



Prevalence of Incidental Radiopacities in Panoramic Radiographs

Hashmath Ara ^a, Chandrasekaran Krithika ^{b*≡} and Chitathoor Sridhar ^{c◊}

^a Private Practitioner, Chennai, India.

^b Meenakshi Academy of Higher Education and Research, West K.K Nagar, Chennai, India.

^c Stanley Medical College, George Town, Chennai, India.

Authors' contributions

This work was carried out in collaboration among all authors. All authors read and approved the final manuscript.

Article Information

DOI: 10.9734/JPRI/2021/v33i58A34135

Open Peer Review History:

This journal follows the Advanced Open Peer Review policy. Identity of the Reviewers, Editor(s) and additional Reviewers, peer review comments, different versions of the manuscript, comments of the editors, etc are available here: <https://www.sdiarticle5.com/review-history/79814>

Original Research Article

Received 06 October 2021

Accepted 12 December 2021

Published 15 December 2021

ABSTRACT

Routine panoramic radiographs often reveal hidden lesions other than those related to the patient's chief complaint [1]. The study aims to determine the prevalence of incidental radiopacities in panoramic views. There are several conditions where calcifications can occur in soft tissue, including major and minor salivary glands, lymph nodes, and blood vessels, such as sialolith, phlebolith, exostosis, dystrophic calcifications, etc. [2]. Interpretation of panoramic radiograph should consider the possibilities of soft tissue calcification super-imposed in bone. Three hundred and sixty (360) panoramic radiographs are included in the study. The prevalence and distribution of radiopacities were documented along with the probable diagnosis. In addition, statistical analysis was done by SPSS software to evaluate the age and gender-related distribution of radiopacities in panoramic radiographs.

Keywords: *Condensing osteitis; enostosis; impacted supernumerary; odontome; periapical cemento-osseous dysplasia (PCOD).*

1. INTRODUCTION

Panoramic radiography is the preferred imaging modality by dental practitioners due to ease of

generation and reduced cost. Although computed tomography is the gold standard, it is complex to operate and expensive [3]. Panoramic images provide view of teeth, jaw, and surrounding

[≡]Registrar;

[◊]Professor & Head;

*Corresponding author: E-mail: drckrithika@gmail.com;

structures free of superimpositions [1]. Panoramic radiography is commonly indicated as a substitute in cases where full mouth intraoral periapical radiographs are needed to be taken, for orthodontic treatment planning, in the detection of fractures, in the evaluation of trauma, or any pathological lesion, and in assessment for surgical procedures [2]. The procedure is undertaken with an x-ray machine that is configured to move round the head [4]. In this study, we had evaluated the various radiopacities found incidentally in panoramic radiographs and their prevalence. The prevalence of each radiopacity found gives an idea of which radiopacity is frequently seen in panoramic radiographs.

1.1 Aim

The study aims to determine the prevalence of incidental radiopacities in panoramic radiographs and to evaluate the age and gender-related distribution of the radiopacities found

2. MATERIALS AND METHODS

A retrospective cross-sectional study was conducted from the source of samples collected from a Dental college and hospital in Chennai. Clearance was obtained from the institutional ethical committee. Panoramic radiographs were selected from patients of age between 13-75 years who had visited the dental department for routine dental check up and various dental complaints. Prevalence and distribution of radiopacities were documented as incidental findings from these radiographs. (1). Radiographs included were those without significant artefacts or distortion while those excluded were panoramic radiographs generated for orthodontic treatment and evaluation of fracture.

In addition, statistical analysis was done by SPSS software to evaluate the age and gender-related distribution of radiopacities in panoramic radiographs and statistical significance will be set at $p \leq 0.05$

3. RESULTS

The study sample comprised of 360 panoramic radiographs with equal numbers for both genders. Further, they were divided into three groups based on age-wise distribution. Group A includes 13 to 25 years of age, Group B- 26 to 50 years, and Group C -51 to 75 years.

In the 360 panoramic radiographs, 29 incidental findings of radiopacities were found. Out of the 29 radiopacities, 13 were found in males and 16 in females (Chart 1). The Maxilla showed 11 while mandible showed 18 radiopacities (Chart 2). Furthermore, group A had 6, group B had 8, and group C had 15 radiopacities out of the 29 findings (Chart 3). Specific pathologies were condensing osteitis (2.5%, $n = 9$), enostosis (2.2%, $n = 8$), impacted supernumerary (1.9%, $n = 7$), Odontome (1.1%, $n = 4$) and PCOD (give full meaning of PCOD Periapical Cemento-Osseous Dysplasia (PCOD)) (3.5%, $n = 1$) (Chart 4).

4. DISCUSSION

Panoramic radiography is a useful tool in the evaluation of teeth and jaw. However, during the procedure, there may be incidental radiopacities that may be artefactual and lead to misdiagnosis [5]. This study aimed at reviewing some panoramic radiographs for evidence of such incidental findings. In this study, out of 29 positive findings from 360 panoramic radiographs, the male had 13 positive results & the female had 16 positive findings. Maxilla showed 11 positive findings & the mandible showed 18 positive results suggesting that the prevalence of radiopacities is more in mandible. Among the three age groups, group A had 6 positive findings, group B had 8, and group C had 15 suggesting that incidence of radiopacity increases with age, and most positive results occur in the age group above 51 years.

Condensing osteitis is a reaction to infection. It is different from other periapical inflammatory diseases as bone production leads to a radiopaque lesion rather than bone destruction [6]. This sclerotic reaction is brought about by good patient resistance combined with a low degree of virulence of bacteria. In this study, the prevalence of condensing osteitis was 9 (2.5%) out of 29 cases with positive findings, commonly occurring in males, mandibular region and most prevalent in older adults of age group 51 to 75 years. A similar result was derived in a study in the Turkish population with a prevalence of 2.7% [7]. A study conducted in Iranian population reported 32 (7.8%) cases of condensing osteitis [8].

Enostosis is a localized, well-defined, radiopaque mass in the jaw with round, elliptical or irregular shapes, and variable sizes [9]. Most of these lesions are asymptomatic and are seen as

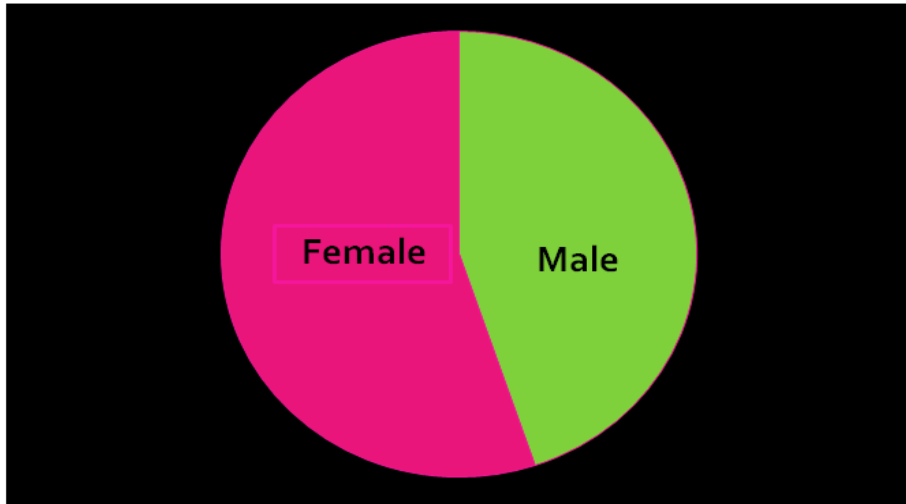


Chart 1. Male and female ratio

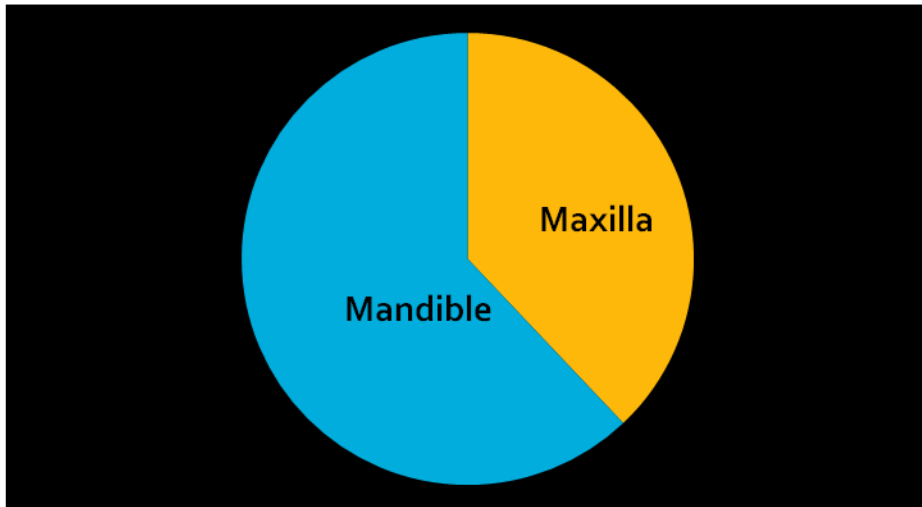


Chart 2. Ratio of maxilla and mandible

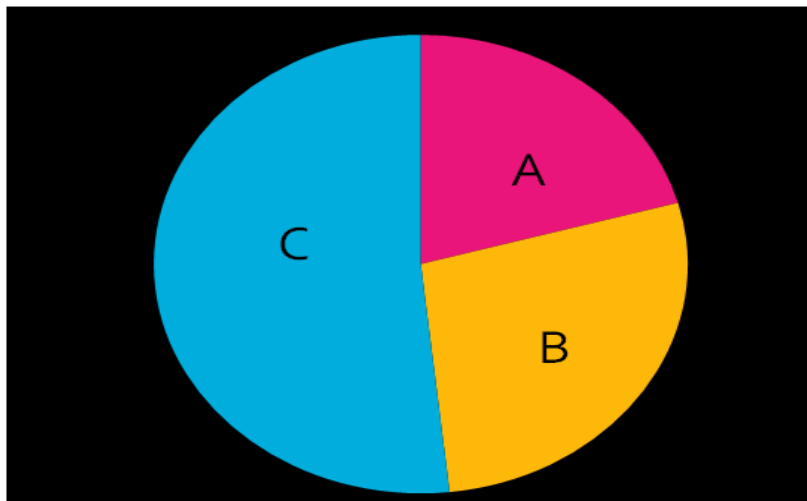


Chart 3. Radiopacities

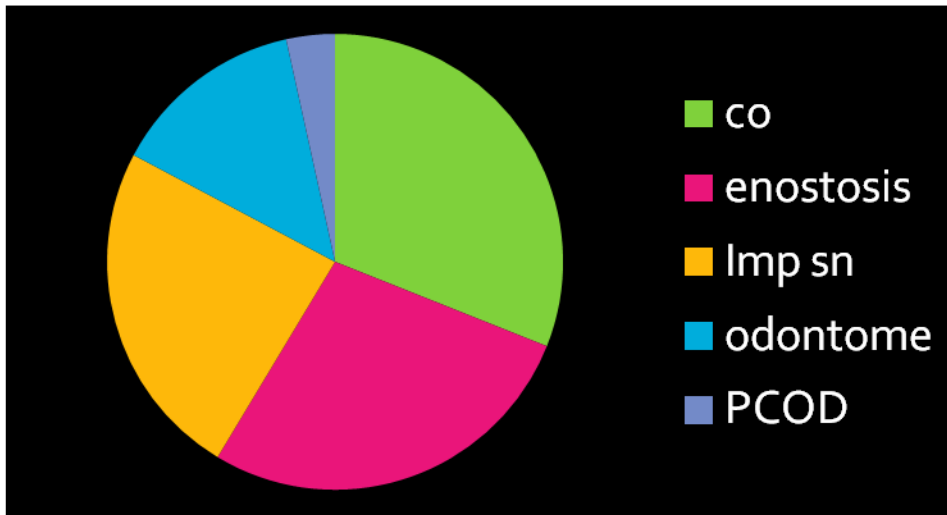


Chart 4. PCOD ratio

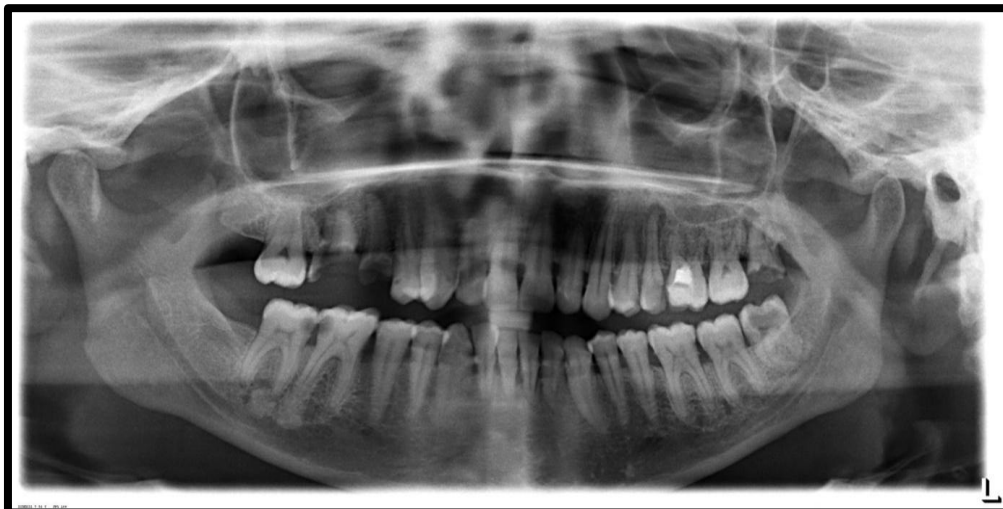

Fig. 1. Condensing osteitis

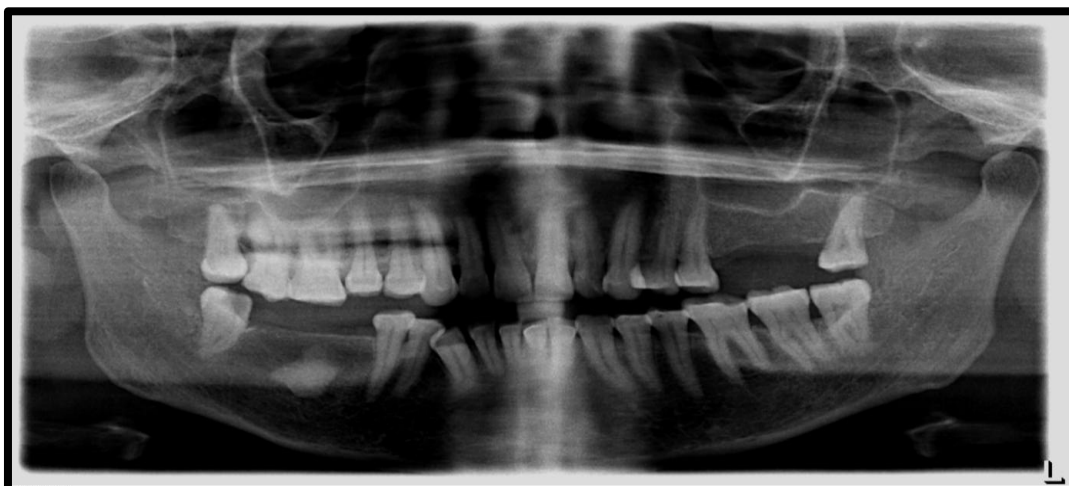

Fig. 2. Enostosis

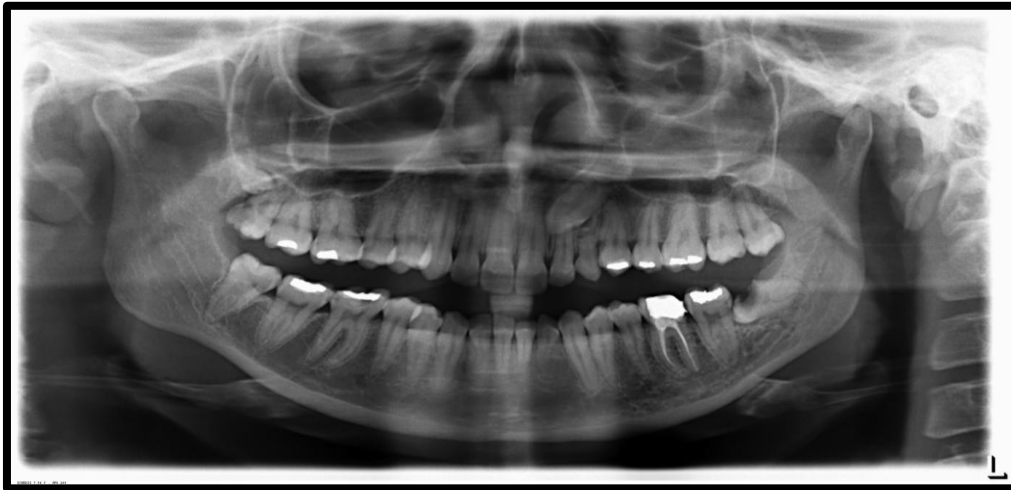

Fig. 3. Impacted supernumerary

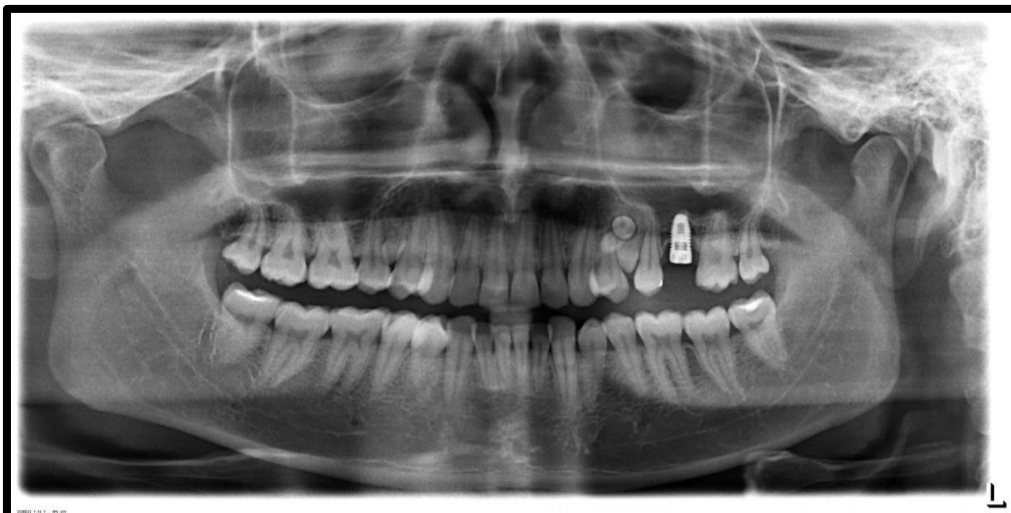


Fig. 4. Odontome

incidental findings in routine radiographs [10]. In this study, prevalence of enostosis was 8 (2.2%) out of 29 cases with positive results, more common in females, mandibular region and mostly found in older age groups of 51 to 75 years. The results of our study were found to be similar to a study reported in the Chilean population with 29 (2.82%) cases reported with idiopathic osteosclerosis with mean age being 30.9 years with higher female predilection [11]. But compared with other studies which reported around 32 (7.5%) cases with mean age being 33.8 ± 13.66 and higher female predilection [8].

Supernumerary teeth are a significant dental anomaly mainly affecting the primary and early mixed dentition, and it may cause many pathological disturbances to the developing

permanent dentition. Therefore, early diagnosis and immediate treatment are necessary for the prevention of deleterious effects [12]. In this study prevalence of impacted supernumerary was 7 (1.9%) out of 29 cases with positive findings. They were commonly seen in females, the maxillary region, and in the age group 13 to 25 years as well as 51 to 75 years. A study conducted in CBCT to investigate impacted supernumerary teeth depicted most location being maxillary anterior region [13]. A retrospective study conducted in North Indian population depicted a prevalence rate of 2.6% of supernumerary teeth with most frequent location being anterior maxilla [14].

Odontomes are the most common type of odontogenic tumors. They come under benign

calcified odontogenic tumors. Odontomes are classified into three types, complex, compound, and composite odontomes. Various theories or etiological factors have been quoted for the formation of odontomes. Mostly they are asymptomatic; rarely, signs and symptoms may occur. Therefore, the management depends upon early diagnosis, histopathological examination, and excision of the tissues [15]. In this study, the prevalence of Odontome was 4 (1.1%) out of 29 cases with positive findings, commonly occurring in males, maxillary region and most common in the younger age group of 13 to 25 years. A Turkish study reported a prevalence of 0.14% of odontomes with more common location being anterior mandible [16]. This lower prevalence rate in their study could be due to more number of panoramic radiographs were examined to identify odontomes.

PCOD is a rare asymptomatic benign lesion, with the replacement of fibrous tissue with the normal bone tissue with metaplastic bone and new-formed cement [17]. In this study prevalence of PCOD is only 1 out of 29 cases with positive findings, as it is rare in occurrence compared to the other four radiopacities. Incidence of PCOD in general population found to be 2-3/1000 [18]. This can also be due to misdiagnosis or misperception with some other radiographic pathology [19].

5. CONCLUSION

Radiopacities in panoramic radiographs had a prevalence of 8.01% (29/360). Specific radiopacities found in this study in decreasing order of prevalence are condensing osteitis, enostosis, impacted supernumerary teeth, odontome, and PCOD. In addition, female predilection and site predilection for mandible was a feature of radiopacities in this study. They were also more common in elderly individuals, over 51 years of age.

CONSENT

As per international standard or university standard, patient's consent has been collected and preserved by the authors.

ETHICAL APPROVAL

As per international standard or university standard written ethical approval has been collected and preserved by the author(s).

COMPETING INTERESTS

Authors have declared that no competing interests exist.

REFERENCES

1. Bondemark L, Jeppsson M, Lindh-Ingildsen L, Rangne K. Incidental findings of pathology and abnormality in pretreatment orthodontic panoramic radiographs. *Angle Orthodontist*. 2006; 76(1):98-102.
2. Ramesh A. Panoramic Imaging. In (Edited by Mallya SM, Lam EWN) *White and Pharoah's Oral Radiology: Principles and Interpretation: Second South Asia Edition*. Elsevier India. 2019;132-150.
3. Adejoh T, Nzotta CC, Umeh EO, Aronu ME, Dambele MY. Head Computed Tomography Protocol Audit & Correction in Two Tertiary Health Institutions in Anambra State of Nigeria. *West African Journal of Radiology*. 2017;24:157- 161
4. Vengalath J, Puttabuddi JH, Rajkumar B, Shivakumar GC. Prevalence of soft tissue calcifications on digital panoramic radiographs: A retrospective study. *Journal of Indian Academy of Oral Medicine and Radiology*. 2014;26(4):385-89.
5. Adejoh T, Onwuzu SWI, Luntsi G, Nkubli FB, Ikegwonu NC. X-Ray Special Investigations Rebook Analysis (XSIRA). *IOSR Journal of Dental and Medical Sciences*. 2015;14(7):71-75.
6. Holly D, Jurkovic R, Mracna J. Condensing osteitis in oral region. *Bratislavské lekarske listy*. 2009;110(11):713-5.
7. Altun O, Dedeoğlu N, Umar E, Yolcu U, Acar AH. Condensing osteitis lesions in eastern anatolian turkish population. *Oral surgery, oral medicine, oral radiology*. 2014;2(2):17-20.
8. Farhadi F, Ruhani MR, Zarandi A. Frequency and pattern of idiopathic osteosclerosis and condensing osteitis lesions in panoramic radiography of Iranian patients. *Dental Research Journal*. 2016;13(4): 322–326.
9. Mariani GC, Favaretti F, Lamazza L, De Biase A. Dense bone island of the jaw: a case report. *Oral & Implantology*. 2008;1(2):87-90.
10. Chintala L, Bhavya B, Chaitanya YC, Chaitanya PV, Mamatha D, Sathwik G. Dense bony islands of the maxillofacial region: A radiological study. *International*

- Journal of Applied Dental Sciences. 2017;3(4),258-260.
11. Fuentes R, Arias A, Astete N, Farfán C, Garay I, Dias F. Prevalence and morphometric analysis of idiopathic osteosclerosis in a Chilean population. *Folia Morphol.* 2018;77(2):272–278.
 12. Gupta S, Marwah N. Impacted Supernumerary Teeth—Early or Delayed Intervention: Decision Making Dilemma? *International journal of clinical pediatric dentistry.* 2012;5(3):226.
 13. Gurler G, Delilbasi C, Delilbasi E. Investigation of impacted supernumerary teeth: A cone beam computed tomograph (CBCT) study. *Journal of Istanbul University Faculty of Dentistry.* 2017;51(3): 18–24.
 14. Chou ST, Chang HP, Yang YH, Lung CY, Tseng YC, Pan CY, Cheng JH. Characteristics of supernumerary teeth among nonsyndromic dental patients. *Journal of Dental Sciences.* 2015;10: 133-138.
 15. Sutton JB. Odontomes. *International Journal of Clinical Pediatric Dentistry.* 2012;3:226-30.
 16. Avsever H, Kurt H, Suer TB, Ozturk HP, Piskin B. The prevalence, anatomic locations and characteristics of the odontomas using panoramic radiographs. *J Oral Maxillofac Radiol.* 2015;3:49-53
 17. Roghi M, Scapparone C, Crippa R, Silvestrini-Biavati A, Angiero F. Periapical cemento-osseous dysplasia: clinic pathological features. *Anticancer Research.* 2014;34(5): 2533-6.
 18. Zegarelli E, Kutscher A, Napoli N, Iurono F, Hoffman P. The cementoma. A study of 230 patients with 435 cementomas. *Oral Surg Oral Med Oral Pathol.* 1964;17:219–224.
 19. Morikava FS, Onuki LY, Chaiben CL, Tommasi MHM, Vieira I, de Lima AAS. Periapical cemento-osseous dysplasia: case report. *RSBO (Online).* 2012; 9 (1).

© 2021 Ara et al.; This is an Open Access article distributed under the terms of the Creative Commons Attribution License (<http://creativecommons.org/licenses/by/4.0>), which permits unrestricted use, distribution, and reproduction in any medium, provided the original work is properly cited.

Peer-review history:

*The peer review history for this paper can be accessed here:
<https://www.sdiarticle5.com/review-history/79814>*