



# **Linear Psoriasis: A Rare and Often Underdiagnosed form of Psoriasis in Children**

**S. Sektaoui <sup>a\*</sup>, Z. Mehsas <sup>a</sup>, N. Ismaili <sup>a</sup> and K. Senouci <sup>a</sup>**

<sup>a</sup> *Department of Dermatology and Venereology, Faculty of Medicine and Pharmacy of Rabat, Ibn Sina University Hospital, Mohamed V University, Rabat, Morocco.*

## **Authors' contributions**

*This work was carried out in collaboration among all authors. Authors SS and ZM designed the study, performed the statistical analysis, wrote the protocol and wrote the first draft of the manuscript. Authors NI and KS managed the analyses of the study. All authors read and approved the final manuscript.*

## **Article Information**

DOI: 10.9734/AJPR/2023/v11i3219

## **Open Peer Review History:**

This journal follows the Advanced Open Peer Review policy. Identity of the Reviewers, Editor(s) and additional Reviewers, peer review comments, different versions of the manuscript, comments of the editors, etc are available here: <https://www.sdiarticle5.com/review-history/96269>

**Case Report**

**Received: 19/11/2022**

**Accepted: 28/01/2023**

**Published: 15/02/2023**

## **ABSTRACT**

Blaschko-linear psoriasis (PBL) is a rare form of psoriasis that presents as longitudinal lines on the skin, along Blaschko lines. This form of psoriasis is often observed in children and can be difficult to distinguish from other acquired Blaschko linear dermatoses such as inflammatory linear verrucous epidermal nevus (ILVEN) and lichen striatus. The prevalence of PBL is unknown, but it is generally observed in children and is more common in boys than in girls. The clinical and histological similarity of PBL to ILVEN presents a diagnostic challenge. In this case report, we present the case of a 7-year-old child with PBL and discuss the diagnostic and therapeutic aspects of this rare form of psoriasis. We were able to confirm the diagnosis of PBL after treatment with white petroleum jelly and salicylic acid petroleum jelly 5% resulted in a significant improvement of the lesions. Topical treatments, phototherapy, and systemic medications can be used in the case of PBL. It is important to select the most appropriate treatment based on the severity of the lesions, the location, and the patient's tolerance, and to keep in mind that PBL can have long-term effects on the quality of life of patients and their families.

\*Corresponding author: Email: [soukaina.sektaoui@gmail.com](mailto:soukaina.sektaoui@gmail.com);

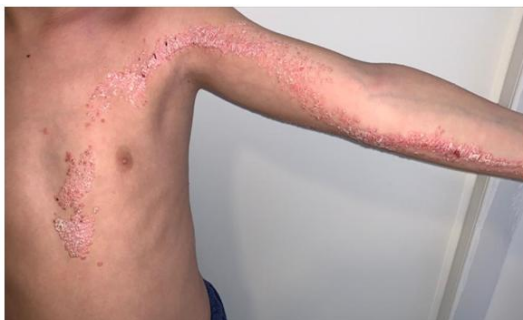**Keywords:** Blaschko-linear psoriasis; inflammatory linear verrucous epidermal nevus; children; diagnosis; treatment.

## 1. INTRODUCTION

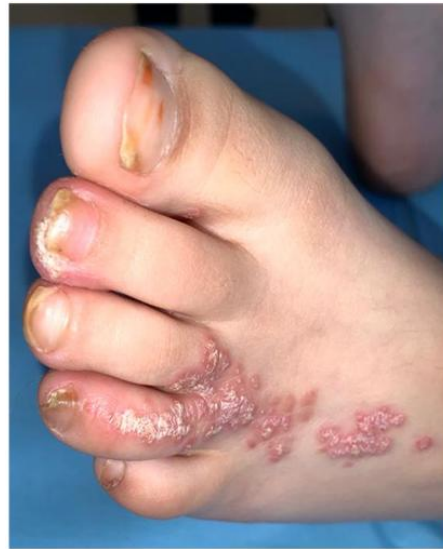Psoriasis is a chronic skin disease characterized by red, scaly patches. While psoriasis is relatively common, some rare forms of the disease can be difficult to diagnose and treat [1]. Blaschko-linear psoriasis (PBL) is a rare form of psoriasis that can be difficult to diagnose due to its similarity to other acquired Blaschko-linear dermatoses such as inflammatory verrucous epidermal nevus and lichen striatus in children [1,2]. PBL presents as longitudinal lines on the skin, along Blaschko lines. In this article, we present the case of a 7-year-old child with blaschko-linear psoriasis and discuss the diagnostic and therapeutic aspects of this rare form of psoriasis.

## 2. PRESENTATION OF THE CASE

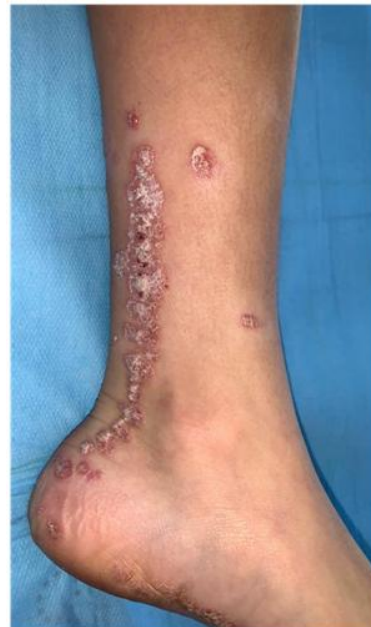The patient was a 7-year-old child with no significant medical history who had been experiencing erythematous and scaly lesions on the left hemi body for 3 years. The lesions were slightly pruritic and presented as small, linear patches. They affected the trunk, shoulder, arms, forearms, leg, third and fourth toes, and the sole of the left foot. Clinical examination revealed the presence of characteristic signs of psoriasis, such as the candle sign and bloody dew, as well as onycholysis and a saw-toothed appearance of the nails (Fig. 1). A skin biopsy was performed and showed parakeratosis, Munro micro abscesses, hypogranulosis, and papillomatosis (Fig. 2). Based on the clinical and histological findings, two diagnoses were considered: PBL and ILVEN. To determine the correct diagnosis, the patient was treated with white petroleum jelly and salicylic acid petroleum jelly 5%, which resulted in a significant improvement of the lesions and confirmed the diagnosis of PBL.



**Fig. 1a. Linear psoriasis is seen on the trunk, shoulders, arms, and forearms**



**Fig. 1b. Linear psoriasis is present on the third and fourth toes, as well as the sole of the left foot**



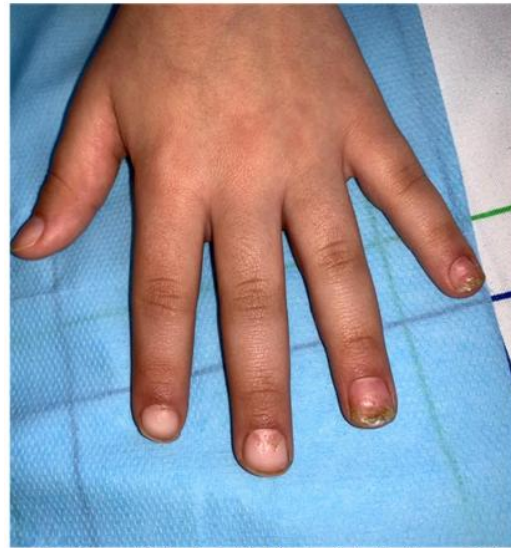**Fig. 1c. The leg displays linear psoriasis**

## 3. DISCUSSION

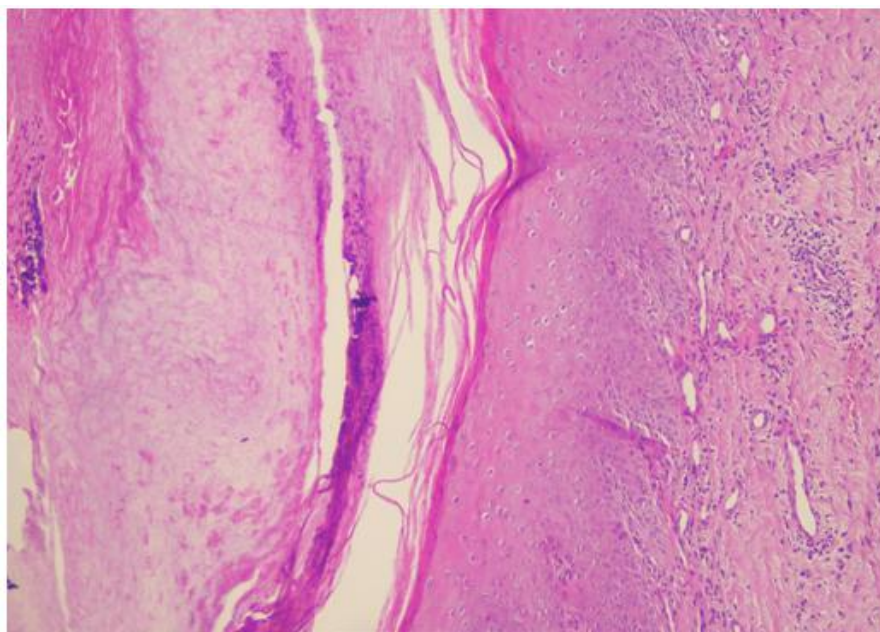
Linear psoriasis (PBL) is a rare form of psoriasis, which is considered uncommon and was first documented in 1951. To date, there have been limited reported cases of this type of psoriasis in medical literature [1]. PBL is characterized by longitudinal lines on the skin along Blaschko

lines. This form of psoriasis is often observed in children and can be difficult to distinguish from other acquired Blaschko linear dermatoses such as inflammatory linear verrucous epidermal nevus (ILVEN) and lichen striatus [2,3]. The exact prevalence of PBL is unknown due to the few cases described in the literature, but it is generally observed in children and is more common in boys than in girls [4]. The clinical and histological similarity of PBL to ILVEN presents a diagnostic challenge, and the distinction between these two diagnoses has been discussed in the literature [4]. Histologically, PBL is difficult to distinguish from ILVEN [5]. However, Saraswat et al. [6] described differences in clinical characteristics between the two entities. Late onset of asymptomatic or slightly pruritic lesions, rapid progression, possible involvement of nails and/or scalp, and a favorable response to anti-psoriasis treatment are in favor of PBL. In contrast, ILVEN lesions typically appear in the first few months of life, are slowly progressive, very pruritic, and very resistant to anti-psoriasis treatment [5]. In our case, after clinical examination and biopsy, we were unable to distinguish between PBL and ILVEN. It was only after treatment with white petroleum jelly and salicylic acid petroleum jelly 5%, which resulted in a significant improvement of the lesions, as has been observed in other cases of PBL [7,8], that we were able to confirm the diagnosis of PBL. Topical treatments, phototherapy, and

systemic medications can be used in the case of PBL. It is important to select the most appropriate treatment based on the severity of the lesions, the location, and the patient's tolerance, and to keep in mind that PBL can have long-term effects on the quality of life of patients and their families [4].



**Fig. 1d. Characteristic signs of psoriasis, including the candle sign, bloody dew, onycholysis, and a saw-toothed nail appearance, are also visible**



**Fig. 2. This image shows the results of the skin biopsy and revealed parakeratosis, Munro micro abscesses, hypogranulosis, and papillomatosis, confirming the diagnosis of linear psoriasis**



#### 4. CONCLUSION

Linear Blaschko psoriasis (PBL) is a rare form of psoriasis that presents as longitudinal lines on the skin along the Blaschko lines. Although similar clinically and histologically to inflammatory verrucous epidermal nevus (ILVEN), there are differences in the clinical characteristics between the two entities. The exact prevalence of PBL is not known, but it is generally seen in children and is more common in boys than in girls. PBL can be difficult to diagnose and treat, but it is important to select the most appropriate treatment based on the severity of the lesions, their location, and the patient's tolerance. In our case, treatment with white petroleum jelly and 5% salicylic acid petroleum jelly resulted in a significant improvement of the lesions, confirming the diagnosis of PBL. It is important to consider the long-term effects of PBL on the quality of life of patients and their families.

#### CONSENT

All authors declare that 'written informed consent was obtained from the parents of the patient (for publication of this case report and accompanying images).

#### ETHICAL APPROVAL

All authors hereby declare that all experiments have been examined and approved by the appropriate ethics committee and have therefore been performed in accordance with the ethical standards laid down in the 1964 Declaration of Helsinki

#### COMPETING INTERESTS

Authors have declared that no competing interests exist.

#### REFERENCES

1. Nasimi M, Abedini R, Azizpour A, Nikoo A. Isolated linear blaschkoid psoriasis. Clin Exp Dermatol. 2016;41(7):775-778.
2. Grosshans EM. Acquired blaschkolinear dermatoses. Am J Med Genet. 1999;85:334-7.
3. Lee HJ, Kang WH, Hann SK. Acquired blaschko dermatitis: Acquired relapsing self-healing blaschko dermatitis. J Dermatol. 1996;23:639-42.
4. De Jong E, Rulo HF, van de Kerkhof PC. Inflammatory linear verrucous epidermal nevus versus linear psoriasis. A clinical, histological and immunohistochemical study. Acta Derm Venereol. 1991;71:343-346.
5. Figueiras Dde A, Cauas RC, Takano DM, Ramos TB, Marinho AK, Bezerra MS. Linear psoriasis: A case report on three-year-old child. An Bras Dermatol. 2015;90(3 Suppl 1):194-6.
6. Saraswat A, et al. Unilateral linear psoriasis with palmoplantar, nail, and scalp involvement. Pediatr Dermatol. 2004;21:70
7. Chien P Jr, Rosenman K, Cheung W, Wang N, Sanchez M. Linear psoriasis. Dermatol Online J. 2009;15(8):4.
8. Sfia M, Roth-Mall B, Tortel MC, Guillaume JC, Cribier B. Psoriasis blaschko-linéaire révélé par un traitement par infliximab (Remicade) [Blasch-kolinear psoriasis revealed by infliximab therapy]. Ann Dermatol Venereol. 2009;136(12):898-903.

Peer-review history:

The peer review history for this paper can be accessed here:  
<https://www.sdiarticle5.com/review-history/96269>