



A Pheochromocytoma with Liver Metastasis: What about Curative Surgery?

Choukri Elm'hadi ^{a,b,++*}, Meryem Zerrik ^c, Yassir Benameur ^d,
Imad Taleb ^a and Rachid Tanz ^a

^a Department of Medical Oncology, Mohammed V Military Teaching Hospital of Rabat, Morocco.

^b School of Medicine and Pharmacy, University Hassan II, Casablanca, Morocco.

^c Department of Internal Medicine, Mohammed V Military Teaching Hospital of Rabat, Morocco.

^d Department of Nuclear medicine, Mohammed V Military Teaching Hospital of Rabat, Morocco.

Authors' contributions

This work was carried out in collaboration among all authors. All authors read and approved the final manuscript.

Article Information

DOI: 10.9734/JAMMR/2023/v35i74985

Open Peer Review History:

This journal follows the Advanced Open Peer Review policy. Identity of the Reviewers, Editor(s) and additional Reviewers, peer review comments, different versions of the manuscript, comments of the editors, etc are available here: <https://www.sdiarticle5.com/review-history/97039>

Case Study

Received: 20/12/2022

Accepted: 27/02/2023

Published: 08/03/2023

ABSTRACT

Introduction: 35% of pheochromocytomas are malignant and generally have a poor prognosis. Visceral metastases are associated with shorter survival. Treatments for advanced pheochromocytomas are essentially palliative. Surgery is potentially curative; however, tumor extension limits the chance for a curative resection.

Case Presentation: A 21-year-old woman presented to our hospital with severe hypertension associated with Ménard's triad and heaviness of the left flank. The abdominal CT scan discovered a left adrenal mass with liver metastases. The diagnosis of pheochromocytoma was confirmed biochemically by the elevated catecholamine and metanephrine levels in the blood and urine. After preparation by the alpha-adrenergic blockade, she underwent left adrenalectomy and resection of

⁺⁺ Medical Oncologist;

*Corresponding author: E-mail: dr.choukrielmhadi@gmail.com;

left liver metastases followed by right hepatectomy. A pathology examination was performed and the final report was a metastatic pheochromocytoma with negative margins. She was discharged on postoperative without complications, and no evidence of recurrence occurred 48 months postoperatively.

Conclusion: complete resection of liver metastases from metastatic pheochromocytoma can improve survival and should also be considered in the event of predominant secreting symptoms.

Keywords: Pheochromocytoma; liver metastases; complete resection.

1. INTRODUCTION

"Pheochromocytomas is rare neuroendocrine tumors that arise from the adrenal medulla especially from chromaffin cells" [1]. 35% of pheochromocytomas are malignant and generally have a poor prognosis [2]. "The most common sites of metastasis are the bone, lymph nodes, lungs, and liver. Visceral metastases are associated with shorter survival" [3]. The majority of pheochromocytomas are sporadic tumors [4]. The genetic forms are seen in a third of cases and are often related to a Succinate dehydrogenase mutation [5]. Currently, treatments for advanced pheochromocytomas are essentially palliative. Surgery is potentially curative; however, tumor extension limits the chance of curative resection.

We report the case of a young woman with a metastatic pheochromocytoma to the liver with prolonged disease control through surgery of the primary tumor and metastasis.

2. CASE PRESENTATION

A 21-year-old woman presented to our hospital with severe hypertension with peaks paroxysmal at 260/140 mmHg associated with Ménard's triad (headaches, palpitations, sweating attacks) and heaviness of the left flank.

A chest/abdomen CT discovered an irregular left hypodense adrenal mass enhanced with contrast (98 * 58 * 45 mm). This mass compressing the left kidney was in contact with the left renal artery and vein, the splenic vein, and the spleen without signs of an invasion. Also, the scanner revealed hypodense nodules in the liver suggestive of malignancy in segments II, V, VI, VII, VIII, and I.

The diagnosis of pheochromocytoma was confirmed biochemically by the elevated catecholamine and metanephrine levels in the blood [metanephrine 1.41 nmol/l (nl < 0.36), normetanephrine > 32 nmol/l (nl < 0.71) and urine

24 hours Metanephrines 357 nmol/24h (nl < 159)) Normetanephrines > 4500 nmol/24h (nl < 281).

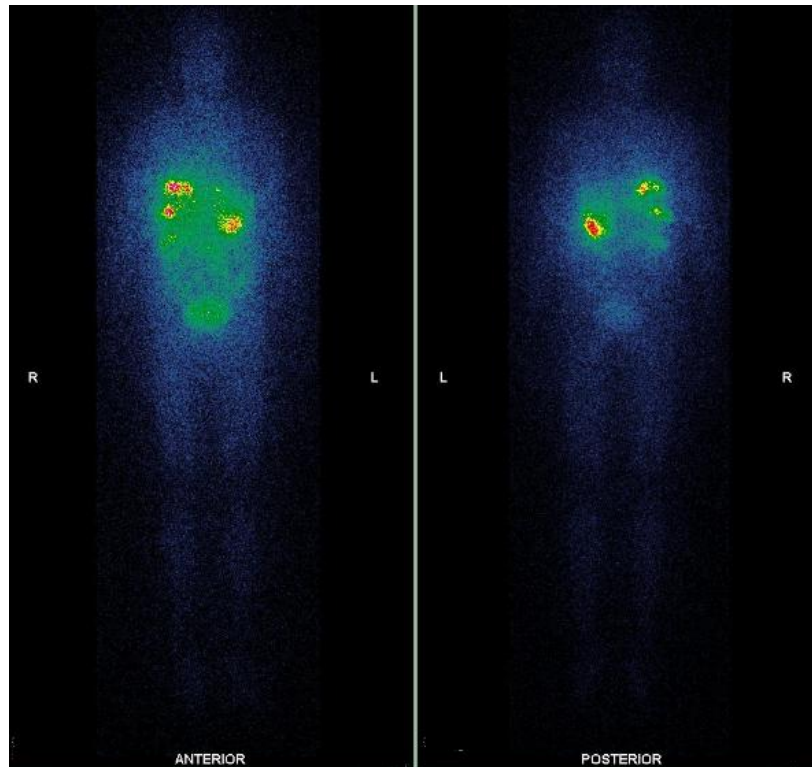
Metaiodobenzylguanidine Scintigraphy and 18F-fluoro-2-deoxyglucose positron emission tomography/CT scan showed abnormal uptake in adrenal left tumor, segments IV, VI and VII of the liver, and in the hepatic dome (Fig. 1 A and B).

After evaluation by a multidisciplinary board, surgical treatment was indicated. Prior to surgery, administering of an alpha-blocker, β blockers and calcium channel blockers was initiated for blood pressure control and increasing of circulating blood volumes. The left adrenalectomy with left liver metastasectomy were performed first. The right portal vein was ligated of increasing the future liver remnant volume as preparation for the planned right hepatectomy.

Pathology examination revealed pheochromocytoma with malignant potential classified according to the pheochromocytoma of the adrenal gland scaled score (PASS) as 4, confirmed by immunohistochemistry (positive in chromogranin A, S100 protein, Synaptophysin, mitotic index (2/20)). Liver metastases were also pathologically diagnosed as pheochromocytoma. Surgical margins were negative. She underwent a right hepatectomy at 4 months after her initial surgery. Again, histopathological examination of the surgical specimens was consistent with pheochromocytoma.

She was discharged 30 days postoperatively without complications; there is no evidence of recurrence after 4 years of surveillance after the last surgery. At the time, the patient is completely asymptomatic, with negative CT scans and normal measurements of urinary and plasma fractionated metanephrines and catecholamines during follow-up.

A-Whole body MIBG scintigraphy



B-Abdomen MIBG scintigraphy

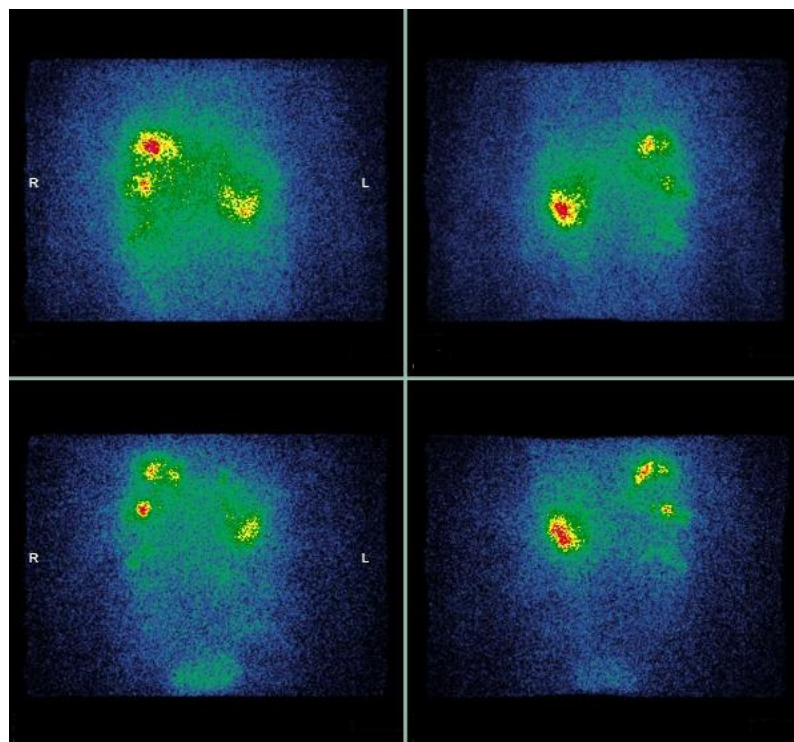


Fig. 1. Iodine-123 MIBG scintigraphy findings showing abnormal uptake in left adrenal tumor and liver metastases

3. DISCUSSION

"Pheochromocytomas are neoplasms of the chromaffin cells of the adrenal medulla in 80% to 90% of cases. Ectopic /Extra-adrenal pheochromocytomas that derived from sympathetic and par-aortic sympathetic ganglia are called paragangliomas" [6]. Pheochromocytomas arise 0.1% hypertensive patients. The annual incidence is estimated to be between 500 and 1600 in the United States [7]. The peak incidence of occurrence is between the third and fifth decades of life, but the mostly occur at a younger age and are more likely to be bilateral in family forms.

The clinical presentation is variable and can be confused with other conditions having similar symptoms. Most of the symptoms are an effect of the overproduction of catecholamine. These include the classic triad of headaches, palpitations, and profuse sweating; associated with hypertension and occasionally severe acute cardiovascular complications. The diagnosis is based on plasma or urines metanephrines measurements. Concomitant drugs should be reviewed before testing for those that interfere with plasma or blood catecholamines evaluation. Conventional and nuclear medicine imaging confirms the diagnosis. Computed Tomography (CT) scans (abdomen/pelvis) are recommended and most helpful for adrenal masses and paragangliomas. If metastatic or multifocal disease is suspected, other imaging procedures should be considered like abdominal/pelvic multiphasic CT or MRI scans, Somatostatin receptor based imaging (SSR), FDG-PET/CT scans, chest CT and metaiodobenzylguanidine (MIBG) scans. Ga-68 DOTATATE and other diverse radionuclide imaging techniques are available for the diagnosis, staging, and follow-up of pheochromocytoma.

"There are no curative treatments for metastatic pheochromocytoma. In patients with metastatic disease with slow/moderate disease progression and asymptomatic, watchful waiting is recommended. Radiotherapy is recommended with cytoreductive resection when possible. Alternatively, radionuclide therapy is recommended if tumors are positive on MIBG scan, or on SSR-based imaging. High-specific-activity iobenguane I-131 or other Iodine-131-MIBG offers multiple benefits, including reduction in antihypertension medication, clinical benefit and biochemical tumor marker responses with an acceptable safety profile" [8]. "It's the only FDA

approved therapy to treat patients with inoperable locally advanced, or metastatic pheochromocytoma MIBG avid. Peptide receptor radionuclide therapy (PRRT) with 177 Lu-dotatate should be considered in patients with high SSR expressing pheochromocytoma given the benefit shown in terms of objective response rate and disease control rate" [9,10].

"Chemotherapy with cyclophosphamide, vincristine, and dacarbazine (CVD) appears to be effective for symptomatic or rapidly progressive malignant pheochromocytoma. This regimen led to an overall response of approximately 50%, including reduction in symptoms, antihypertensive medications, or tumor size" [11]. "Overall survival data are heterogeneous. The overall median survival varies from 3.7 to 6.4 years depending on tumor response" [12]. The major toxicities encountered were moderate reversible granulocytopenia, neurotoxicity. If there is a partial response or disease stabilization, maintenance chemotherapy by dacarbazine or temozolomide may be considered. "All patients develop progressive and ultimately fatal disease" [11].

"Pheochromocytomas are highly vascularized tumors. Vascular endothelial growth factor (VEGF), a main angiogenic factor, has been shown to be upregulated in these tumors, which suggests that it could be a potential therapeutic target" [13]. Tyrosine kinase inhibitors such as sunitinib and cabozantinib seem to show potential activity in metastatic SDH or VHL mutated. Other molecular targeting therapies are under study. "Future Strategies are based on HIF2- α inhibitors, PARP inhibitors, SSTR2 analogues, combination therapies with mTORC1 inhibitors; immunotherapy, combination of radionuclide therapy, and radiosensitizers" [3].

Surgery is the only potentially curative treatment; however, tumor dissemination limits the chance for curative resection. Like colorectal liver metastases, surgical resection might be discussed for patients with resectable metastasis. Liver metastases have increasingly been operated on due to advances in imaging, surgical techniques, anaesthesia management, improved systemic therapy allowing better control of metastatic disease and fewer liver metastases thus enabling curative liver resections. In patients with liver metastases from non-colorectal non-endocrine carcinoma there is no consensus about optimal management and practices remain heterogeneous. Surgery may

be considered in patients with complete resection of metastasis and primary tumors are possible. A primary optimal evaluation by a multidisciplinary board including hepatic surgeons is required.

“Surgical management of metastatic pheochromocytomas is currently controversial given their rarity. Considerable surgical difficulties may be encountered as a result of hypervascularity, adhesion to adjacent organs, and serious adrenergic events” [14]. In the literature, many cases of liver resection of metastases have been reported, but, usually, cases only included metastatic relapses or multi-metastatic tumors having benefited cytoreductive surgery [15-18]. Our patient is remarkable in that she has undergone successful resection of primary tumor and metastases involving liver, without having to resort to specific medical treatment for pheochromocytoma. To our knowledge, this is the first case of a metastatic pheochromocytoma with complete resection of all the affected tissues without adjuvant or preoperative therapy.

4. CONCLUSION

Complete resection of liver metastases from metastatic pheochromocytoma, can improve survival and should also be considered in the event of predominant secreting symptoms. Our experience thus suggests a potential role for surgery as more than merely a palliative treatment for carefully selected patients with resectable metastases. Much caution must however be exercised before extrapolating from experience with a single patient.

CONSENT

As per international standard or university standard, patient(s) written consent has been collected and preserved by the author(s).

ETHICAL APPROVAL

As per international standard or university standard written ethical approval has been collected and preserved by the author(s).

COMPETING INTERESTS

Authors have declared that no competing interests exist.

REFERENCES

1. Lenders JW, Eisenhofer G, Mannelli M, Pacak K. Pheochromocytoma. *Lancet*

- (London, England). 2005;366(9486):665–75.
2. Eisenhofer G, Bornstein SR, Brouwers FM, Cheung NK, Dahia PL, de Krijger RR, et al. Malignant pheochromocytoma: current status and initiatives for future progress. *EndocrRelat Cancer*. 2004;11:423–36.
3. Ilanchezhian M, Jha A, Pacak K, Del Rivero J. Emerging Treatments for Advanced/Metastatic Pheochromocytoma and Paraganglioma. *Curr Treat Options Oncol*. 2020;21(11) :1-18
4. Luchetti A, Walsh D, Rodger F, Clark G, Martin T, Irving R, et al. Profiling of somatic mutations in pheochromocytoma and paraganglioma by targeted next generation sequencing analysis. *Int J Endocrinol*. 2015;2015:138573.
5. Astuti D, Latif F, Dallol A, Dahia PL, Douglas F, George E, et al. Gene mutations in the succinate dehydrogenase subunit SDHB cause susceptibility to familial pheochromocytoma and to familial paraganglioma. *Am J Hum Genet*. 2001; 69(1):49–54.
6. Lenders JW, Duh QY, Eisenhofer G, Gimenez-Roqueplo AP, Grebe SK, Murad MH, et al. Pheochromocytoma and paraganglioma: an endocrine society clinical practice guideline. *J Clin Endocrinol Metab*. 2014;99:1915-1942.
7. Wang W, Li P, Wang Y, Wang Y, Ma Z, Wang G, et al. Effectiveness and safety of laparoscopic adrenalectomy of large pheochromocytoma: A prospective, nonrandomized, controlled study. *Am J Surg*. 2015; 210:230-235.
8. Pryma DA, Chin BB, Noto RB, Dillon JS, Perkins S, Solnes L, et al. Efficacy and safety of high-specific-activity (131) I-MIBG therapy in patients with advanced pheochromocytoma or paraganglioma. *J Nucl Med*. 2019;60:623-630.
9. Satapathy S, Mittal BR, Bhansali A. 'Peptide receptor radionuclide therapy in the management of advanced pheochromocytoma and paraganglioma: A systematic review and meta-analysis'. *ClinEndocrinol (Oxf)*. 2019; 91:718-727
10. Nastos K, Cheung VTF, Toumpanakis C, Navalkisoor S, Quigley AM, Caplin M., et al. Peptide receptor radionuclide treatment and (131)I-MIBG in the management of patients with metastatic/progressive pheochromocytomas and paragangliomas. *J SurgOncol* 2017;115: 425-434.

11. Huang H, Abraham J, Hung E, Averbuch S, Merino M, Steinberg SM, et al. Treatment of malignant pheochromocytoma/paraganglioma with cyclophosphamide, vincristine, and dacarbazine: Recommendation from a 22-year follow-up of 18 patients. *Cancer*. 2008;113(8):2020–8.
12. Ayala-Ramirez M, Feng L, Habra MA, et al. Clinical benefits of systemic chemotherapy for patients with metastatic pheochromocytomas or sympathetic extra-adrenal paragangliomas: Insights from the largest single-institutional experience. *Cancer*. 2012;118:2804-2812.
13. Ferreira CV, Siqueira DR, Romitti M, Ceolin L, Brasil BA, Meurer L, et al. Role of VEGF-A and its receptors in sporadic and MEN2-associated pheochromocytoma. *Int J Mol Sci*. 2014; 15(4):5323–36
14. J. Naranjo, Dodd Sarah, Y.N. Martin, Perioperative management of pheochromocytoma, *J. Cardiothorac. Vasc. Anesth*. 2017;31:1427–1439.
15. López-Gómez J, Salazar-Álvarez MA, Adame RY, Alfaro-Goldaracena A, Flores-Vazquez ER, Gonzalez-Infante SH, et al. Metastatic pheochromocytoma to liver without elevation of metanephrines and catecholamines. *Int J Surg Case Rep*. 2016;29:71-75.
16. Wei S, Wu D, Yue J. Surgical resection of multiple liver metastasis of functional malignant pheochromocytoma: a case report and literature review. *J Cancer Res Ther* Wei S, Wu D, Yue J. Surgical resection of multiple liver metastasis of functional malignant pheochromocytoma: a case report and literature review. *J Cancer Res Ther*. 2013;9 Suppl: S183-5.
17. Kaneto H, Kamei S, Tatsumi F, Shimoda M, Kimura T, Nakanishi S, et al . Case Report: Malignant Pheochromocytoma Without Hypertension Accompanied by Increment of Serum VEGF Level and Catecholamine Cardiomyopathy. *Front Endocrinol (Lausanne)*. 2021;12:688536.
18. Arnas-Leon C, Sánchez V, Santana Suárez AD, Quintana Arroyo S, Acosta C, Martínez Martín FJ. Complete Remission in Metastatic Pheochromocytoma Treated with Extensive Surgery. *Cureus*. 2016;8 (1):e447.

© 2023 Elm'hadi et al.; This is an Open Access article distributed under the terms of the Creative Commons Attribution License (<http://creativecommons.org/licenses/by/4.0>), which permits unrestricted use, distribution, and reproduction in any medium, provided the original work is properly cited.

Peer-review history:

The peer review history for this paper can be accessed here:

<https://www.sdiarticle5.com/review-history/97039>