



Umbilical Pilonidal Sinus: Case Report of 2 Cases and Review of Literature

Manas Ranjan Panda¹ and Prajesh Bhuta^{1*}

¹Jaslok Hospital, Peddar Road, 15, Deshmukh Marg, Mumbai-400026, India.

Authors' contributions

This work was carried out in collaboration between both authors. Author MRP collected the data, patient information and wrote the first draft of the manuscript. Author PB did the review of literature and references. Both authors read and approved the final manuscript.

Article Information

Editor(s):

(1) Dr. Georgios Tsoulfas, Aristoteleion University of Thessaloniki, Greece.

Reviewers:

(1) Josko Petricevic, University of Mostar, Bosnia and Herzegovina.

(2) Hakan Özdemir, Haydarpasa Numune Training and Research Hospital, Turkey.

(3) Elias Saikaly, Saint George Hospital University Medical Center, University of Balamand, Lebanon.

Complete Peer review History: <http://www.sdiarticle4.com/review-history/58340>

Received 16 April 2020

Accepted 22 June 2020

Published 02 July 2020

Case Study

ABSTRACT

Pilonidal sinus is a chronic and commonly recurrent disorder that is usually seen in the natal cleft in the sacro-coccygeal area although very few cases involving the umbilicus, axilla or interdigital area have also been reported. Although not very rare the cases reported are few and there is no consensus on management. We report 2 cases of umbilical pilonidal sinus in a tertiary care Hospital treated with excision of tract with umbilectomy.

Keywords: Pilonidal sinus; umbilicus; umbilectomy.

1. INTRODUCTION

Pilonidal sinus is a disease which is characterized by a granulomatous reaction to a hair shaft penetrating epidermis from the cutaneous surface [1]. Although commonly seen in sacrococcygeal region it is seen in other

parts of the body as well though it is not very common.

Pilonidal sinus term was first coined by Hodges in 1880. Pilonidal sinus occurs in many parts of the body such as web of fingers penis shaft, sacrococcygeal area and navel. The pilonidal

*Corresponding author: E-mail: colorectalunit@gmail.com;

sinus was originally thought to be of congenital origin but the presence of interdigital pilonidal sinus in barbers suggests that it may be acquired [2].

Sacrococcygeal pilonidal sinus is more common in obese patients but the same does not hold true for umbilical pilonidal sinus. This may be cause of flattening of the hole in obese patients and less chance of migration of hair. Also the obese gen wear loose clothes which might decrease friction [2].

There is no particular agreement about the treatment of this disease, and thus various and different treatment methods (from conservative modalities to umbilectomy) exist in literature [1,3].

2. CASE REPORT

First case is of 51 year old male who presented with history of pain in the umbilical region on and

off since 1 year which had increased in intensity. There was associated pus discharge since 1 month. Patient had taken oral medications for the same without significant symptomatic relief. Tenderness and induration was present locally. Medical history was unremarkable. There was no h/o any previous surgeries. Laboratory tests were within normal limits. Clinically we could not identify any obvious cause so ultrasound of abdomen was ordered to rule out any other intrabdominal pathology.

The second patient, a 58 year old man presented with pain and swelling in the umbilical region and pus discharge since 1 week. Patient was a known diabetic well controlled on regular antidiabetic medications. Patient had history of suture repair of an Umbilical hernia 25 years back but detailed history was not available. Ultrasound was done to rule out presence of mesh as no notes were available. It confirmed no mesh or any intrabdominal collection.

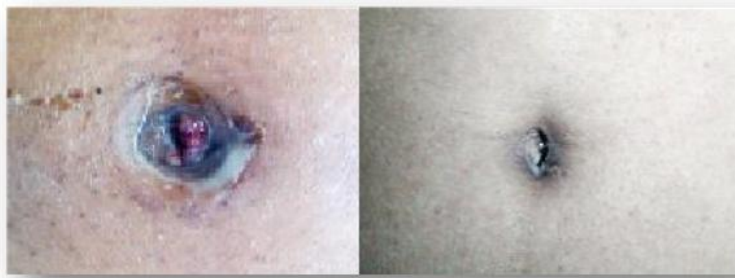

Fig. 1. Pre operative appearance: Clinical diagnostic but in our case could not see the hairs

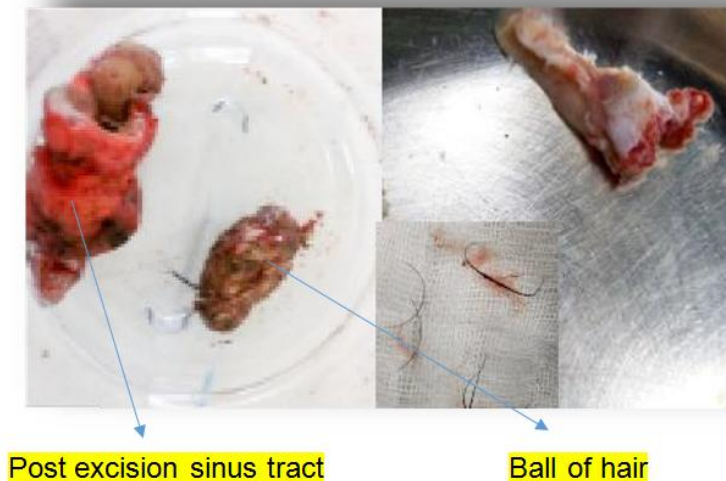


Fig. 2.

The first patient had failure of medical treatment and the second one had significant surrounding cellulitis. Both were advised umbilectomy with excision of sinus and taken up for surgery after taking written informed consent. An elliptical incision was taken enclosing the umbilicus. Small ball of hair and pus was present in the first case. Hair strands were also found in the cavity in both cases.

All associated tissue removed and thorough wash was given. If stuck to the sheath we feel it is important to excise a small part of the sheath. This was the case in the second patient where it was stuck to previous suture line. The sheath was closed with PDS suture like a hernia repair.

Closure was done in single layer over suction drain which was removed after 3 days. We feel even if the patient are not obese a suction drain decreases the incidence of seromas haematomas and subsequent wound infections. Intravenous antibiotics were given for 2 days and patient was discharged on oral antibiotics for 5 days. Histopathology report was compatible with pilonidal sinus. There was no recurrence in the follow up period of 6 months.

3. DISCUSSION

Umbilical pilonidal sinus was first described 160 years ago [4]; Fewer than 20 cases were reported before 1980. Congenital origin theory is losing popularity against acquired origin theory of pilonidal sinus disease [5]. Eryilmaz et al. [1] described male sex, young age, hairiness, deep navel and poor personal hygiene to be predisposing factors. The exact etiology still remains unknown.

The predisposing factors have been described in many studies, however, the exact etiology of this disease remains unknown [6]. The most common symptoms described are umbilical pain, bloody discharge, purulent discharge and umbilical mass with 100%, 69%, 23% and 26% respectively [1].

Pilonidal sinus is a clinical diagnosis and seldom requires investigations. A careful examination with good light will confirm diagnosis showing a tuft of hair in the sinus. A pre-operative intra-abdominal imaging may be beneficial in some patients [3,7]. This is mainly to rule out any underlying different pathology which might require a different treatment. Due to the risk of peritoneal extension of inflammation from this

condition, the infected umbilical pilonidal sinus should be treated more aggressively than its sacrococcygeal counterpart [8].

Other umbilical region anomalies such as umbilical hernia, endometriosis (for women), Sister Mary Joseph nodule, pyogenic granuloma, urachus and epidermoid cysts should be kept in mind as differential diagnosis. It is suggested that this possibility should be considered in cases of resistant or recurrent omphalitis [6].

There is no consensus about the treatment of umbilical pilonidal sinus disease. Some have described good results with extraction of hair and cleaning with antiseptic solutions [9]. Kareem et al have in a series of 134 patient's recommended conservative treatment in all patients before surgery is contemplated. However, failures of conservative methods such as hair extraction and appropriate personal hygiene make the surgical treatment inevitable for ongoing symptoms.

When surgery is decided it is important to excise the entire tract right down to the sheath to decrease chances of reoccurrence as in our cases.

The umbilicus defines the median abdominal sulcus and contributes to the curved shape of the inferior abdomen. Its absence leads to an unnatural abdominal appearance, and an abnormally shaped or misplaced umbilicus may draw undue attention to the central abdomen [10]. The absence of the umbilicus is an aesthetically and psychologically frustrating condition for patients, and sometimes poses challenges to surgeons.

Both of our male patients were counselled but neither was keen on preserving the umbilicus and so was not reconstructed.

It is important to discuss with the patients regards to their wish for reconstruction of the umbilicus as in some patients it might impact them psychologically. The reconstruction option should be offered to all patients who desire the same.

4. CONCLUSION

Umbilical pilonidal sinus should be suspected in all young hairy males with a discharging umbilical sinus. Clinical examination for hair in the umbilicus should be carefully done as ii diagnostic.

Although conservative treatment may work our experience suggests that most might need excision of the same for preventing reoccurrence and permanent relief of symptoms.

If patients are worried about cosmesis attempts must be made to reconstruct the umbilicus.

CONSENT AND ETHICAL APPROVAL

As per international standard or university standard guideline participant consent and ethical approval has been collected and preserved by the authors.

COMPETING INTERESTS

Authors have declared that no competing interests exist.

REFERENCES

1. Eryilmaz R, Sahin M, Okan I, Alimoglu O, Somay A. Umbilical pilonidal sinus disease: Predisposing factors and treatment. *World J Surg.* 2005;29(9):1158-1160.
2. Patey DH. A reappraisal of the acquired theory of sacrococcygeal pilonidal sinus and assessment of its influence on surgical practice. *Br J Surg.* 1969;56:463-466.
3. Abdulwahab BA, Harste K. Umbilical pilonidal sinus. *Ugeskr Laeger.* 2010;172(41):2848-2849.
4. Thorlakson RH. Pilonidal sinus of the umbilicus. *Br J Surg.* 1966;53(1):76-78.
5. Humphries AE, Duncan JE. Evaluation and management of pilonidal disease. *Surg Clin North Am.* 2010;90(1):113-124.
6. Colapinto ND. Umbilical pilonidal sinus. *Br J Surg.* 1977;64:494-495.
7. Gupta S, Sikora S, Singh M, Sharma L. Pilonidal disease of the umbilicus -a report of two cases. *Jpn J Surg.* 1990;20:590-592.
8. Barrett TL, Schoelch SB. Umbilical pilonidal sinus. *Cutis.* 1998;62:83-84.
9. Ali Coskun Hakan Bulus Omer, Faruk Akinici Abdullah Ozgonul. Etiological factors in umbilical pilonidal sinus. *Indian Journal of Surgery.* 2011;73(1):54-57.
10. Mazzocchi M, Trignano E, Armenti AF, Figus A, Dessy LA. Long-term results of a versatile technique for umbilicoplasty in abdominoplasty. *Aesth Plast Surg.* 2011;35:456-462.

© 2020 Panda and Bhuta; This is an Open Access article distributed under the terms of the Creative Commons Attribution License (<http://creativecommons.org/licenses/by/4.0>), which permits unrestricted use, distribution, and reproduction in any medium, provided the original work is properly cited.

Peer-review history:

*The peer review history for this paper can be accessed here:
<http://www.sdiarticle4.com/review-history/58340>*