

# Maximum Sacral Alar Width and Its Implications on Morphometry of Sacral Vestibule: A Plain CT Based Study in North West Indian Population

Tarun Kumar<sup>1</sup>, Sunny Dua<sup>1\*</sup> and Narinder Singh<sup>1</sup>

<sup>1</sup>Dr. Rajendra Prasad Government Medical College, Kangra, Tanda, Himachal Pradesh, India.

## Authors' contributions

This work was carried out in collaboration among all authors. Author TK designed the study, performed the statistical analysis, wrote the protocol and wrote the first draft of the manuscript. Author SD managed the analyses of the study. Author NS managed the literature searches. All authors read and approved the final manuscript.

## Article Information

### Editor(s):

(1) Dr. Ikem, Innocent Chiedu, Obafemi Awolowo University, Nigeria.

### Reviewers:

(1) Kastanis Grigorios, General Hospital of Heraklion, Greece.

(2) Mehmet Fatih Korkmaz, Istanbul Medeniyet University, Turkey.

Complete Peer review History: <http://www.sdiarticle4.com/review-history/57038>

Original Research Article

Received 10 March 2020

Accepted 15 May 2020

Published 24 May 2020

## ABSTRACT

**Background:** The present study was carried to understand and analyze the maximum sacral alar width and its implications on morphometry of sacral vestibule using plain computerized tomography in north western part of India, which will aid in pre operative planning to fix the posterior pelvic wall fractures with percutaneous screws in closed manner, thereby decreasing the dangers of open reduction and internal fixation.

**Methods:** This study was carried in the Department of Orthopaedics and Radiology at Dr Rajendra Prasad Govt. Medical College, Kangra at Tanda in one year. All the patients of the aged 18 years and more who came to the institute for either abdominal, pelvic and spinal pathology and presented to the Department of Radiology for computerized tomography, were included in the study.

**Results:** Alar width ranged from 25.0 to 36.0 with a mean value of  $30.39 \pm 3.41$ . Alar width was not significantly different between age-groups. There was a weak relation between alar width and age-groups 18-30 years ( $r=0.069$ ;  $P=0.388$ ), 31-40 years ( $r=0.031$ ;  $P=0.788$ ), 41-50 years ( $r=-0.066$ ;  $P=0.488$ ), 51-60 years ( $r=-0.066$ ;  $P=0.330$ ), and >60 years ( $r=-0.075$ ;  $P=0.816$ ). Alar width was

\*Corresponding author: Email: [sunydua64@gmail.com](mailto:sunydua64@gmail.com);

non-significantly ( $P=0.271$ ) higher in males in comparison to females. There existed non-significant relation of Alar width ( $r=0.038$ ;  $P=0.347$ ) with interspinous distance. There was found non-significant relation of Alar width ( $r=0.072$ ;  $P=0.077$ ) with height.

**Conclusion:** This study, is the first of its type in North Western part of India which will aid in preoperative planning to fix posterior pelvic wall fractures with percutaneous screws and thereby lessens the dangers of open reduction and internal fixation.

**Keywords:** Sacral vestibule; maximum width of the vestibule; interspinous distance.

## 1. INTRODUCTION

The sacrum exhibits a complex morphology with a high rate of variations. In view of this, exhibiting of morphology knowledge of the sacrum, with particular emphasis on iliosacral screw fixation, has become essential for pelvic trauma surgeons. Considering the fact that sacral dysmorphism occurs in 30%–40% adults, it is a very common condition [1]. The most common cause of dysmorphism is the fusion of L5 to the sacrum with a narrow osseous pathway called sacralization, which constitutes at least half of the cases. In this scenario, the sacrum is often elevated from the iliac wing, displays conspicuous mammillary processes, and has a sharper alar slope, as well. The dysmorphic upper sacral morphology creates consistent yet atypical alar pedicle (so-called safe zone or osseous pathway) sizes and angles that are very important technical and radiographic alterations when S1 and S2 sacral segment iliosacral screws are to be placed [2].

Gardner et al. quantified the obliquity and dimensions of the upper and second sacral segment iliosacral screw safe corridors and exhibited the differences between normal and dysmorphic sacral morphology in fifty patients with computerized tomography scans. All sacra were presented as normal or dysmorphic based on plain pelvic radiographs and previously described criteria. Multiple computed tomography scan reconstructions were studied and manipulated simultaneously with 6 degrees of freedom to allow for custom visualization in any plane. Sacral dysmorphism was identified in 22 patients. In these sacra, the upper sacral segment safe zone cross-section was 36% smaller than in normal sacra ( $P < 0.001$ ). No transverse screws could be inserted, but accommodating for the caudal to cranial obliquity ( $30^\circ$  vs.  $21^\circ$  in normals,  $P < 0.001$ ) and posterior to anterior obliquity (15% vs. 4% in normals,  $P < 0.001$ ) of the safe corridor, an iliosacral screw at least 75 mm in length could be placed safely in 91% of patients. A transverse screw could be

placed in 75% of normal sacra. In the second segment safe zone, the cross-sectional area was more than twice as large in dysmorphic sacra compared to normals (220 mm vs. 109 mm,  $P < 0.001$ ). The obliquity was not different on either the inlet or outlet views between groups. A transverse screw could be placed at this level in 95% of those with dysmorphic sacra and in only 50% of normal sacra [3].

The widely accepted treatment of unstable sacral fractures is operative fixation because of high chances of residual morbidity under non operative management. The aim is anatomic reduction and stern fracture fixation. There are several surgical procedures like fixation with iliosacral screws or plates, triangular osteosynthesis, ilioiliac (plates, internal fixators, and bars) and trans-sacral screws or bars. Currently, sacroiliac screws and spinopelvic internal fixators have become the implants of choice for fixation of posterior pelvic ring fractures. Whereas full weight bearing is permitted for most spinopelvic fixations, none or partial weight bearing is permitted for iliosacral screw fixations [4].

The present study was aimed to recognize and evolve in-depth understanding of the maximum alar width and its implications on morphometry of sacral vestibule in North-West Indian population presenting to our institution using plain computerized tomography, which will aid in pre operative planning to fix the posterior pelvic wall fractures with percutaneous screws, thereby reducing hazards associated with open reduction and internal fixation of fractures.

## 2. MATERIALS AND METHODS

This study was done in the Department of Orthopaedics and Radiology at Dr Rajendra Prasad Govt. Medical College, Kangra at Tanda over a period of one year. All the patients of the age 18 years and more above who came for either abdominal, lower spinal or pathology of pelvic region, came for computed tomography to

the Department of Radiodiagnosis were studied. The patients were informed about the aims, objectives and methods of the study. After informed consent was given for they were included in the study.

The study was not performed in following individuals:

1. Patients less than 18 years of age.
2. The patient who had pelvic ring anomalies.
3. Metastatic pelvic lesions.
4. Fractures in posterior pelvic bones.
5. Any operated cases of above fractures.
6. The patients who did not give the consent.
7. Old operated cases with implants in situ in lumbosacral junction.

Due care was taken to respect the privacy of the patient, patient's information was kept confidential to minimize the effect of the study on his/her physical and mental status. The subjects were placed in the supine position with fully extended knee joint with patella pointing towards the sky for during scanning. All CT scan were done as anteroposterior tomogram as well as axial sections of Sacral Vestibule. All the measurements were taken at the CT workstation. All the Measurements were measured by a junior resident (the investigator) from the Department of Orthopaedics Dr. RPGMC Tanda and supervised by consulting Orthopaedician and Radiologist.

Following parameters were measured:

- Age of the patient
- Sex of the patient
- Maximum Width of vestibule S1
- Interspinous distance
- Height of the patient

## 2.1 Analyzing the Data

The data was prepared as frequency, percentages, and median (inter quartile range; IQR). Mann Whitney U test was used find the difference between quantitative variables. The relationship between two variables was studied by Spearman correlation coefficient. P value <0.05 was considered significant. SPSS v20 was used for Statistical analyses.

## 3. MAXIMUM WIDTH OF VESTIBULE

Width of vestibule was the length of the longest antero-posterior diameter of sacral vestibule as shown in Picture 1.

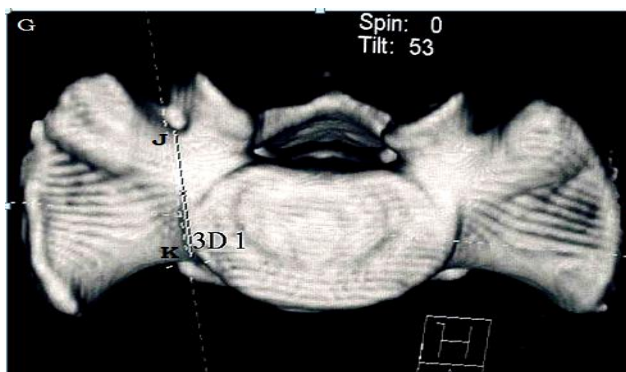
The Table 1 shows that alar width ranged from 25.0 to 36.0 with a mean value of 30.39±3.41.

**Table 1. Morphological analysis of sacral vestibule alar width (mm)**

	Alar width
Minimum	25.0
Maximum	36.0
Mean	30.39±3.41
Median	30
IQR	30

The Table 2 depicts that alar width was not significantly different between age-groups.

The Table 3 shows that there existed a weak relation between alar width and age-groups 18-30 years (r=0.069; P=0.388), 31-40 years (r=0.031; P=0.788), 41-50 years (r=-0.066; P=0.488), 51-60 years (r=-0.066; P=0.330), and >60 years (r=-0.075; P=0.816).



**Picture 1. Showing the measurement of Maximum Sacral Alar Width**

**Table 2. Relation with age (Comparative analysis of Maximum width of Vestibule S1)**

	Age-group	Mean±SD	Min-Max	P value
Alar Width	18-30 <sup>a</sup>	30.46±3.19	25-36	Pab=0.528; Pac=0.600
	31-40 <sup>b</sup>	30.17±3.60	25-36	Pad=0.920; Pae=0.759
	41-50 <sup>c</sup>	30.25±3.66	25-36	Pbc=0.887; Pbd=0.469
	51-60 <sup>d</sup>	30.49±3.35	25-36	Pbe=0.602; Pcd=0.522
	>60 <sup>e</sup>	30.75±3.33	27-36	Pce=0.647; Pde=0.795

**Table 3. Relation with age**

		Correlation coefficient (r)	P value
Alar Width	18-30	0.069	0.388
	31-40	0.031	0.778
	41-50	-0.066	0.448
	51-60	0.066	0.330
	>60	0.075	0.816

**Table 4. Relation with sex**

		Male	Female	P value
Alar width	Mean±SD	30.52±3.41	30.21±3.41	0.271
	Median	31.0	30.0	
	IQR	5.0	6.0	

The Table 4 depicts alar width was found non-significantly (P=0.271) higher in males in comparison to females.

**Table 5. Relation with interspinus distance**

	Correlation coefficient (r)	P value
Alar width	0.038	0.347

The Table 5 depicts that there was found non-significant relation of Alar width (r=0.038; P=0.347) with interspinous distance.

**Table 6. Relation with height**

	Correlation coefficient (r)	P value
Alar width	0.072	0.077

The Table 6 depicts that there existed non-significant relation of Alar width (r=0.072; P=0.077) with height.

**4. DISCUSSION**

The sacral vestibule was first time described as the three-dimensional zone that is present in the narrowest part of the iliosacral screw corridor. The sacral vestibule concept was suggested by Carlson et al. Anteroposteriorly, the vestibule is

dumbbell shaped, but it is elliptical on the sagittal section [2]. This study was planned to understand and analyze the maximum sacral alar width and its implications on morphometry of sacral vestibule using plain computerized tomography in north western part of India, which will aid in pre operative planning to fix the posterior pelvic wall fractures with percutaneous screws in closed manner, thereby decreasing the dangers of open reduction and internal fixation.

Alar width was ranged from 25.0 to 36.0 with a mean value of 30.39±3.41. Alar width was not significantly different between age-groups. There was found a weak relation between alar width and age-groups 18-30 years (r=0.069; P=0.388), 31-40 years (r=0.031; P=0.788), 41-50 years (r=-0.066; P=0.488), 51-60 years (r=-0.066; P=0.330), and >60 years (r=-0.075; P=0.816). Alar width was non-significantly (P=0.271) higher in males in comparison to females. There was found non-significant relation of Alar width (r=0.038; P=0.347) with interspinous distance. There existed non-significant relation of Alar width (r=0.072; P=0.077) with height.

The average maximum width S1 vestibules were 25.15±2.91 mm in Chinese population [5]. The above-mentioned results were comparable to our study.

Noojin et al. [6] conducted CT based study of sacral vestibule of 13 adults (6 men and 7 women) and concluded that the average vestibular width of all specimens was 28.05 mm (22.10 mm to 34.00 mm) and the vestibular height was 27.76 mm (22.80 mm to 35.90 mm). The vestibule of male was larger than those of females. They recorded significant difference in vestibule measurements on the left and the right side of the body.

The exact location, inclination, and length, to insert iliosacral screws is parallel to the long diameter with the inclination angle of the vestibule, so, these parameters are very important in preoperative assessment [7]. Due to smaller size in these parameters, the insertion location, direction of the screw, and the position relationships between the screws are particularly limited for female patients due to high chances of dimorphism [5].

## 5. CONCLUSION

This study, the first of its type in North Western part of India which will aid in preoperative planning to fix posterior pelvic wall fractures with percutaneous screws and thereby lessens the dangers of open reduction and internal fixation.

## CONSENT

As per international standard informed and written participant consent has been collected and preserved by the authors.

## ETHICAL APPROVAL

As per international standard written ethical permission has been collected and preserved by the author(s).

## COMPETING INTERESTS

Authors have declared that no competing interests exist.

## REFERENCES

1. Routt MLC, Simonian PT, Agnew SG, Mann FA. Radiographic Recognition of the Sacral Alar Slope for Optimal Placement of Iliosacral Screws: A Cadaveric and Clinical Study. *Journal of Orthop Trauma*. 1996; 10:171-7.
2. Carlson DA, Scheid DK, Maar DC, Baele JR, Kaehr DM. Safe placement of S1 and S2 iliosacral screws: The "vestibule" concept. *J Orthop Trauma*. 2000;14:264-9.
3. Gardner MJ, Morshed S, Nork SE, Ricci WM, Chip Routt ML Jr. Quantification of the upper and second sacral segment safe zones in normal and dysmorphic sacra. *J Orthop Trauma*. 2010;24:622-9.
4. Mehta S, Auerbach JD, Born CT, Chin KR. Sacral fractures. *J Amer Acad Orthop Surg*. 2006;14(12):656-65.
5. Dong Q, Tian W, and Ma B. Evaluation and clinical application of sacral S1 vestibule measurements in Chinese adults. *Int. J. Morphol*. 2014;32(1):202-7.
6. Noojin FK, Malkani AL, Haikal A, Lundquist C, Voor MJ. Cross-sectional geometry of the sacral ala for safe insertion of iliosacral lag screws: A computed tomography model. *J Orthop Trauma*. 2000;14(1):31-5.
7. Kim J-J, Jung C-Y, Eastman JG, Oh H-K. Measurement of Optimal Insertion Angle for Iliosacral Screw Fixation Using Three-Dimensional Computed Tomography Scans. *Clinics in Orthopedic Surgery*. 2016;8(2):133-9.

© 2020 Kumar et al.; This is an Open Access article distributed under the terms of the Creative Commons Attribution License (<http://creativecommons.org/licenses/by/4.0>), which permits unrestricted use, distribution, and reproduction in any medium, provided the original work is properly cited.

*Peer-review history:*

*The peer review history for this paper can be accessed here:*  
<http://www.sdiarticle4.com/review-history/57038>