

# A Rare Localization of Langerhans Cell Histiocytosis in the Hand: A Case Report

Sbai Mohamed Ali<sup>1\*</sup>, Triki Rami<sup>1</sup>, Amri Raja<sup>2</sup>, Boussem Monia<sup>3</sup> and Ayari Rabie<sup>1</sup>

<sup>1</sup>Department of Plastic, Reconstructive, Hand Surgery and Burn, Mohamed Taher Maamouri Hospital, Nabeul, Tunisia.

<sup>2</sup>Department of Internal Medicine, Mohamed Taher Maamouri Hospital, Nabeul, Tunisia.

<sup>3</sup>Department of Emergency, Mongi Slim Hospital, La Marsa, Tunisia.

## Authors' contributions

This work was carried out in collaboration among all authors. Author SMA designed the study, Author TR wrote the protocol and wrote the first draft of the manuscript. Authors Amri Raja and BM managed the analyses of the study. Author Ayari Rabie managed the literature searches. All authors read and approved the final manuscript.

## Article Information

### Editor(s):

(1) Dr. Ikem, Innocent Chiedu, Obafemi Awolowo University, Nigeria.

### Reviewers:

(1) Handra-Luca Adriana, University Sorbonne Paris Nord, France.

(2) Kastanis Grigorios, General Hospital of Heraklion, Greece.

Complete Peer review History: <http://www.sdiarticle4.com/review-history/56740>

Received 24 February 2020

Accepted 29 April 2020

Published 08 May 2020

Case Study

## ABSTRACT

Langerhans cell histiocytosis (LCH) belongs to a spectrum of rare disorders characterized by idiopathic infiltration and accumulation of abnormal histiocytes within various tissues. It touches mostly the bones and most frequently the skull. We report here a rare case of LCH localized in the hand.

*Keywords:* Langerhans cell histiocytosis; hand; bone.

## 1. INTRODUCTION

Langerhans cell histiocytosis (LCH), formerly known as "histiocytosis X", is a non-neoplastic proliferative disease that can affect

one or more organs. It comes under several forms, from the mildest form, reaching a single organ (skin, bone), to the most severe, with invasion of several systems. Bone damage is present in most patients. We present here a

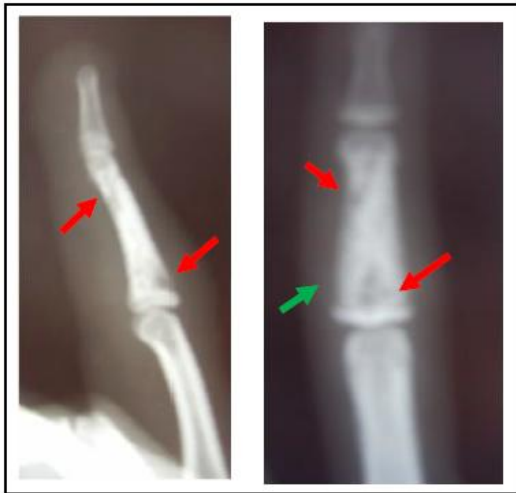\*Corresponding author: Email: mohamedali.sbai@ms.tn;

case of a boy who had a rare localization in the hand.

## 2. CASE REPORT

The present case is a 13 year-old male patient, right handed, who consulted for inflammatory pain and swelling of the 4<sup>th</sup> finger of the right hand since 6 months. There was no history of trauma or infection. Clinical examination showed an edema of the finger and mild pain on palpation of the 2<sup>nd</sup> phalanx. There was no restriction of the range of motion of the finger with flexible interphalangeal articulations. Skin examination was normal. General examination was normal.

The X-ray of the hand (Fig. 1) showed multiple osteolytic lesions of the metaphysis and diaphysis of the 2<sup>nd</sup> phalanx of the 4<sup>th</sup> right finger. Articular cartilage was respected. There was also a periosteal reaction. Thoracic X-ray was normal.



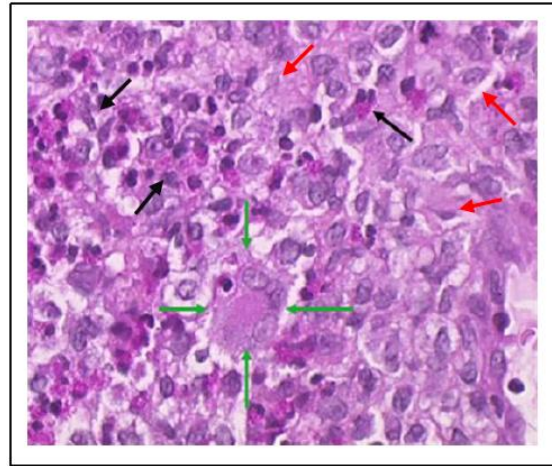
**Fig. 1. X-rays showing the lesions**  
- Red arrows: Osteolytic lesions  
- Green arrow: Periosteal reaction

Biological examinations showed an elevated erythrocyte sedimentation rate at 40. White blood cells count was normal. CRP was normal as well.

A surgical biopsy and curettage of the lesion was performed. It showed histiocytic granulomas with giant multinucleated cells, eosinophils and Langerhans cells (Fig. 2).

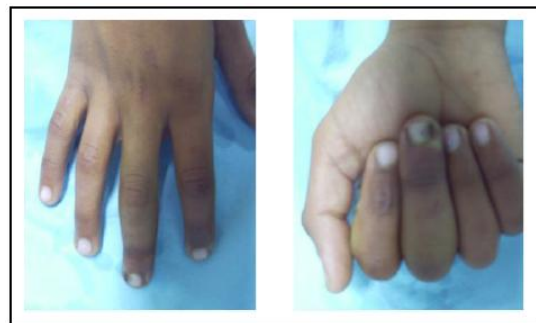The patient had an immobilization of the hand with a splint MP Stop with syndactyly of the 3<sup>rd</sup>,

4<sup>th</sup> and 5<sup>th</sup> rights fingers during 3 weeks. He had also analgesic and anti-inflammatory treatment.



**Fig. 2. Histological aspect of the lesion**  
- Red arrows: Langerhans cells  
- Green arrow: Giant multinucleated cells  
- Black arrows: Eosinophils

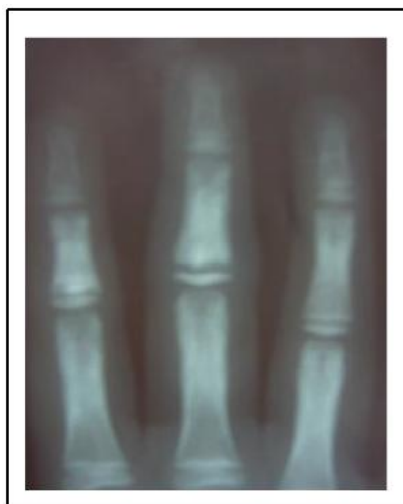The evolution was good with disappearance of the pain and the swelling within 3 weeks (Fig. 3). In 6 months, there was a complete bone reconstruction of the 2<sup>nd</sup> phalanx of the 4<sup>th</sup> right finger (Fig. 4). The patient had a consultation with a referred pediatrician who eliminated the localization of any other abnormality.



**Fig. 3. Clinical examination after 6 months**

## 3. DISCUSSION

Langerhans cell histiocytosis belongs to a spectrum of rare disorders characterized by idiopathic infiltration and accumulation of abnormal histiocytes (i.e. the Langerhans cells) within various tissues (bone marrow, skin, central nervous system, lung, liver, spleen, lymph nodes) causing focal or systemic effects [1].



**Fig. 4. X-rays after 6 months, showing reconstruction of the bone compared to the other fingers**

It was formerly known as “Histiocytosis X”, which was regrouping three major variants of the same disease: If the lesion is unifocal with a solitary bone lesion, we are talking about eosinophilic granuloma. If we have multifocal LCH with the classic triad of skull lesions, exophthalmos and diabetes insipidus, it is known as the Hand-Schüller-Christian disease. If we have fulminant LCH with multiple organ involvement, it is known as the Letterer-Siwe disease [1]. This old terminology is now replaced by a classification that is based on the site of lesions, number of involved sites and whether the disease involves risk organs (hematopoietic system, liver, or spleen) [2].

LCH occur most often in the children aged between 5 and 15 [3], and it affects 5 persons per 1 million people [4]. Occurrence in the adult is possible too, but the clinical forms are often less serious [5].

When LCH affect the bones, flat bones (skull (nearly 50%), pelvis, ribs and mandible) are the most commonly involved, followed by the spine (mainly thoracic and lumbar) [6]. About one-third of all single-bone lesions involve the long bones, most commonly the femur, followed by the humerus and tibia. Long bone involvement is more frequent in children and most lesions arise in the diaphysis (58%), metaphysis (28%), metadiaphysis (12%), or epiphysis (2%) [3]. Lesions of short tubular bones of hand and feet are only seldom reported [6]. This is why this

case is particular. There were no reports of lesions within the phalanx of the digits of the hand.

LCH are often associated with local pain and clinical examination is poor. X-rays can show well limited osteolysis lesions of the bone. Sometimes, it can show disruption of the cortical bone or periosteal reaction mimicking some tumoral lesions (like Ewing Sarcoma) or vascular like lesions [7]. The images in the X-rays can depend on the stage of the disease. In the acute stage, bony lesions may have an aggressive pattern of osteolysis and appear permeative with a wide zone of transition and a laminated periosteal reaction. In the chronic stage, lesions have a more benign appearance with well-defined sclerotic margins, a narrow zone of transition, and a mature or absent periosteal reaction [3]. MRI is superior to X-rays and CT scans to define the lesion [8]. The most common MR appearance of skeletal LCH is a focal lesion, surrounded by an extensive, ill-defined bone marrow and soft tissue reaction with low signal intensity on T1-weighted imaging and high signal intensity on T2-weighted imaging, considered to represent bone marrow and soft tissue edema, respectively [9]. In our case, MRI was not performed.

Due to the rarity of LCH, especially in the smaller bones of the foot and hand, other mimicking lesions of other diseases must be kept in mind and excluded. These lesions include osteomyelitis, tumors and even body-induced lesions [6].

Biopsy should be performed to confirm the diagnosis and eliminate other more serious diseases. Core needle or open biopsy of the lesion should be performed [1].

Treatment is often done for the patient with symptomatic lesions. The choice of treatment depends whether there is a single or multisystem involvement and the size of the lesions [6]. If the size of the lesion is smaller than 2 cm, curettage of the lesion can offer a definitive treatment [7] like this case. For bigger lesions the treatment of choice is excision, which may be combined with bone grafting. In some large-sized, multifocal lesions or multisystem disease, surgery is better combined with low-dose irradiation and chemotherapy. Chemotherapy, in the form of a combination of vinblastine and prednisolone, is effective in multisystem LCH in children and may also be given in adult [6]. For some patients,

which lesions are asymptomatic, we can do a simple observation, as lesions are known to resolve spontaneously.

#### 4. CONCLUSION

When localized in the bone, LCH can mimic infectious and tumoral lesions. Therefore, elimination of this severe diagnosis must be made before starting the treatment, especially when the lesion is located in a rare location, such as the phalanx of the digit.

#### CONSENT

As per international standard informed and written participant consent has been collected and preserved by the authors.

#### ETHICAL APPROVAL

As per international standard written ethical permission has been collected and preserved by the author(s).

#### COMPETING INTERESTS

Authors have declared that no competing interests exist.

#### REFERENCES

1. Kamal AF, Luthfi APWY. Diagnosis and treatment of langerhans cell histiocytosis with bone lesion in pediatric patient: A case report. *Ann Med Surg.* 2019;45:102-9.
2. Khung S, Budzik J, Amzallag-Bellenger E, et al. Skeletal involvement in langerhans cell histiocytosis. *Insights Imaging.* 2013;4(8):569–579. Available:<https://doi.org/10.1007/s13244-013-0271-7>
3. Chang W-F, Hsu Y-C, Wu Y-D, Kuo C-L, Huang G-S. Localized langerhans cell histiocytosis masquerading as Brodie's abscess in a 2-year-old child: A case report. *EXCLI J.* 2015;5.
4. Badalian-Very G, Vergilio JA, Fleming M, et al. Pathogenesis of langerhans cell histiocytosis. *Annu Rev Pathol.* 2013;8:1-20.
5. Christopher Z, Binitie O, Henderson-Jackson E, Perno J, Makanji RJ. Langerhans cell histiocytosis of bone in an adult: A case report. *Radiol Case Rep.* 2018;13(2):310-4.
6. Vaish A, Vaishya R, Singh LK, Kashyap V. Langerhans cell histiocytosis of a metatarsal bone in an adult female. *BMJ Case Rep.* 2019;12(10):e231343.
7. Donadieu J, Héritier S. Histiocytose langerhansienne de l'enfant. *Presse Médicale.* 2017;46(1):85-95.
8. Zhang X, Zhou J, Chai X, Chen G, Guo B, Ni L, et al. The application of x-ray, computed tomography, and magnetic resonance imaging on 22 pediatric langerhans cell histiocytosis patients with long bone involvement: A retrospective analysis. *Medicine (Baltimore).* 2018;97(17):e0411.
9. Moon TY, Lee JM, Lee IS, Choi KU, Chae JM, Kim JI, et al. MRI and histopathologic classification of langerhans cell histiocytosis. *Curr Med Imag Rev.* 2009;5: 4-18.

© 2020 Ali et al.; This is an Open Access article distributed under the terms of the Creative Commons Attribution License (<http://creativecommons.org/licenses/by/4.0>), which permits unrestricted use, distribution, and reproduction in any medium, provided the original work is properly cited.

Peer-review history:

The peer review history for this paper can be accessed here:  
<http://www.sdiarticle4.com/review-history/56740>