



Full Mouth Implant Supported Rehabilitation Involving Immediate Implant Placement in Patient with History of Periodontitis: A Case Report

Ankur Thakral^{1*}, Mriganka Barman Chowdhuri² and Prachi Gulati³

¹*Department of Oral and Maxillofacial Surgery, Military Dental Centre, Delhi Cantt, Delhi – 110010, India.*

²*Department of Periodontics, Military Dental Centre, Delhi Cantt, Delhi – 110010, India.*

³*Department of Prosthodontics, Including Crown and Bridge, Maxillofacial Prosthodontics and Oral Implantology, I.T.S. Centre for Dental Studies and Research, Ghaziabad – 201206, Uttar Pradesh, India.*

Authors' contributions

This work was carried out in collaboration among all authors. All authors participated in designing the study, managing the literature searches and writing the first draft of the manuscript searches. All authors read and approved the final manuscript.

Article Information

Editor(s):

(1) Dr. Hena Rahman, Government Medical College, India.

Reviewers:

(1) Karina Sarno Paes Alves Dias, Independent College of the Northeast (Fainor), Brazil.

(2) Leandro Araújo Fernandes, Federal University of Alfenas, Brazil.

Complete Peer review History: <http://www.sdiarticle4.com/review-history/61169>

Case Study

Received 06 July 2020
Accepted 11 September 2020
Published 21 September 2020

ABSTRACT

Background: Oral rehabilitation of periodontally compromised patient presents a challenge to clinicians. The periodontitis might have a negative influence on osseointegration leading to increased implant failure and management usually involve placing implants in healed sites after extraction of teeth with poor periodontal prognosis. However, patients who attain and maintain excellent plaque control, the technique of immediate implant placement can be utilised for oral rehabilitation.

Case Report: This case report describes comprehensive rehabilitation in a patient with history of periodontitis who underwent immediate implant placement following teeth extraction. With proper treatment planning, patient compliance and supportive periodontal therapy, good functional and aesthetic outcomes were achieved. There was no evidence of peri-implant mucositis or peri-implant bone loss after 30 months of follow-up.

*Corresponding author: Email: ankur_thakral2000@yahoo.com;

Conclusion: The technique of immediate implant placement in periodontitis susceptible patient with proper management and carefully monitored supportive periodontal therapy can be a successful treatment modality with predictable outcome.

Keywords: Dental implants; periodontitis; immediate implant placement; implant supported prosthesis.

1. INTRODUCTION

Periodontitis is the main chronic infectious disease of the oral cavity caused by the host inflammatory response to plaque biofilm accumulation. The periodontal disease, if left untreated, inevitably leads to more attachment loss and increased tooth mobility and is main cause of tooth loss. The aesthetics, mastication and speech are compromised by loss of teeth that adversely impact the quality of life. The success of osseointegrated dental implants has revolutionized dentistry. With the use of dental implants, it is possible to permanently replace missing teeth with a function and appearance close to that of the natural dentition [1].

Oral rehabilitation of periodontally compromised patient requires special attention because of the influence of the disease on the placement and survival of implants. The management approach usually involve placing implants in healed sites after extraction of periodontally compromised teeth [2]. It generally leads to increased treatment time and the resultant residual alveolar ridge atrophy following teeth extraction complicates the treatment plan for implant supported fixed prosthesis. Immediate placement of dental implants has gained popularity in the recent years [3,4,]. Recent studies have documented that implant survival rates in periodontally compromised patients are similar to healthy patients [5,6,]. Supportive periodontal therapy is of paramount importance for periodontal maintenance when placing implants in patients with chronic periodontitis. Rocuzzo et al. demonstrated survival rate of 94.7% in 15 subjects with a history of advanced periodontitis who were maintained and treated periodontally [7].

The authors reported a periodontally compromised case that involve multidisciplinary team approach for full mouth rehabilitation. It demonstrated restoration of form, function and aesthetics with immediate implant placement and implant supported fixed complete prostheses.

2. PRESENTATION OF A CASE

2.1 Diagnosis and Treatment Planning

A 48-year-old male reported to our dental centre with the chief complaint of few remaining mobile teeth in both the jaws and difficulty in chewing food. The patient desired implant supported fixed prosthesis to restore aesthetics and mastication and a single surgical intervention. His medical history was not significant and was non-smoker. Intraoral examination revealed partially edentulous arches with periodontally compromised remaining upper and lower dentition with varying degree of mobility and pathologic migration (Fig. 1A). He underwent routine blood investigations, orthopantomogram (OPG) radiograph (Fig. 1B) and cone beam computed tomography (CBCT) scan. Radiographic examination revealed horizontal and vertical bone loss with respect to remaining teeth and reduced residual alveolar bone height in bilateral maxillary first molar region with maxillary sinus pneumatisation. He was diagnosed as a case of advanced periodontitis. The patient was informed that there is a higher risk of peri-implant disease, however, clinically acceptable results can be achieved with supportive periodontal therapy. The patient was educated and motivated regarding oral hygiene maintenance. He was planned for extraction of remaining teeth, bilateral maxillary sinus augmentation and immediate implant placement. The initial periodontal therapy consisted of thorough training in techniques of plaque control with scaling and root planing. The diagnostic impressions of maxillary and mandibular arches were made to fabricate diagnostic models and surgical guide.

2.2 Surgical Phase

All sterilization and disinfection protocols were followed prior to surgery. The surgical procedure was done under local anaesthesia and involved atraumatic extractions of remaining teeth followed by thorough socket debridement. The maxillary sinus membrane was elevated bilaterally using lateral window approach. The

vertical bone augmentation was done with particulate bovine xenograft (Geistlich Bio-Oss; Geistlich Pharma AG; Wolhusen; Switzerland) and platelet-rich fibrin mixture and covered with a collagen membrane (Biogide, Geistlich Pharma AG, Wolhusen; Switzerland). Immediate placement of 8 implants (Myriad-Plus; Equinox Medical Technologies B.V. de Stuwdam; Netherlands) in the maxillary arch and 7 implants in the mandibular arch in accordance with the planned position was done following the manufacturer's instructions (Fig. 1C). All implants achieved good primary stability with a minimum torque of 20-45 Ncm. The bone augmentation was carried out in the other regions after immediate implant placement as needed.

Patient was prescribed antimicrobial therapy of amoxicillin/clavulanic acid 625 mg orally every 8 h for 7 days, starting 1 day before surgery and 0.12% chlorhexidine mouth rinse three times daily for 7 days with instructions to maintain meticulous oral hygiene. He was recalled after a week for suture removal. The interim removable complete dentures relined with soft tissue conditioner were delivered so as not to compress

the sites of healing. Patient was followed-up every month for oral hygiene evaluation and maintenance.

2.3 Prosthetic Phase

At 4-month post-surgery, the second phase of treatment was done. All the implants had osseointegrated except one implant at the canine site of first quadrant. During second-stage surgery, cover screws were removed and healing abutments were placed to form gingival collars around the implants (Figs. 2A – 2C). An abutment level impression was made using alginate impression material to fabricate study models. A custom tray with window cut through the implant was fabricated for open tray implant level impression. Open tray transfer copings were tightened on each fixture and polyvinyl siloxane elastomeric impression material was used to record the definitive impression. Once material was set, impression copings were unscrewed and impression was removed from the patient's mouth (Figs. 3A and 3B). The secondary models were poured following attachment of implant analogs to impression copings.

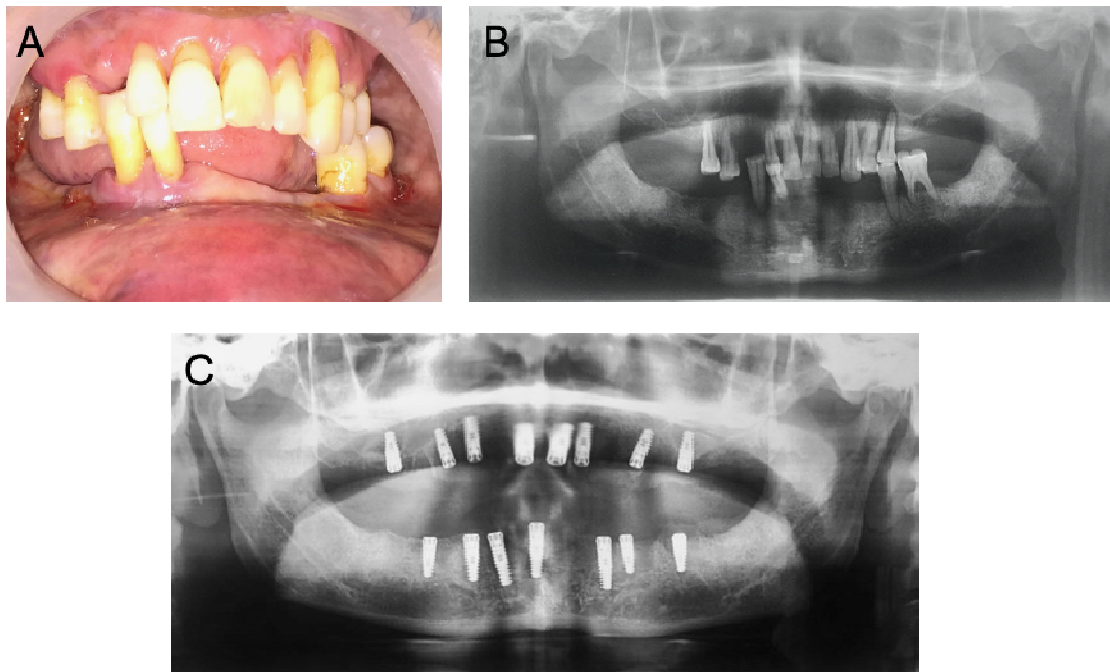


Fig. 1. (A) Pre-operative intraoral view and (B) orthopantomogram with bone loss and increased sinus pneumatization. (C) Orthopantomogram immediately following implant placement

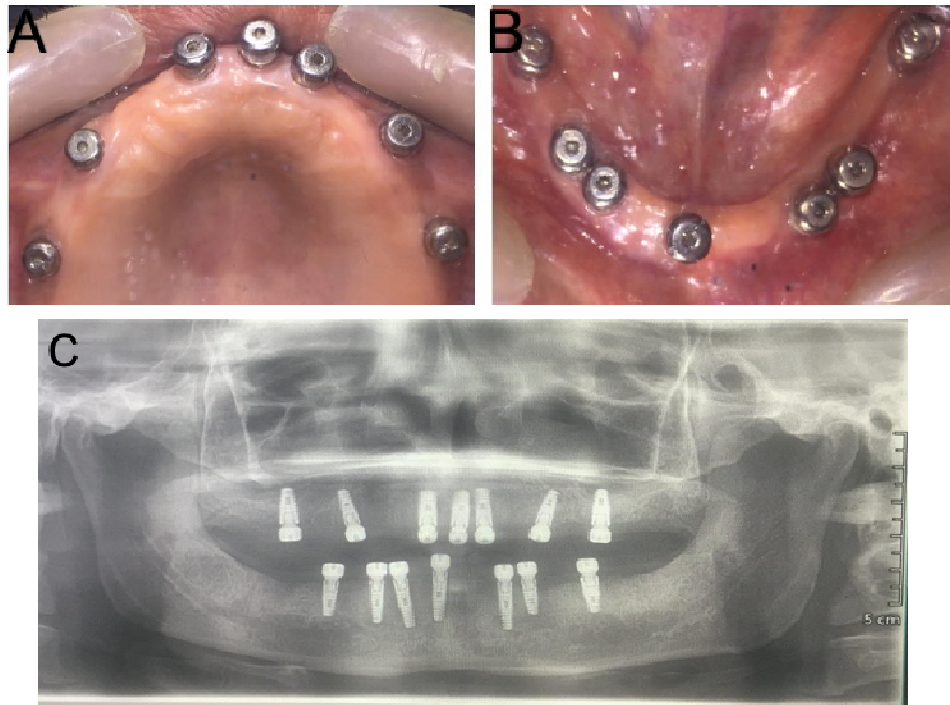


Fig. 2. Healing abutments in place. (A) Maxillary view. (B) Mandibular view. (C) Orthopantomogram

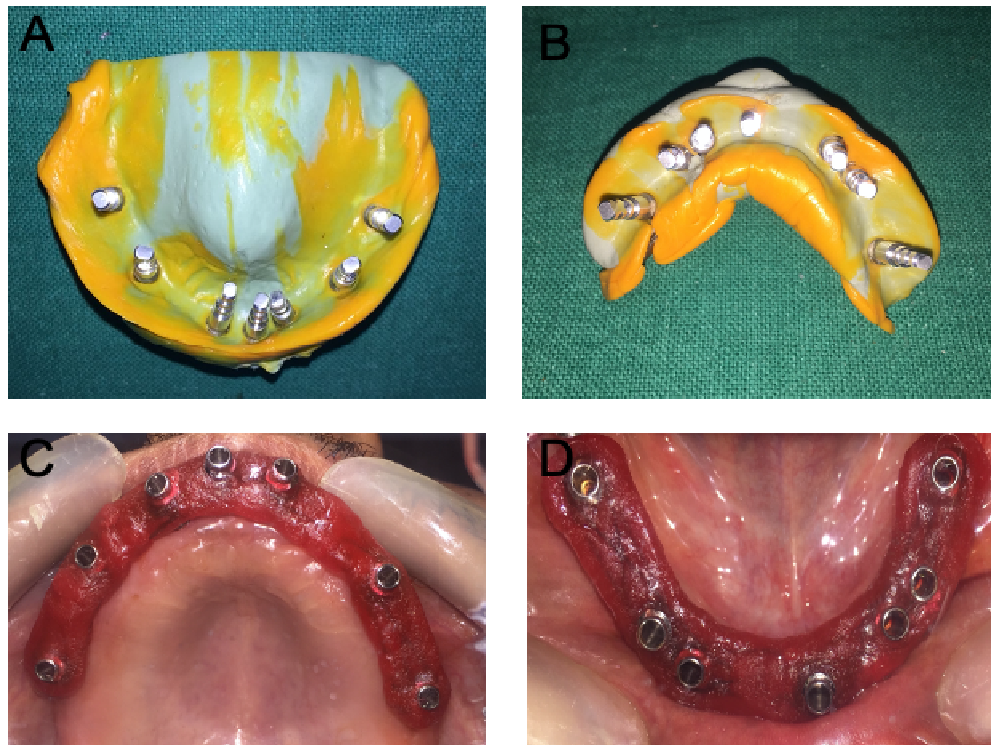


Fig. 3. (A) Definitive implant level maxillary impression. (B) Mandibular impression. (C) Maxillary resin jig in-situ. (D) Mandibular resin jig in-situ

The resin jig was fabricated using pattern resin (Pattern Resin LS; GC America Inc.; IL; USA) with definitive abutments in place (Figs. 3C and 3D). The jig was verified both clinically and radiographically for marginal discrepancy. Screw retained single unit prosthesis was planned for maxillary arch and screw retained split prosthesis for mandibular arch. Customised acrylic base plates were made and occlusal rims were constructed to record the maxillo-mandibular relation using arbitrary face-bow (Hanau Spring-Bow Earpiece; WhipMix Corporation; Colorado; USA). Afterwards, master casts were mounted on a semi-adjustable articulator (Hanau Wide-View; WhipMix Corporation; Colorado; USA). Artificial teeth were chosen and were set up in order to achieve the mutually protected occlusion of the forthcoming fixed prostheses on the mock-ups. The mock-up trial was done and following minor corrections, mock-ups were mounted on the master casts again. A putty silicone elastomer index was made labially, in order to cover the mock-up and the master cast together. Mock-ups were removed and the remaining space was used for the construction of the definitive prostheses.

Wax patterns were fabricated (Figs. 4A and 4B) and then the patterns were sprued and invested. Cast cobalt-chromium metal framework was fabricated by lost wax technique. The passive fit of metal framework was verified in patient's mouth. Shade selection was done and ceramic build-up was carried out according to silicone index. The bisque trial was done in patient's mouth and centric and eccentric relations were improved and interferences were eliminated prior

to the glazing. Finally, full mouth implant supported metal-ceramic maxillary and mandibular prostheses were screwed and access holes were closed with composite restorative material. Optimal aesthetic results (Figs. 5A and 5B) and patient satisfaction were achieved. Post-treatment OPG (Fig. 5C) was taken and instructions were given regarding oral hygiene and good maintenance of the prosthesis. Patient was prescribed interdental brushes and powered water irrigation system. He was scheduled for regular maintenance therapy at 3 months' interval. During these visits periodontal assessment was carried out with routine supragingival and subgingival debridement. Patient had completed 30 months of follow-up and all the implants were stable with no signs of inflammation. Radiographic examination revealed no evidence of peri-implant radiolucency. There was no prosthesis complications like ceramic fracture and unscrewing of abutments.

3. DISCUSSION

Implant treatment in periodontally compromised patients is a challenging task. Understanding the disease and managing patient expectations form an integral part of implant therapy in these patients. The studies have revealed a negative influence of periodontitis on osseointegration with higher incidence of peri-implantitis, greater marginal bone loss and increased rate of implant failure [8,9]. Pjetursson et al. reported that residual periodontal pockets more than 5mm increases the risk for losing peri-implant bone [9].

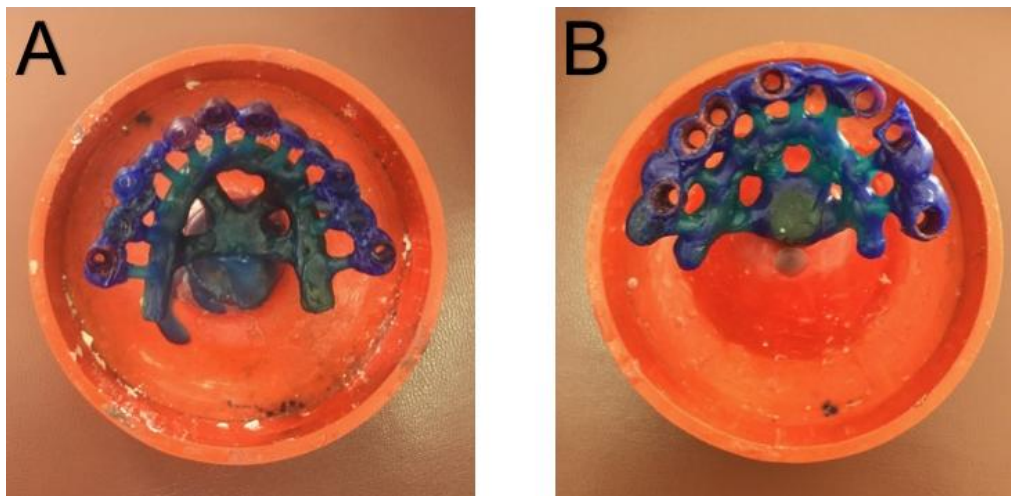


Fig. 4. (A) Maxillary wax pattern. (B) Mandibular wax pattern

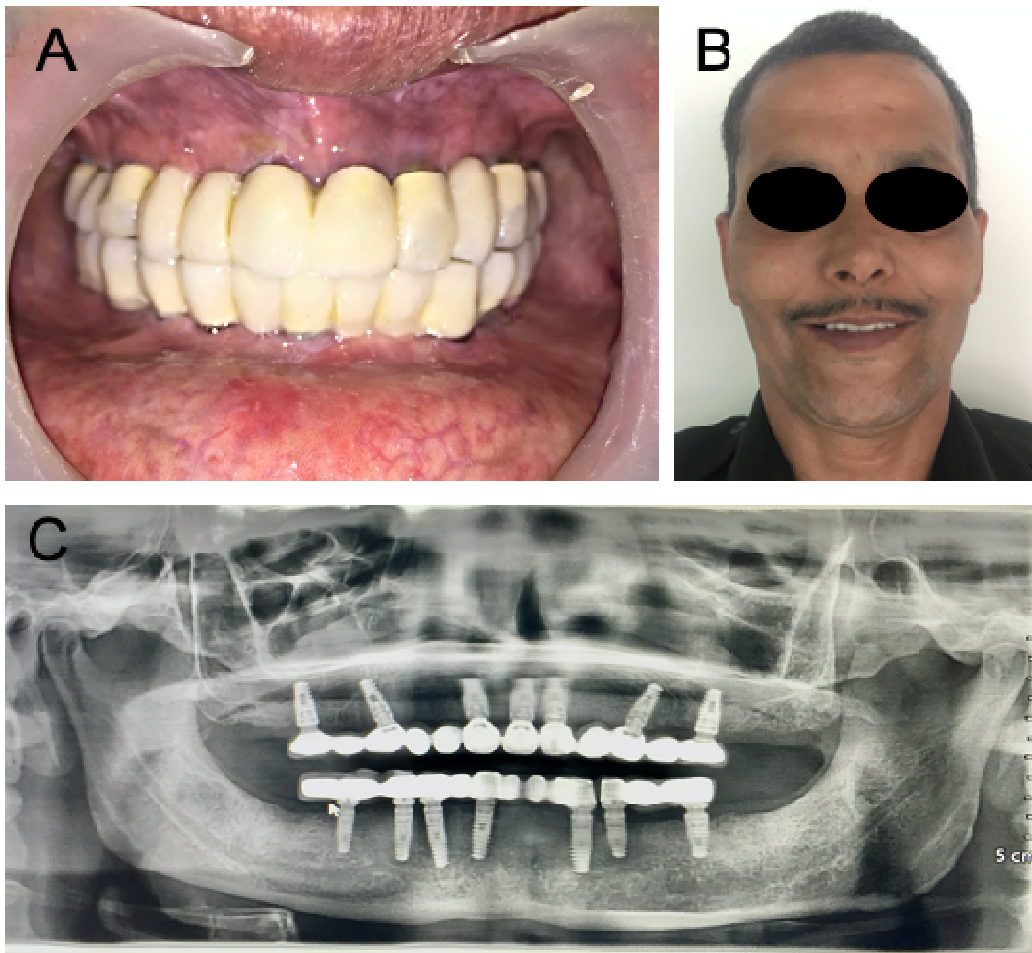


Fig. 5. (A) Post-treatment intraoral view of implant supported metal-ceramic prostheses. (B) Patient's smile after treatment. (C) Orthopantomogram following loading of prostheses

It was suggested that periodontitis persists even after tooth extraction and may impact the survival rate and long term prognosis of dental implants. However, presently there is no appropriate scientific evidence to definitely conclude that individuals with a previous history of periodontitis demonstrate increased failure rates when rehabilitated with dental implants [5,6]. A systematic review conducted by Zangrando et al. [10] revealed satisfactory outcomes and high survival rates after 10 years of follow-up in periodontitis patients. Hardt et al. [11] reported implant survival rate of 92% in patients with chronic periodontitis versus 96.7% in periodontally healthy patients. Statistically no significant differences were found between the two groups with regards to mean bone loss after 5 years [11]. In the present case report, an implant survival rate of 93.3% was reported.

The bone resorption following extraction in patients with advanced periodontitis often present a challenge for implant supported comprehensive rehabilitation. Most often, the patient require major bone grafting procedures that involve frequent surgical visits. The immediate implant placement is an effective treatment modality that abbreviates the surgical time frame [3,4]. A systematic review has reported comparable survival rate and prognosis of immediate implantation with that of delayed implant placement [4]. Good clinical outcomes with a survival rate of 100% and low marginal bone loss has been reported following immediate loading of implants placed in fresh extraction sockets in periodontally compromised patient [12].

Supportive periodontal therapy is of utmost importance for the maintenance of periodontal

health around implants in patients with periodontitis. The patient compliance in plaque control program forms the mainstay in improving prognosis of dental implant therapy. It has been emphasized that periodontal treatment prior to placement of dental implants significantly increases the survival rates of dental implants in periodontally compromised patients as residual periodontal pockets might lead to biological complications [13]. Prophylactic antibiotics in addition to chlorhexidine rinse are frequently administered prior to placement of implants to minimize the risk of infection. The recall visits form the basis of long term success after implant placement and prevent recurrence of periodontitis. A 10-year implant survival rate have been reported in patient with a history of periodontitis with carefully monitored supportive periodontal therapy [14].

Appropriate diagnosis and treatment planning is the key to successful full mouth rehabilitation. The accuracy of every component and step in the process is essential. The ideal implant position should be determined by the proposed location of the new teeth to achieve good aesthetics, loading characteristics and masticatory function. Incorrect positioning of implants too buccally, palatally or deep compromises the treatment outcomes. A passive fit is critical for the maintenance of osseointegration of implants in fixed prosthesis and not achieving it, results in biological and mechanical complications [15]. Passive fit is challenging to achieve in multi-unit implant supported fixed prosthesis and multiple techniques are used for it. However, errors can be introduced in the framework during procedures like, wax-up, casting, pouring, indexing and soldering. Impression is the foremost and critical step to ensure passive fit of implant framework. Open tray implant level impression is more accurate in case of multiple implants and offers greater flexibility in selection and modification of abutments [16]. In the present case, splinting of impression copings was done during impression procedure using pattern resin, to stabilize and prevent the rotational, horizontal and vertical movement of the impression copings. Resin jig verification and casting trial were done to ensure passive fit of the prosthesis at every step.

The prosthesis fabrication involving multiple implants is a challenging task. In the present case, maxillary one-piece prosthesis was designed with no cantilevers and cross-arch

stabilization for even stress distribution. In case of mandibular full arch fixed prosthesis, flexure of mandible may create stresses on the implants posterior to the interforaminal region and splitting the framework near the region of mental foramen can help to allow the flexure of mandible without causing undue forces to the implants [17]. Therefore, framework was split on the right side between canine and premolar to compensate for mandibular flexure. Screw retained prostheses were fabricated as cemented restorations carry the risk of biological complications. There are reports that excess cement present in the peri-implant tissues after placement of cemented implant restorations has been associated with peri-implantitis and increased risk of peri-implant bone loss [18].

4. CONCLUSION

To conclude, clinically acceptable aesthetic and functional outcomes can be obtained by immediate placement of dental implants in patient with a history of periodontitis. The survival rate and prognosis of immediate implantation following teeth extraction is comparable with that of delayed implantation. However, supportive periodontal therapy adequate infection control, patient compliance and motivational reinforcement to oral hygiene are necessary requirements for treatment to be successful, predictable and durable.

CONSENT AND ETHICAL APPROVAL

Written informed consent was obtained from the patient and permission from institutional ethical committee was obtained (Letter No. 4202/GC/2018).

COMPETING INTERESTS

Authors have declared that no competing interests exist.

REFERENCES

1. Jemt T, Johansson J. Implant treatment in the edentulous maxillae: a 15-year follow-up study on 76 consecutive patients provided with fixed prostheses. *Clin Implant Dent Relat Res.* 2006;8(2):61-9. DOI: 10.1111/j.1708-8208.2006.00003.x PMID: 16774591
2. Jiang BQ, Lan J, Huang HY, Liang J, Ma XN, Huo LD, et al. A clinical study on the

- effectiveness of implant supported dental restoration in patients with chronic periodontal diseases. *Int J Oral Maxillofac Surg.* 2013;42(2):256-9.
DOI: 10.1016/j.ijom.2012.08.001.
PMID: 23021323
3. Chiapasco M. Early and immediate restoration and loading of implants in completely edentulous patients. *Int J Oral Maxillofac Implants.* 2004;19(Suppl):76-91.
PMID: 15635948
 4. Lang NP, Pun L, Lau KY, Li KY, Wong MC. A systematic review on survival and success rates of implants placed immediately into fresh extraction sockets after at least 1 year. *Clin Oral Implants Res.* 2012;23(Suppl)5:39-66.
DOI: 10.1111/j.1600-0501.2011.02372.x
PMID: 22211305
 5. Cornelini R, Cangini F, Covani U, Wilson TG Jr. Immediate restoration of implants placed into fresh extraction sockets for single-tooth replacement: A prospective clinical study. *Int J Periodontics Restorative Dent* 2005;25(5):439-447.
PMID: 16250566
 6. Wang P, Tang C, Tang Y, Wu Y. Immediate implant placement and complete mouth rehabilitation with CAD-CAM titanium frameworks and cemented crowns for a patient with severe periodontal disease: A clinical report. *J Prosthet Dent.* 2018;119(4):511-515.
DOI: 10.1016/j.prosdent.2017.05.005 Epub 2017 Aug 4.
PMID: 28781070
 7. Rocuzzo M, De Angelis N, Bonino L, Aglietta M. Ten-year results of a three-arm prospective cohort study on implants in periodontally compromised patients. Part 1: implant loss and radiographic bone loss. *Clin Oral Implants Res.* 2010;21(5):490-496.
DOI: 10.1111/j.1600-0501.2009.01886.x.
 8. Evian CI, Emling R, Rosenberg ES, Waasdorp JA, Halpern W, Shah S, et al. Retrospective analysis of implant survival and the influence of periodontal disease and immediate placement on long-term results. *Int J Oral Maxillofac Implants.* 2004;19(3):393-398.
PMID: 15214224.
 9. Pjetursson BE, Helbling C, Weber HP, Matuliene G, Salvi GE, Bragger U, et al. Peri-implantitis susceptibility as it relates to periodontal therapy and supportive care. *Clin Oral Implants Res.* 2012;23(7):888-94.
DOI: 10.1111/j.1600-0501.2012.02474.x
PMID: 22530771
 10. Zangrando MS, Damante CA, Sant'Ana AC, Rubo de Rezende ML, Gregghi SL, Chambrone. Long-term evaluation of periodontal parameters and implant outcomes in periodontally compromised patients: a systematic review. *J Periodontol.* 2015;86(2):201-21.
DOI: 10.1902/jop.2014.140390
PMID: 25272977
 11. Hardt CR, Grondahl K, Lekholm U, Wennstrom JL. Outcome of implant therapy in relation to experienced loss of periodontal bone support: a retrospective 5- year study. *Clin Oral Implants Res.* 2002;13(5):488-94
DOI: 10.1034/j.1600-0501.2002.130507.x
PMID: 12453125
 12. Cornelini R, Cangini F, Covani U, Wilson TG Jr. Immediate restoration of implants placed into fresh extraction sockets for single-tooth replacement: A prospective clinical study. *Int J Periodontics Restorative Dent* 2005;25(5):439-47.
PMID: 16250566
 13. Karoussis IK, Salvi GE, Heitz-Mayfield LJ, Bragger U, Hammerle CH, Lang NP. Long-term implant prognosis in patients with and without a history of chronic periodontitis: a 10-year prospective cohort study of the ITI Dental Implant System. *Clin Oral Implants Res* 2003;14:329-339.
DOI: 10.1034/j.1600-0501.000.00934.x
PMID: 12755783
 14. Marija P.P., Daniela V.S., and Kiro I. Ten Years Follow-up after Dental Implant Therapy in Patient with a Chronic Periodontitis: A Case Report. *International Journal of Clinical Case Reports.* 2016;6(14):1-7.
DOI: 10.5376/ijccr.2016.06.0014
 15. Buzayan MM, Yunus NB. Passive fit in screw retained multi-unit implant prosthesis understanding and achieving: a review of the literature. *J Indian Prosthodont Soc.* 2014;14(1):16-23.
DOI: 10.1007/s13191-013-0343-x
PMID: 24604993
 16. Assuncao WG, Filho HG, Zaniquelli O. Evaluation of transfer impressions for osseointegrated implants at various angulations. *Implant Dent.* 2004;13(4):358-366.
DOI: 10.1097/01.id.0000144509.58901.f7
PMID: 15591998

17. Gowd MS, Shankar T, Ranjan R, Singh A. Prosthetic Consideration in Implant-supported Prosthesis: A Review of Literature. J Int Soc Prev Community Dent. 2017;7(Suppl 1):S1-S7.
DOI: 10.4103/jispcd.JISPCD_149_17
PMID: 28713760
18. Wilson TG Jr. The positive relationship between excess cement and peri-implant disease: a prospective clinical endoscopic study. J Periodontol. 2009;80(9):1388-92.
DOI: 10.1902/jop.2009.090115
PMID: 19722787

© 2020 Thakral et al.; This is an Open Access article distributed under the terms of the Creative Commons Attribution License (<http://creativecommons.org/licenses/by/4.0>), which permits unrestricted use, distribution, and reproduction in any medium, provided the original work is properly cited.

Peer-review history:
The peer review history for this paper can be accessed here:
<http://www.sdiarticle4.com/review-history/61169>