



Research Article

Effect of Curcumin and N-Acetylcysteine on Brain Histology and Inflammatory Factors (MMP-2, 9 and TNF- α) in Rats Exposed to Arsenic

Mostafa Fallah¹, Najmeh Moghble¹, Iraj Javadi¹, Hossein Bahadoran², Alireza Shahriary^{3*}

¹Department of Toxicology, Faculty of Pharmacy, Islamic Azad University, Shahreza Branch, Shahreza, Iran.

²Department of Anatomy, Baqiyatallah University of Medical Sciences, Tehran, Iran.

³Chemical Injuries Research Center, Systems Biology and Poisonings Institute, Baqiyatallah University of Medical Sciences, Tehran, Iran.

Article Info

Article History:

Received: 22 May 2018
Revised: 4 September 2018
Accepted: 5 September 2018
ePublished: 30 December 2018

Keywords:

-Curcumin
-Inflammation
-MMPs
-N-acetylcysteine
-TNF- α

ABSTRACT

Background: Arsenic is a toxic element that widely widespread in environment. Inflammation is now considered as one of the major mechanisms implicated in arsenic poisoning. Curcumin (Cur) and N-acetylcysteine (NAC) are potential antioxidants that protect cells against inflammation. This study aimed to compare the protective effect of Cur and NAC on brain histology and inflammatory factors, including matrix metalloproteinases-2, -9 (MMP-2, 9) and tumor necrosis factor- α (TNF- α) in rats exposed to single dose of arsenic.

Methods: Rats were exposed to single dose of arsenic (20mg/kg, by gavage) for 30 days and then treated with 300mg/kg NAC (by gavage) and 100mg/kg Cur (by gavage), individually. Serum level of TNF- α was measured using specific ELISA kits. MMP2 and MMP9 contents were measured using Gelatin Zymography method. Brain samples were collected for histopathological and morphological examinations.

Results: Arsenic treatment induced white matter lesions and cellular damages at hippocampal CA1 area of the brain. The number of hippocampal CA1 pyramidal cells was significantly declined in arsenic exposed rats ($p < 0.05$). Treatment with NAC and Cur improved these abnormalities. The mean levels of MMP2, MMP9 and TNF- α inflammatory biomarkers were slightly declined after treatment with NAC and Cur ($p > 0.05$).

Conclusion: NAC and Cur play an important role in protecting the hippocampal CA1 cells injury induced by arsenic.

Introduction

Arsenic is a toxic and heavy metal that widely widespread in environment.¹ It can be found in water, air and soil and chronic exposure to it has now become a major public health problem.² Human exposure to arsenic (As) increases the risk of many disorders including cardiovascular and lung diseases, leukemia, cancers, hepatotoxicity, neurotoxicity, and diabetes.³⁻⁶ Nevertheless, the mechanisms in which arsenic induces these abnormalities are not well-understood.

Recent evidences have indicated that arsenic induces cellular toxicity through the inhibition of approximately 200 enzymes involved in cellular energy pathways, DNA synthesis and repair.⁷ Oxidative stress and inflammation induced by excessive production of reactive oxygen species (ROS) is now considered as one of the main mechanisms of arsenic toxicity.⁸ ROS can interact with DNA, lipids and proteins to stimulate severe damages including DNA breaks, deletions, membrane disability and as the result cell death and apoptosis.^{9,10} Arsenic exposure can be involved in production of different types of ROS such as superoxide anion ($O_2^{\cdot-}$), hydrogen

peroxide (H_2O_2), and hydroxyl radicals (OH^{\cdot}).¹¹ Chronic exposure to arsenic was reported to be associated with overproduction of ROS in the liver,¹² increased production of lipid peroxide in serum,¹³ and depletion of blood antioxidants.¹⁴ It is also associated with an increase in the C-reactive protein (CRP) in the liver and kidney,¹⁵ leukocytes recruitment at the site of injuries,¹⁶ proinflammatory cytokines such as interleukin-6 (IL-6) and IL-8.¹⁷ Therefore, it is expected that antioxidant therapy may be helpful to mitigate the arsenic toxicity in exposed individuals.

N-acetylcysteine (NAC) is an acetylated cysteine residue that improves the protective ability of the cell against oxidative stress, infections, toxic assault, and inflammatory conditions.^{18,19} Curcumin (Cur) is a natural component that has strong antioxidative and anti-inflammatory activities.²⁰ A large number of studies have illustrated that both NAC and Cur attenuate arsenic-induced toxicity. For example, recent studies have indicated that NAC and Cur can attenuate arsenic-induced hepatotoxicity,²¹ renal toxicity, kidney, brain,²²

*Corresponding Author: Alireza Shahriary, E-mail: Shahriary961@gmail.com

©2018 The Authors. This is an open access article and applies the Creative Commons Attribution (CC BY), which permits unrestricted use, distribution and reproduction in any medium, as long as the original authors and source are cited. No permission is required from the authors or the publishers.

reprotoxicity,²³ DNA damage,²⁴ oxidative stress, inflammation, and apoptosis.²⁵

Although several studies have considered the arsenic-induced toxicity in different tissues, less information is available about anti-inflammatory and protective effects of NAC and Cur during and after arsenic exposure. We hypothesize that treatment with NAC and Cur may help maintain brain health by declining inflammation. Therefore, the present study is designed to compare the protective effects of NAC and Cur administration on histological alterations and inflammatory mediators, including matrix metalloproteinases-2, -9 (MMP-2, 9) and tumor necrosis factor- α (TNF- α), in rats exposed to single dose of arsenic.

Materials and Methods

Animals

In this experimental study, 36 male Wistar rats (6-8 weeks of age) with a body weight of 150-200 g were provided from the Baqiyatallah University of Medical Sciences. After a period of one week adaptation with lab environment, rats were randomly allocated into 6 groups, including control, G2 (arsenic), G3 (arsenic + NAC), G4 (arsenic + Cur), G5 (arsenic + NAC, post treatment) and G6 (arsenic + Cur, post treatment). Rats in each group were housed 3 per cage (55 × 30 × 20 cm) in a climate controlled room (ambient temperature of 22 ± 2°C, humidity 55 ± 2, and a 12:12 light/dark cycle) and had free access to food (10g/kg/day) and tap water. The study was approved by the animal care and use committee at the Islamic Azad University of Shahre Reza, Iran.

Treatments

Arsenic and Cur were purchased from the Merck Company (German), while NAC was purchased from the Sigma Aldrich Company (USA). Rats in G2 group received a single gavage administration of arsenic (20mg/kg, by gavage) every other day for 30 days²⁶. Rats in G3 group received gavage administration of arsenic (20mg/kg) and NAC (300mg/kg, by gavage) at same time every other day for 30 days.²⁶ Rats in G4 group treated with concomitant administration of arsenic (20mg/kg) and Cur (100mg/kg) every other day for 30 days.²⁶ Rats in G5 group gained a gavage administration of arsenic (20mg/kg) for 4 weeks and then they treated with NAC (300mg/kg) for 2 weeks. Rats in G6 group obtained a gavage administration of arsenic (20mg/kg) for 4 weeks and then they treated with Cur (300mg/kg) for 2 weeks. The control group was fed with normal pellet and water for 30 days.

Blood and tissue Samples

On finishing the experiment (24h after the final treatment), rats were anesthetized with diethyl ether and then blood samples were collected from the abdominal aorta.²⁷ Blood samples were centrifuged at 2000 rpm for 10 min and serum was stored at -20 °C until further examinations. For histological examinations, brain tissue

was removed and fixed in 10% formalin for at least 48h. Fragments were dehydrated in graded series of ethanol, embedded in paraffin and sectioned using an automatic microtome at 4-5 mm thickness. For histological and morphological examinations, the sectioned tissues were stained with Haematoxylin-Eosin (H&E) and examined by light microscopy.

TNF- α measurement

The level of TNF- α in serum samples was measured by the Rat TNF- α ELISA Kit provided by Diaclone Company (French).

MMP2 and MMP9 measurement

MMP2 and MMP9 were measured using Gelatin Zymography method, as previously described in detail.²⁸ Briefly, serum specimen was separated by electrophoresis in 30% polyacrylamide gel impregnated with 3% of gelatin under non-reducing conditions. Serum total proteins concentration was determined by Bradford method.²⁹ Each lane of a SDS-polyacrylamide gel was loaded with 15 μ g of total protein mixed with loading buffer. All samples were provided in duplicate and averaged. Electrophoresis was performed under a constant current of 90 MA until the bromophenol blue reaches the bottom of the gel. After electrophoresis, the gels were washed in distilled water and then soaked in renaturing buffer (60 min in 2.5% Triton X-100) with gentle shaking at room temperature in order to remove the sodium dodecyl sulfate. After that, the gels were washed in distilled water 2-3 times and then soaked in zymogram developing buffer (50 mM Tris Base, pH 7.4 containing 200 mM NaCl, 4 mM CaCl₂ and 0.02 M Tween) for 48h at 37° C. After washing the gels with distilled water 3 times for 10 min, they were stained with Coomassie Blue and stained with gentle agitation for 1 hr. The areas of proteinase activity were visualized as clear bands by washing the gels with distilled water and then destaining solution (40% methanol and 10% glacial acetic) for 30 min. For quantification of gelatin degradation, gels were scanned and were assessed by densitometer analysis method (JS800 model) creating an arbitrary unit (AU) for each band by calculating the integrated area under each peak (Image software). The activity values of pro- and active MMP-2 and MMP-9 for each specimen were expressed in AU related to the level of pro-MMP-2 of the positive-control standard loaded on each gel (Figure 1). Each band's activity was reported as the mean of two different measurements of the same sample.

Statistical analysis

All data are reported as means ±SD. The mean of all parameters between different groups was compared using the One-Way ANOVA: Post Hoc-Tukey test. Data were analyzed using SPSS (version 19). A p<0.05 was considered as significant.

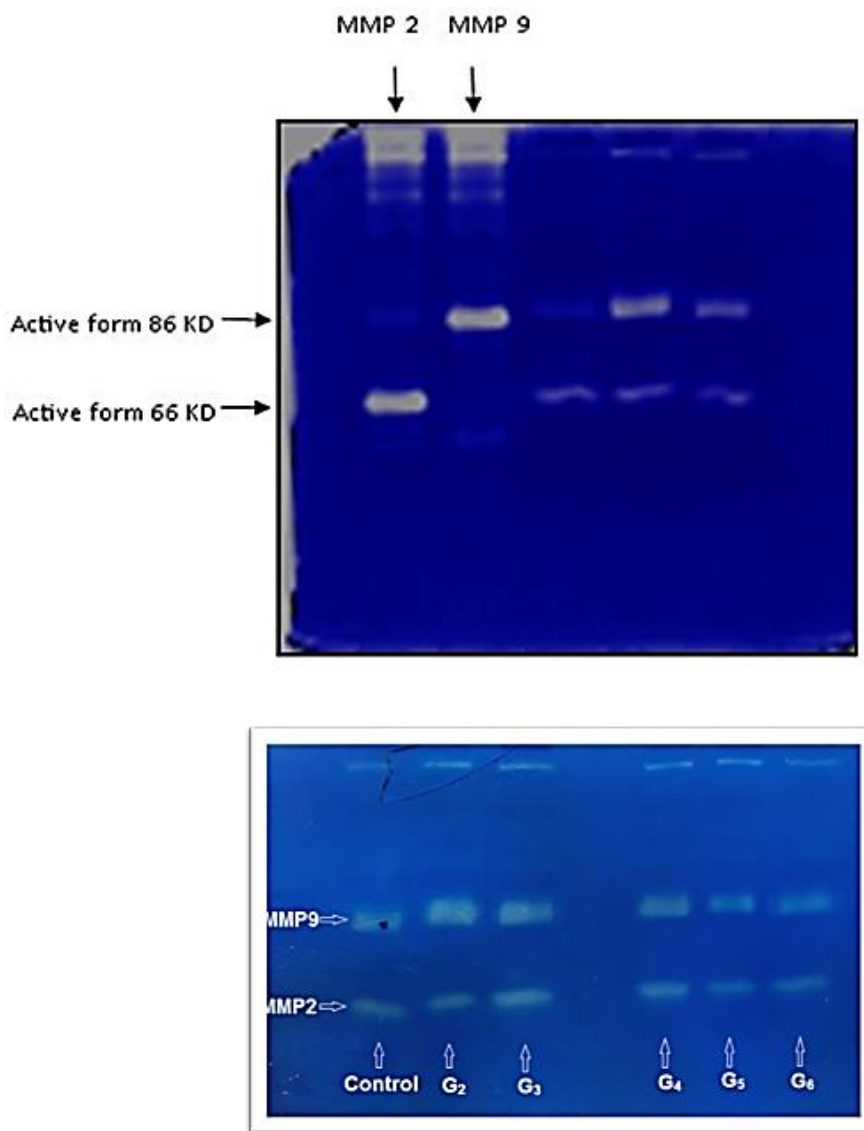


Figure 1. Gelatin zymogram image including MMP-9 and MMP-2.

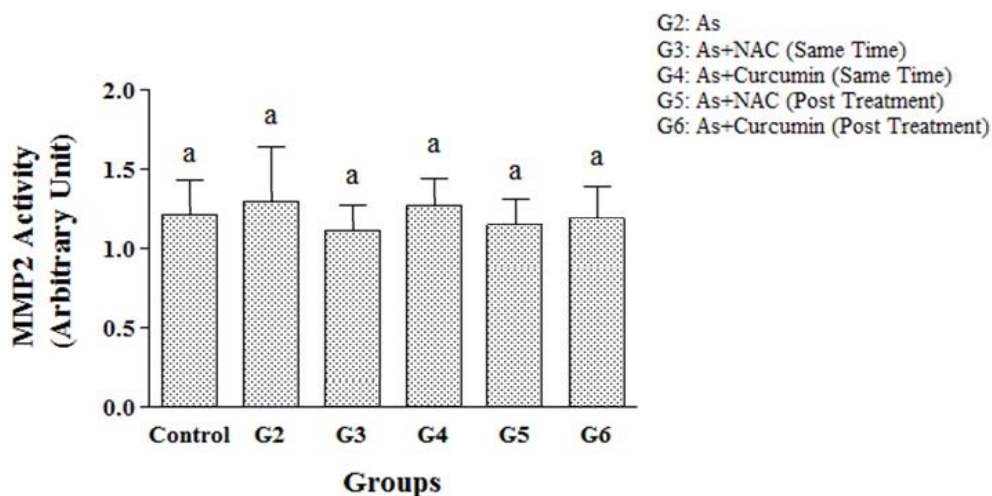


Figure 2. Comparison of the MMP2 mean values between control, G2, G3, G4, G5 and G6 groups. Non-significant difference was found in the mean of MMP2 between the groups ($p=0.981$). G2 (arsenic), G3 (arsenic + NAC), G4 (arsenic + Cur), G5 (arsenic + NAC, post treatment) and G6 (arsenic + Cur, post treatment). Post Hoc-Tukey test was applied to compare mean value of parameters between all groups. The mean of MMP2 is not significant between groups with similar symbols (a).

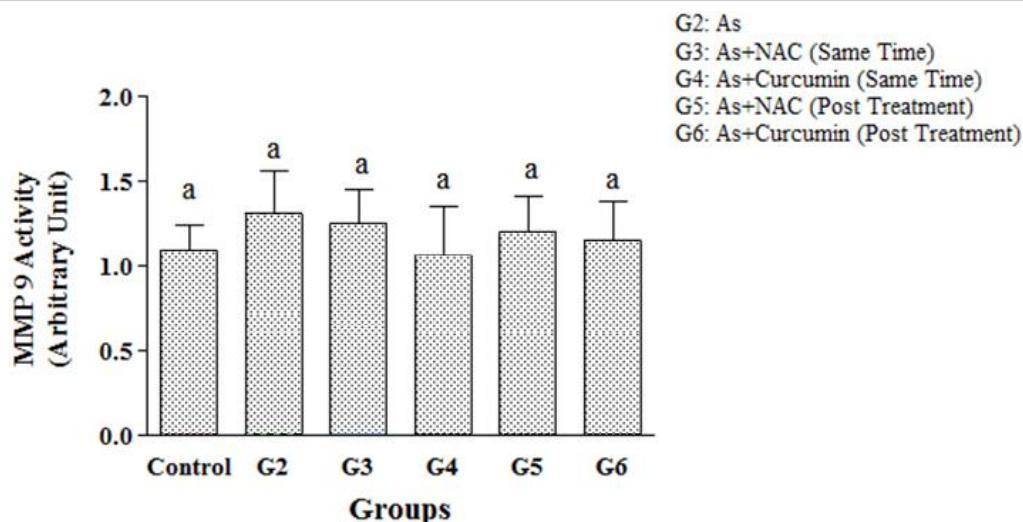


Figure 3. Comparison of the MMP9 mean values between control, G2, G3, G4, G5 and G6 groups. Non-significant difference was observed in the mean level of MMP9 between the groups ($p=0.936$). G2 (arsenic), G3 (arsenic + NAC), G4 (arsenic + Cur), G5 (arsenic + NAC, post treatment) and G6 (arsenic + Cur, post treatment). Post Hoc-Tukey test was applied to compare mean value of parameters between all groups. The mean of MMP9 is not significant between groups with similar symbols (a).

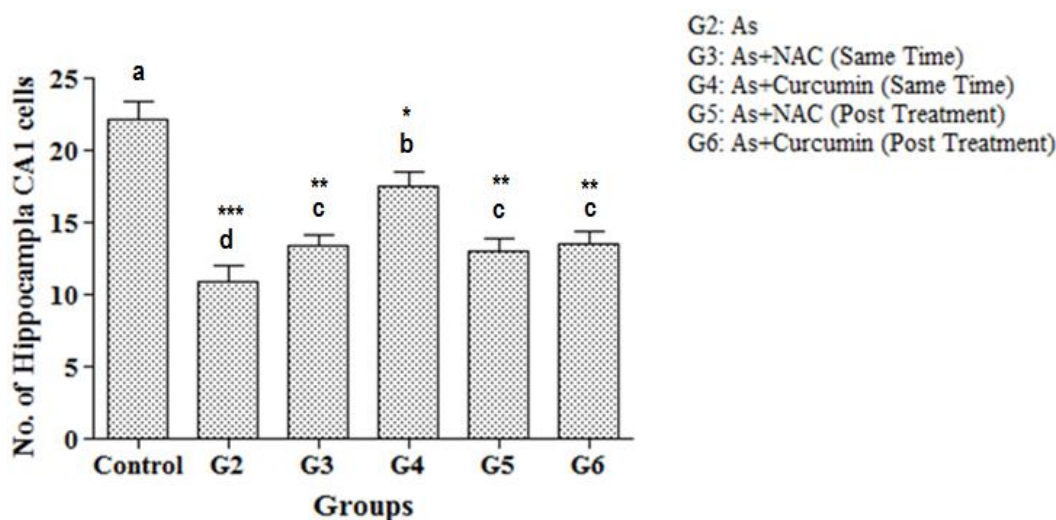


Figure 4. Comparison of the mean number of hippocampal CA1 pyramidal cells between control, G2, G3, G4, G5 and G6 groups. A significant difference was observed in the mean number of the cells between the groups ($p<0.001$). G2 (arsenic), G3 (arsenic + NAC), G4 (arsenic + Cur), G5 (arsenic + NAC, post treatment) and G6 (arsenic + Cur, post treatment). Post Hoc-Tukey test was applied to compare mean value of parameters between all groups. The mean number of hippocampal CA1 pyramidal cells is not significant between groups with similar symbols (a). * $p<0.05$ compared to control. ** $p<0.01$ compared to control; *** $p<0.001$ compared to control.

Results

Comparison of the MMP2 mean values between all groups can be seen in Figure 2. Although non-significant difference was found in the mean value of MMP2 between all groups ($p=0.981$), rats that received arsenic alone showed the highest mean level of MMP2 (1.35 ± 0.29). While rats that post-treated with As + NAC (G3) demonstrated the lowest mean level of MMP2 (1.15 ± 0.16) compared to the other groups. The mean of MMP2 in G2 and G4 groups was increased by 10.7% and 2.4%, respectively, compared to the control group. In contrast, it has been declined by 4.9%, 5.7% and 2.5% in G3, G5, and G4 groups, respectively, when compared to the control group (Figure 2).

Figure 3 shows comparison of the MMP9 mean levels between all groups. There was no significant difference in

the mean of MMP9 level between all groups ($p=0.936$). Nevertheless, rats that received arsenic alone showed a mild increase in mean level of MMP9 (1.31 ± 0.25), while rats that post-treated with As + Curcumin (G4) demonstrated a slight reduction in mean level of MMP9 (1.06 ± 0.2) compared to the other groups. The mean of MMP9 in G2, G3, G5 and G6 groups was increased by 20.2%, 14.7%, 10.1% and 5.5%, respectively, compared to the control group. In contrast, it has been decreased by 2.8% in G4 group compared to the control group (Figure 3).

The mean number of hippocampal CA1 pyramidal cells in all groups is presented in Figure 4. A significant difference was found in the mean number of the cells between all groups ($p<0.001$). The mean number of the hippocampal CA1 pyramidal cells in control group

(22.17 ± 1.17) was significantly higher than that in other groups ($p < 0.01$), while rats that treated with arsenic alone showed significantly the lowest mean cells counts (10.83 ± 1.17) compared to the other groups ($p < 0.05$). Rats that received arsenic and Curcumin at a same time (G4 group), showed the second greatest mean number of the

hippocampal CA1 pyramidal cells (17.5 ± 1.05) compared to the G2, G3 (13.33 ± 0.82), G5 (13.0 ± 0.89) and G6 (13.5 ± 0.84) groups ($p < 0.05$). There was no significant difference in mean of cells counts between G3, G5 and G6 groups (Figure 4).

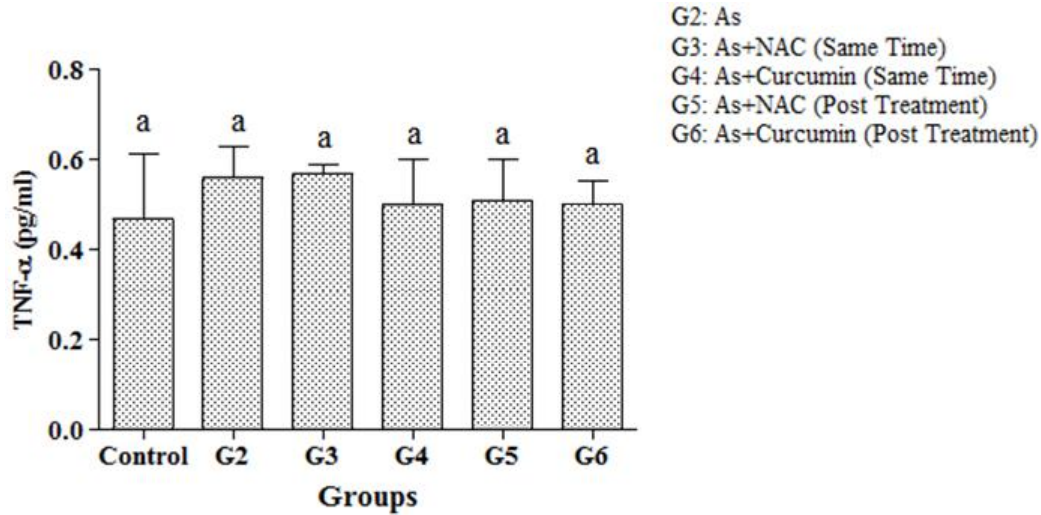


Figure 5. Comparison of the TNF-α mean values between control, G2, G3, G4, G5 and G6 groups. Non-significant difference was observed in the mean level of TNF-α between the groups ($p = 0.399$). G2 (arsenic), G3 (arsenic + NAC), G4 (arsenic + Cur), G5 (arsenic + NAC, post treatment) and G6 (arsenic + Cur, post treatment). Post Hoc-Tukey test was applied to compare mean value of parameters between all groups. The mean of TNF-α is not significant between groups with similar symbols (a).

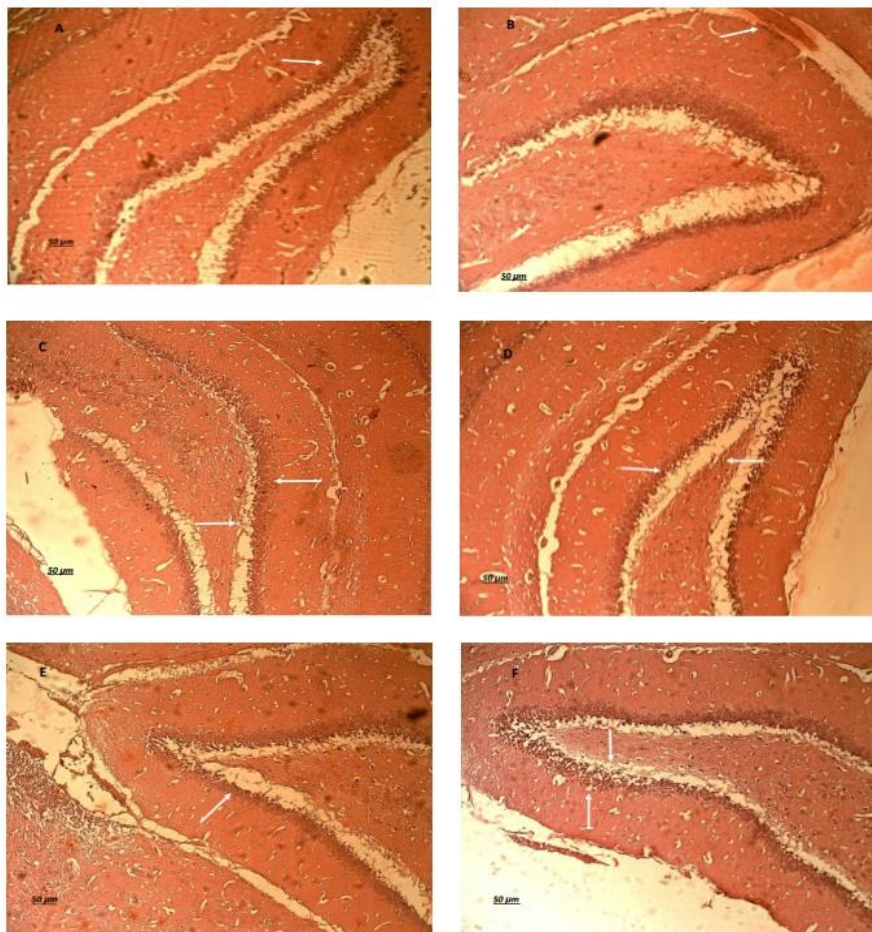


Figure 6. Sections of brain tissue, hippocampal CA1 area, in control (A); G2 (B); G3 (C); G4 (D); G5 (E) and G6 (F) groups.

The mean level of TNF- α in all groups is depicted in Figure 5. A non-significant difference was observed in the mean of TNF- α levels between all groups ($p=0.399$). Rats that received arsenic and NAC at a same time (G3) had slightly higher mean value of TNF- α (0.57 ± 0.02), while rats in the control group showed slightly lower mean level of TNF- α (0.47 ± 0.14) compared to the other groups. The mean of TNF- α level from G2 to G6 groups was increased by 19.1%, 21.3%, 6.4%, 8.5%, and 6.4%, respectively, compared to the control group.

The histopathological and morphological examinations of brain tissue from different groups can be seen in Figure 6. The hippocampal CA1 area from control group (Figure 6A) was normal in structure. Furthermore, normal gray matter and white matter can be seen in hippocampal CA1 area. Severe white matter lesions and cellular damages are detected in the hippocampal CA1 area of rats in G2 (Figure 6B) group. The hippocampal CA1 area of G3 (Figure 6C) and G5 (Figure 6E) groups showed mild lesions in the gray and white matters. An improvement was found in cells morphology and arrangement in G4 (Figure 6D) and G6 (Figure 6F) groups. Additionally, the normal gray and white matters along with neurons were also arranged in normal structure.

Discussion

Inflammation is now considered as one of the significant mechanisms of arsenic toxicity which can be associated with ROS production, oxidative stress, DNA oxidation, lipid peroxidation and cellular damages.³⁰ A growing number of studies have shown that chronic exposure to arsenic enhances inflammatory responses and subsequently oxidative stress by generating ROS.³¹⁻³⁴ For example, maternal exposure to arsenic has been reported to be associated with increased placental contents of inflammatory markers such as 8-oxoguanine (8-oxoG), interleukin-1 β (IL-1 β), TNF- α and interferon-gamma (IFN- γ).³⁵ In another study, arsenic exposure was associated with increased renal inflammation and decreased estimated glomerular filtration rate.³⁴ Ma et al,³⁶ illustrated that arsenic results in oxidative stress and inflammation through induction of NADPH oxidase (NOX) activity and overproduction of nitric oxide (NO). A more recent study has reported that chronic exposure to arsenic is associated with lung inflammation and impaired lung function.³⁷ Arsenic can also accumulate macrophages and neutrophils, as a major source of inflammatory mediators, at the site of tissue injury. Increased macrophage and neutrophil level can subsequently be associated with recruitment and activation of other leukocytes.³⁸ This causes to overproduction of ROS that can overwhelm the antioxidant strategies, leading to oxidative stress.³⁹ Oxidative stress and pro-inflammatory cytokines induced by arsenic impair cellular protein degradation and autophagy, leading to intracellular protein aggregation, reticulum endoplasmic stress and mitochondrial dysfunction.⁴⁰ Arsenic intake via food or water was reported to be associated with elevated serum MMP-9.⁴¹

In another study, Zhnag et al,⁴² indicated that arsenic can down-regulate the expression of VEGF and inhibit the activity of MMP-2 and MMP-9.

Given the fact that arsenic exposure can be associated with antioxidants depletion, inflammatory responses and oxidative stress, antioxidant therapy may be helpful to mitigate its pathological effects. In this study, we compared the protective effect of Cur and NAC on the level of inflammatory factors, MMP-2, MMP-9 and TNF- α , in rats exposed to single dose of arsenic for 30 days. A mild trend was observed toward increased values of serum MMP-2, MMP-9 and TNF- α in rats exposed to arsenic. Additionally, arsenic treatment induced white matter lesions and cellular damages at hippocampal CA1 area of the brain. We also found that arsenic exposure reduced significantly the number of hippocampal CA1 pyramidal cells count compared to untreated rats. These data confirmed that the rats are suffered inflammation after exposure to arsenic. We found that treatment with NAC and Cur declined the level of inflammatory biomarkers. Furthermore, the number of hippocampal CA1 pyramidal cells was improved after treatment with these antioxidants. However, curcumin showed relatively higher protective effect on brain compared to NAC.

These findings suggest that NAC and Cur play an important role in protecting the hippocampal CA1 cells injury induced by arsenic.

Several lines of studies indicated that Cur and NAC have important roles to prevent harmful effects of arsenic on different tissues such as brain, kidney and liver.^{21,43-45} For instance, Srivastava et al,²⁶ demonstrated the neuroprotection of Cur (100mg/kg) against arsenic-induced toxicity in rats. They observed loss of myelin sheath and distorted mitochondria cristae in the both frontal cortex and hippocampus of arsenic exposed (20 mg/kg) rats. Curcumin therapy was found to protect arsenic-induced changes in the mitochondrial membrane potential and activity of mitochondrial complexes both in frontal cortex and hippocampus.²⁶ da Silva et al,¹ reported that coadministration of NAC can ameliorate the harmful effects of arsenic on the male genital system. In another study, Reddy et al,²³ demonstrated that intraperitoneal injection of NAC increase the weights of reproductive organs, reduce arsenic-induced inflammation and improve steroidogenesis in arsenic-exposed mice, suggesting the beneficial role of NAC to counteract arsenic-induced inflammation and to restore the suppressed reproduction in male mice. The anti-apoptotic effect of both Cur and NAC was explained in previous studies,^{46,47} In another research, Cur therapy has been also shown to ameliorate arsenic-induced inflammatory damage in kidney and brain tissues.²² In a previous study, Cur therapy attenuated arsenic-induced chromosomal aberrations, micronuclei formation and DNA damage in rat bone marrow cells.⁴⁸ In another research, hepatoprotective effect of curcumin against arsenic toxicity was considered. For example, Sanker et al,⁴⁹ illustrated that arsenic not only increases lipid peroxidation, GSH depletion and decreased the activities

of SOD, CAT, GPX and glutathione reductase (GSR) in liver, but also it increases the activity of serum alanine aminotransferase (ALT) and aspartate aminotransferase (AST) and causes histological alterations in liver indicating hepatotoxicity. They also showed that all of these abnormalities were attenuated with curcumin treatment (100 mg/kg). These data suggest that Cur can protect different organ against arsenic toxicity by reducing the ROS generation, DNA damage, lipid peroxidation and increasing the level of antioxidant activity.²⁴

Conclusion

In summary, it is concluded that arsenic induces morphological abnormalities in brain such as severe white matter lesions and cellular damages along with significant reduction in the number of hippocampal CA1 cells counts. Furthermore, a trend was found toward increased values of serum MMP-2, MMP-9 and TNF- α in the brain of arsenic exposed rats. However, a limitation of this study is related to oral administration of Cur, which seems to be not an appropriate method for Cur supplementation in the sole water. Therefore, NAC and Cur play an important role in protecting the hippocampal CA1 cells injury induced by arsenic due to their possible anti-inflammatory properties.

Acknowledgments

We would also like to appreciate the staffs of the department of toxicology, Faculty of Pharmacology, Islamic Azad University of Shahre-Reza, Iran.

Conflict of interests

The authors claim that there is no conflict of interest.

References

1. Da Silva RF, Borges CDS, Villela E Silva P, Missassi G, Kiguti LRA, Pupo AS, et al. The Coadministration of N-Acetylcysteine Ameliorates the Effects of Arsenic Trioxide on the Male Mouse Genital System. *Oxid Med Cell Longev*. 2016;2016:1-11. doi:10.1155/2016/4257498
2. Xu Z, Wang Z, Li JJ, Chen C, Zhang PC, Dong L, et al. Protective effects of selenium on oxidative damage and oxidative stress related gene expression in rat liver under chronic poisoning of arsenic. *Food Chem Toxicol*. 2013;58:1-7. doi:10.1016/j.fct.2013.03.048
3. Lin J, Zhu H, Li S, Fan H, Lu X. Complete remission of acute promyelocytic leukemia in a very elderly patient after treatment with low dose arsenic trioxide and sequential retinoic acid: a case report. *Ann Hematol*. 2014;93(2):335-6. doi:10.1007/s00277-013-1791-4
4. Wu HE, Abdel-Gawad NM, Gharbaoui Y, Teixeira AL, Pigott TA. An Unusual Case of Acute Psychosis With Obsessive-Compulsive Features Following Arsenic Poisoning. *J Psychiatr Pract*. 2017;23(5):382-5. doi:10.1097/pr.0000000000000254
5. Sun X, Li J, Zhao H, Wang Y, Liu J, Shao Y, et al. Synergistic effect of copper and arsenic upon oxidative stress, inflammation and autophagy alterations in brain tissues of Gallus gallus. *J Inorg Biochem*. 2018;178:54-62. doi:10.1016/j.jinorgbio.2017.10.006
6. Ratnaike RN. Acute and chronic arsenic toxicity. *Postgrad Med J*. 2003;79(933):391-6. doi:10.1136/pmj.79.933.391
7. Singh AP, Goel RK, Kaur T. Mechanisms pertaining to arsenic toxicity. *Toxicol Int*. 2011;18(2):87-93. doi:10.4103/0971-6580.84258
8. Jomova K, Jenisova Z, Feszterova M, Baros S, Liska J, Hudecova D, et al. Arsenic: toxicity, oxidative stress and human disease. *J Appl Toxicol*. 2011;31(2):95-107. doi:10.1002/jat.1649
9. Fujino Y, Guo X, Liu J, Matthews IP, Shirane K, Wu K, et al. Chronic arsenic exposure and urinary 8-hydroxy-2'-deoxyguanosine in an arsenic-affected area in Inner Mongolia, China. *J Expo Anal Environ Epidemiol*. 2005;15(2):147-52. doi:10.1038/sj.jea.750381
10. Yamauchi H, Aminaka Y, Yoshida K, Sun G, Pi J, Waalkes MP. Evaluation of DNA damage in patients with arsenic poisoning: urinary 8-hydroxydeoxyguanine. *Toxicol Appl Pharmacol*. 2004;198(3):291-6. doi:10.1016/j.taap.2003.10.021
11. Shi H, Hudson LG, Ding W, Wang S, Cooper KL, Liu S, et al. Arsenite causes DNA damage in keratinocytes via generation of hydroxyl radicals. *Chem Res Toxicol*. 2004;17(7):871-8. doi:10.1021/tx049939e
12. Liu SX, Athar M, Lippai I, Waldren C, Hei TK. Induction of oxyradicals by arsenic: implication for mechanism of genotoxicity. *Proc Natl Acad Sci U S A*. 2001;98(4):1643-8. doi:10.1073/pnas.031482998
13. Pi J, Yamauchi H, Kumagai Y, Sun G, Yoshida T, Aikawa H, et al. Evidence for induction of oxidative stress caused by chronic exposure of Chinese residents to arsenic contained in drinking water. *Environ Health Perspect*. 2002;110(4):331-6. doi:10.1289/ehp.02110331
14. Wu MM, Chiou HY, Wang TW, Hsueh YM, Wang IH, Chen CJ, et al. Association of blood arsenic levels with increased reactive oxidants and decreased antioxidant capacity in a human population of northeastern Taiwan. *Environ Health Perspect*. 2001;109(10):1011-7. doi:10.2307/3454955
15. Druwe IL, Sollome JJ, Sanchez-Soria P, Hardwick RN, Camenisch TD, Vaillancourt RR. Arsenite activates NFkappaB through induction of C-reactive protein. *Toxicol Appl Pharmacol*. 2012;261(3):263-70. doi:10.1016/j.taap.2012.04.005
16. Conner EM, Grisham MB. Inflammation, free radicals, and antioxidants. *Nutrition*. 1996;12(4):274-7.
17. Das N, Paul S, Chatterjee D, Banerjee N, Majumder NS, Sarma N, et al. Arsenic exposure through drinking water increases the risk of liver and cardiovascular diseases in the population of West Bengal, India. *BMC*

- Public Health. 2012;12(1):639. doi:10.1186/1471-2458-12-639
18. Kerksick C, Willoughby D. The antioxidant role of glutathione and N-acetyl-cysteine supplements and exercise-induced oxidative stress. *J Int Soc Sports Nutr.* 2005;2(2):38-44. doi:10.1186/1550-2783-2-2-38
 19. Dekhuijzen PN. Antioxidant properties of N-acetylcysteine: their relevance in relation to chronic obstructive pulmonary disease. *Eur Respir J.* 2004;23(4):629-36. doi:10.1183/09031936.04.00016804
 20. Menon VP, Sudheer AR. Antioxidant and anti-inflammatory properties of curcumin. *Adv Exp Med Biol.* 2007;595:105-25. doi:10.1007/978-0-387-46401-5_3
 21. Gao S, Duan X, Wang X, Dong D, Liu D, Li X, et al. Curcumin attenuates arsenic-induced hepatic injuries and oxidative stress in experimental mice through activation of Nrf2 pathway, promotion of arsenic methylation and urinary excretion. *Food Chem Toxicol.* 2013;59:739-47. doi:10.1016/j.fct.2013.07.032
 22. Sankar P, Telang AG, Kalaivanan R, Karunakaran V, Suresh S, Kesavan M. Oral nanoparticulate curcumin combating arsenic-induced oxidative damage in kidney and brain of rats. *Toxicol Ind Health.* 2016;32(3):410-21. doi:10.1177/0748233713498455
 23. Reddy PS, Rani GP, Sainath SB, Meena R, Supriya C. Protective effects of N-acetylcysteine against arsenic-induced oxidative stress and reprotoxicity in male mice. *J Trace Elem Med Biol.* 2011;25(4):247-53. doi:10.1016/j.jtemb.2011.08.145
 24. Biswas J, Sinha D, Mukherjee S, Roy S, Siddiqi M, Roy M. Curcumin protects DNA damage in a chronically arsenic-exposed population of West Bengal. *Hum Exp Toxicol.* 2010;29(6):513-24. doi:10.1177/0960327109359020
 25. Martin DS, Willis SE, Cline DM. N-acetylcysteine in the treatment of human arsenic poisoning. *J Am Board Fam Pract.* 1990;3(4):293-6.
 26. Srivastava P, Yadav RS, Chandravanshi LP, Shukla RK, Dhuriya YK, Chauhan LK, et al. Unraveling the mechanism of neuroprotection of curcumin in arsenic induced cholinergic dysfunctions in rats. *Toxicol Appl Pharmacol.* 2014;279(3):428-40. doi:10.1016/j.taap.2014.06.006
 27. Prasad P, Sinha D. Low-level arsenic causes chronic inflammation and suppresses expression of phagocytic receptors. *Environ Sci Pollut Res Int.* 2017;24(12):11708-21. doi:10.1007/s11356-017-8744-8
 28. Toth M, Fridman R. Assessment of Gelatinases (MMP-2 and MMP-9 by Gelatin Zymography. *Methods Mol Med.* 2001; 57:163-74. doi:10.1385/1-59259-136-1:163
 29. Bradford MM. A rapid and sensitive method for the quantitation of microgram quantities of protein utilizing the principle of protein-dye binding. *Anal Biochem.* 1976;72(1-2):248-54. doi:10.1016/0003-2697(76)90527-3
 30. Bhadauria S, Flora SJ. Response of arsenic-induced oxidative stress, DNA damage, and metal imbalance to combined administration of DMSA and monoisoamyl-DMSA during chronic arsenic poisoning in rats. *Cell Biol Toxicol.* 2007;23(2):91-104. doi:10.1007/s10565-006-0135-8
 31. Prabu SM, Muthumani M. Silibinin ameliorates arsenic induced nephrotoxicity by abrogation of oxidative stress, inflammation and apoptosis in rats. *Mol Biol Rep.* 2012;39(12):11201-16. doi:10.1007/s11033-012-2029-6
 32. Stone OJ, Willis CJ. The effect of arsenic on inflammation. *Arch Environ Health.* 1968;16(6):801-4. doi:10.1080/00039896.1968.10665155
 33. Stone OJ, Willis CJ. The effect of arsenic on inflammation. 1968;16(6):801-4. doi:10.1080/00039896.1968.10665155
 34. Peters BA, Liu X, Hall MN, Ilievski V, Slavkovich V, Siddique AB, et al. Arsenic exposure, inflammation, and renal function in Bangladeshi adults: effect modification by plasma glutathione redox potential. *Free Radic Biol Med.* 2015;85:174-82. doi:10.1016/j.freeradbiomed.2015.04.020
 35. Ahmed S, Mahabbat-e Khoda S, Rekha RS, Gardner RM, Ameer SS, Moore S, et al. Arsenic-associated oxidative stress, inflammation, and immune disruption in human placenta and cord blood. *Environ Health Perspect.* 2011;119(2):258-64. doi:10.1289/ehp.1002086
 36. Ma Y, Ma Z, Yin S, Yan X, Wang J. Arsenic and fluoride induce apoptosis, inflammation and oxidative stress in cultured human umbilical vein endothelial cells. *Chemosphere.* 2017;167:454-61. doi:10.1016/j.chemosphere.2016.10.025
 37. Ahmed S, Akhtar E, Roy A, von Ehrenstein OS, Vahter M, Wagatsuma Y, et al. Arsenic exposure alters lung function and airway inflammation in children: A cohort study in rural Bangladesh. *Environ Int.* 2017;101:108-16. doi:10.1016/j.envint.2017.01.014
 38. Adikwu E, Bokolo B. Prospects of N-acetylcysteine and melatonin as treatments for tramadol-induced renal toxicity in albino rats. *Pharm Sci.* 2017;23(3):172-81. doi:10.15171/ps.2017.26
 39. Intaraphairot T, Chinpaisal C, Apirakaramwong A. Effect of Curcumin on SMCT-1 Expression and Dichloroacetate Toxicity in HCT116 Colon Cancer Cells. *Pharm Sci.* 2017;23(2):112-20. doi:10.15171/ps.2017.17
 40. Escudero-Lourdes C. Toxicity mechanisms of arsenic that are shared with neurodegenerative diseases and cognitive impairment: Role of oxidative stress and inflammatory responses. *Neurotoxicology.* 2016;53:223-35. doi:10.1016/j.neuro.2016.02.002
 41. Kurzius-Spencer M, Harris RB, Hartz V, Roberge J, Hsu CH, O'Rourke MK, et al. Relation of dietary inorganic arsenic to serum matrix metalloproteinase-9

- (MMP-9) at different threshold concentrations of tap water arsenic. *J Expo Sci Environ Epidemiol*. 2016;26(5):445-51. doi:10.1038/jes.2014.92
42. Zhang Y, Zhang JD, Gu J, Ma L, Shen WG, Wang XL, et al. Effect of arsenic trioxide on VEGF/R and MMP-2, 9 expressed in K562 cells. *Zhonghua Xue Ye Xue Za Zhi*. 2007;28(2):107-10.
43. Jahanbazi Jahan-Abad A, Morteza-Zadeh P, Sahab Negah S, Gorji A. Curcumin attenuates harmful effects of arsenic on neural stem/progenitor cells. *Avicenna J Phytomed*. 2017;7(4):376-88.
44. Tiwari H, Rao MV. Curcumin supplementation protects from genotoxic effects of arsenic and fluoride. *Food Chem Toxicol*. 2010;48(5):1234-8. doi:10.1016/j.fct.2010.02.015
45. Yadav RS, Sankhwar ML, Shukla RK, Chandra R, Pant AB, Islam F, et al. Attenuation of arsenic neurotoxicity by curcumin in rats. *Toxicol Appl Pharmacol*. 2009;240(3):367-76. doi:10.1016/j.taap.2009.07.017
46. Han YH, Kim SZ, Kim SH, Park WH. Suppression of arsenic trioxide-induced apoptosis in HeLa cells by N-acetylcysteine. *Mol Cells*. 2008;26(1):18-25.
47. Santra A, Chowdhury A, Ghatak S, Biswas A, Dhali GK. Arsenic induces apoptosis in mouse liver is mitochondria dependent and is abrogated by N-acetylcysteine. *Toxicol Appl Pharmacol*. 2007;220(2):146-55. doi:10.1016/j.taap.2006.12.029
48. Sankar P, Telang AG, Ramya K, Vijayakaran K, Kesavan M, Sarkar SN. Protective action of curcumin and nano-curcumin against arsenic-induced genotoxicity in rats in vivo. *Mol Biol Rep*. 2014;41(11):7413-22. doi:10.1007/s11033-014-3629-0
49. Sankar P, Gopal Telang A, Kalaivanan R, Karunakaran V, Manikam K, Sarkar SN. Effects of nanoparticle-encapsulated curcumin on arsenic-induced liver toxicity in rats. *Environ Toxicol*. 2015;30(6):628-37. doi:10.1002/tox.21940