



## **Determination of Maxillary Incisal Edge Position using Canine Visibility as a Guide – An *In vivo* Study**

**Ankita Piplani <sup>a\*</sup>, G. Ganadhipathi <sup>b<sup>o</sup></sup> and M. C. Suresh Sajjan <sup>c#</sup>**

<sup>a</sup> Department of Prosthodontics, New Horizon Dental College and Resarch Institute, Bilaspur, Chattisgarh, India.

<sup>b</sup> Godavari Dental Care, Amlapuram, Andhra Pradesh, India.

<sup>c</sup> Department of Prosthodontics, Vishnu Dental College, Bhimavaram, Andhra Pradesh, India.

### **Authors' contributions**

*This work was carried out in collaboration among all authors. Author AP, designed the study, performed the statistical analysis, wrote the protocol and wrote the first draft of the manuscript. Author GG managed the analyses of the study as well as managed the literature searches. Author MCSS read and approved the final manuscript. All authors read and approved the final manuscript.*

### **Article Information**

DOI: 10.9734/JPRI/2021/v33i55B33861

### **Open Peer Review History:**

This journal follows the Advanced Open Peer Review policy. Identity of the Reviewers, Editor(s) and additional Reviewers, peer review comments, different versions of the manuscript, comments of the editors, etc are available here: <https://www.sdiarticle5.com/review-history/78330>

**Original Research Article**

**Received 01 October 2021  
Accepted 04 December 2021  
Published 13 December 2021**

## **ABSTRACT**

**Purpose:** To evaluate the reliability of the visibility of the central incisor & the canine for the cervico incisal positioning of anterior maxillary teeth related to age & sex while the upper lip was in repose in dentate patients & the development of rehabilitation recommendations for edentulous individuals with regard to the location of the maxillary incisal edge

**Methodology:** 308 subjects [152 Males & 156 Females] belonging to the age of 30 to 59 years were selected using a simple stratified random technique. There were three age and sex groups: Group I was 30 to 39 years old, Group II was 40 to 49 years old, and Group III was 50 to 59 years old. The vertical distances (in mm) between the lower border of the upper lip and the right maxillary central incisal edge and canine tip were measured and recorded using adhesive tape marked with millimetres. A single examiner recorded all the measurements and the values were tabulated and subjected to statistical analysis.

**Results:** Men in Groups I and II had maxillary central incisor exposure ranging from +6 to -1mm, whereas males in Group III had exposure ranging from +5 to -2mm. There was an exposure range

<sup>≡</sup> Reader;

<sup>o</sup> Consultant Prosthodontist;

<sup>#</sup> Professor, HOD;

\*Corresponding author: E-mail: [ankitapiplani5@gmail.com](mailto:ankitapiplani5@gmail.com);

of +6 to -2 mm in females in Group I, +7 to -2 mm in Group II, and +5 to -2 mm in Group III for the central incisors. While the canine exposure in Group I and II and Group III ranged from +2 to -4mm in females, the exposure ranged from +3 to -3mm in men of all ages. In all groups, females had statistically significant (P<0.05) more central incisor and canine exposure than men.

**Conclusions:** The canine visibility was less variable in all the age groups and in both males and females in comparison to the central incisor. When restoring edentulous individuals, the average canine exposure dimension can be employed for cervico-incisal location of the anterior maxillary teeth.

*Keywords: Incisor visibility; Canine visibility; arrangement of teeth; cervico incisal relation; edentulous.*

## 1. INTRODUCTION

The esthetic zone is composed of the display of anterior teeth by the movement of lips during smile & speech [1]. When a patient has an edentulous maxillary arch, the position of the teeth should be like a dentate individual identical in age, gender, race & facial structure [2,3].

Several writers have used phonetic concepts to determine the placement of the vertical maxillary incisal edge while making maxillary dentures. Premolar and canine tooth location may be determined using phonemes such as 's','z','c','f' & 'v' [4,5]. It is recommended that the occlusal edge of the maxilla extends approximately two millimetres (mm) below the resting lip level [2,3,6]. On evaluation of age-related changes of the dental esthetic zone at rest, the maxillary central incisor exposure range from 0.4 to 7.7mm and canine exposure range from 0.6 to 3.3mm [1]. Carl.E.Misch stated that the range of exposure of the canine is much narrower when compared to that of the incisor. The visibility of central incisor ranges from -1 to +8mm in females & -3 to +8mm in males, whereas the canine visibility range from -2 to +2mm in females & -3 to +2mm in males [7].

The central incisor has shown a wide range of variations in visibility. Hence central incisor visibility solely cannot be used as a reliable guide for establishing the anterior plane and for the arrangement of anterior teeth.

The present study was undertaken to evaluate the reliability of the incisor & the canine visibility for cervico incisal positioning of anterior maxillary teeth related to age & sex while the upper lip is in repose in dentate patients.

## 2. METHODOLOGY

Subjects reported to institute for some dental treatment were considered for the study. Subjects were selected using simple stratified random technique. The patients were explained

about the procedure and informed consent was taken.

A total of 308 subjects [152 Males & 156 Females] within the age range of 30 to 59 years were included in this study. The subjects divided into three groups according to age.

Group 1 :- 30 to 39 years  
Group 2 :- 40 to 49 years  
Group 3 :- 50 to 59 years.

Patients having an average lip length (13 – 25mm) with intact maxillary & mandibular anterior teeth without caries, extreme occlusal wear, restorations and mobility were included in the study.

Patients having a history of orthodontic treatment & plastic surgery to lips were excluded from the study. Subjects were seated in an upright position in a dental chair in a relaxed state with the mandibular posture unstrained.

It was found that, while the lips were at rest, the length of the upper lip measured from the columella's root to its tip, measured using a Vernier scale, measured the midline of the face. Patients having an average lip length (13-25mm) were considered for the study. A millimeter-scale (Camlin, India) was scanned using a digital scanner. The image of a ruler was printed on an adhesive tape. Adhesive tape with millimeter markings thus obtained was used to measure & record the vertical distances in mm.

The labial surfaces of the right maxillary central incisor & right maxillary canine were air-dried & the adhesive tape with the millimeter markings was cut to sufficient length, which included at least three long markings. Each long marking was indicative of 5mm. it was adhered to the labial surface of the index teeth. Right maxillary central incisor incisal edge and right maxillary canine cusp tip corresponded with centimetre line of sticky strip. With the lips parted, patients

were instructed to utter the word "Emma," and measurements were taken in millimetres. They took measures vertically from the lower lip's upper border in repose to the central incisor and right maxillary canine's apex on the right side of the mount. The amount of visible lines between the lower lip's border and the 5mm marking line revealed negative readings, which led to the discovery of the problem. Two measurements were made for each patient & the data was recorded in a proforma. All measurements were recorded & evaluated by a single examiner. A digital camera [Canon-SX 110 power shot] was used to make photographs in addition to the measurement of teeth visibility to correlate the clinical findings with the photographic findings. All the values obtained were tabulated Groupwise and Genderwise and subjected to statistical analysis (SPSS Software). A 0.05 threshold of significance was used for the student t-test to assess the data.

### 3. RESULTS

Comparison of central incisor visibility in mm between males & females in different age groups (Table 1) shows the Subjects in Group I showed an average central incisor exposure of 2.09mm in males & 3.28mm in females. This study found an average of 2.58mm of central incisor enamel exposed in men in Group II and 3.02mm in women in this group. Subjects in Group III

showed an average central incisor exposure of 1.45mm in males & 2.42mm in females. Female subjects displayed a more significant amount of central incisor compared to males in all groups. The difference between Group I and III was large enough to be statistically meaningful. In Group II, there was no statistically significant difference in the visibility of the central incisor between the sexes. As the age advances, the visibility decreases in both males & females.

Comparison of canine visibility in mm between males & females in different age groups (Table 2) shows the Subjects in Group I the average canine exposure of -1.75mm in males & -0.86mm in females. In Group II, the average canine exposure was -1.29mm in males & -1.13mm in females. Subjects in Group III showed an average canine exposure of -1.9mm in males & -1.13mm in females. Females displayed a more significant amount of canine than men in Group I & III. Males and females in Group II did not have any statistically significant differences to be found.

Comparison between the central incisor & the canine visibility in males of different age groups was statistically significant in all groups.

Correlation between the central incisor & the canine visibility in females of different age groups was statistically significant in all groups.

**Table 1. Comparison of central incisor visibility (in mm) between males & females in different age groups**

Group	Male[Incisor]		Female[Incisor]		t - value	P value
	Mean	SD	Mean	SD		
I	2.09	1.97	3.28	0.001	-3.509	0.001 s
II	2.58	1.95	3.02	1.51	-1.331	0.186 ns
III	1.45	1.71	2.42	1.78	-2.327	0.023 s

*Statistically significant if P<0.05*

**Table 2. Comparison of canine visibility (in mm) between males & females in different age groups**

Group	Male[Canine]		Female[Canine]		t -value	P value
	Mean	SD	Mean	SD		
1	-1.75	2.05	-0.86	1.74	-2.523	0.013 s
2	-1.29	1.57	-1.13	1.68	-0.529	0.598 ns
3	-1.9	1.88	-1.13	1.78	-1.902	0.61 Ns

*Statistically significant if P<0.05*

**Table 3. Comparison of the central incisor & the canine visibility (in mm) in males in different age groups**

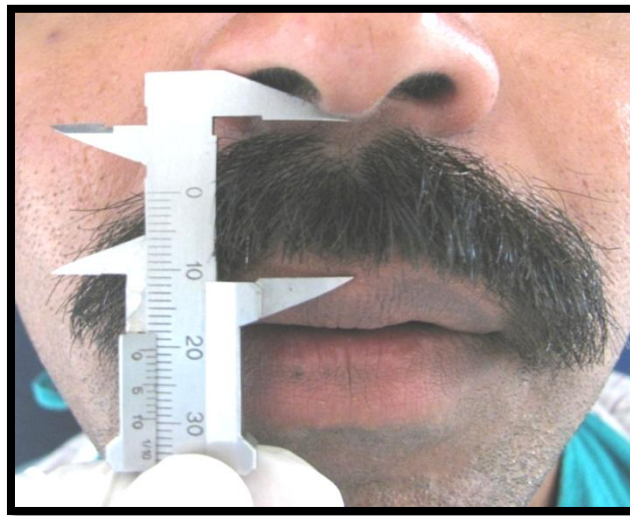
Group	Male[Incisor]		Male[Canine]		t- value	P value
	Mean	SD	Mean	SD		
1	2.09	1.97	-1.75	2.05	17.828	0.000 s
2	2.58	1.95	-1.29	1.57	18.794	0.000 s
3	1.45	1.71	-1.9	1.88	11.709	0.000 s

Statistically significant if  $P < 0.05$

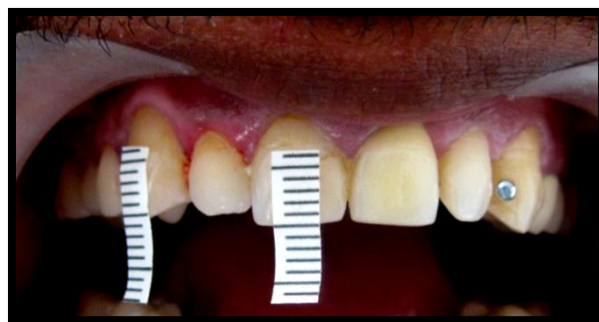**Table 4. Comparison of the central incisor & the canine visibility (in mm) in females in different age groups**

Group	Female [Incisor]		Female[Canine]		t-value	P value
	Mean	SD	Mean	SD		
1	3.28	1.69	-0.86	1.74	21.344	0.000 s
2	3.02	1.51	-1.13	1.68	20.934	0.000 s
3	2.42	1.78	-1.13	1.78	12.781	0.000 s

Statistically significant if  $P < 0.0$



**Fig.1. Measuring lip length with Vernier Caliper**



**Fig. 2. Sticking the adhesive tape with millimeter markings on labial surface of the right central incisor. The centimeter marking line correlated at the level of incisal edge of maxillary central incisor & the tip of maxillary canine**

#### 4. DISCUSSION

Visibility of the teeth is one of the components to make the smile more effective. Four factors influence the vertical position and the amount of maxillary teeth exposure namely Lip length, Age, Race & Sex also known as LARS factors [8]. Exposure of the teeth depends on the position of the teeth in the anterior maxillary segment and the lip. Factors like lip length, lip musculature, tonicity of the lip musculature, length of the lip musculature and inter-commissural distance control the exposure of the teeth. Visibility of the central incisor being at the center of the lip depends on the amount of lip movement apically. The orbicularis oris muscle runs horizontally across the lip and contraction causes the lip to get pulled apically at the midline. Thus expose the central incisor teeth. As the age advances, the tonicity of the muscle also reduces, therefore makes the lip look longer [9]. This is the reason for the reduced visibility of central incisor teeth with age. Hence variability of the central incisor visibility is common [10,11].

Canine is positioned at the corner of the mouth. Canine provides support to the modiolus. Modiolus is an insertion point for eight muscles of facial expression in the lower half of the face. The movement of the corner of the mouth largely depends on the activities of these muscles. The muscles act as a group during a smile and laugh. Since the corner moves in the horizontal direction, the canine visibility shows a smaller variation. This is also the reason for the central incisor to have higher exposure than canine. Considering the consistent position of the commissure, it is also taken as a reference point to establish the occlusal plane [10,11]. There were gender and age differences in the individuals' tooth presentation in this study. The exposure range of the maxillary central incisor in females was +6 to -1 mm in Group I and Group II, and +5 to -2 mm in Group III. Tolerable dog exposure ranges are 2 to 4 millimetres in Groups I and II and 3 to 3 millimetres in Group III (Graph III). A study on men found that in groups I, II, and III, the central-incisor range was between 6 and 2 millimetres; in groups IV, the range was between 5 and 2 millimetres. All age groups had canine exposure ranging from +2 to -4 mm (Graph IV). The central incisor exposure range was found to be larger in males and females in all groups when compared to canine visibility in the same groups. As a result, the quantity of maxillary central incisor exposed when the lip is relaxed varies widely when compared to the

maxillary canine.

Various authors have evaluated the range of exposure of the central incisor & the canine concerning age & sex [2,12,13,14]. The central incisor exposure ranges from 1.16 to 4.16mm in males & 1.02 to 4.80mm in females. The canine exposure ranges from -1.9 to +2.3mm in males & -1.46 to +1.02mm in females while the lips were at rest [15]. These results matched those from the current investigation, which showed a smaller exposure range for dogs' canines than for the central incisor.

Teeth exposure may be more predictable when using smaller averages with a tighter range (3 to 4mm in the canine position) than larger averages (6 to 8mm in the central incisor position) with a broader range. According to this research, between the ages of 30 and 59, the canine tip position was typically anywhere between +1 and -2 millimetres above the level of the top lip in repose. Comparing canine position to central incisor position, less variation was seen with age and gender in the canine position. There was a greater similarity in canine position relative to the upper lip in repose at 35 years of age than at 55 years of age when the central incisor position varied. As people become older, the canine tip becomes more fixed in relation to the upper lip's resting place, but the central incisal edge of the maxilla becomes more mobile. The maxillary incisors had an exposure length of 1 to 2mm greater than the canines when measured along a horizontal plane. Consequently, it is possible to establish the vertical location of the maxillary central incisal edge following determination of the canine tip position. Contradictory findings were observed in previous studies, stated that the maxillary central incisor was an excellent reference than the rest of the anterior teeth concerning the amount of visibility [16,15]. This was due to the canines exhibited higher standard deviations than the means compared to the central incisors [15] & suggested that the assessment of the central incisor position was critical with the upper lip to maintain aesthetics.

The current study found that the maxillary central incisor had a wide range of exposure, and that in actual practise, utilising the average dimension as a guide may not be realistic. The researchers in this study also observed a narrow range in the association between the exposure of the cusp tips of the maxillary canines to the upper lip when they rested on the jaw. Maximum canine size was at the extremes of the range when

compared to all the other factors. A more accurate variable for evaluating the vertical position of anterior maxillary teeth was found in this patient group: canine placement relative to the upper lip. Regardless of age or gender, the distance from the upper lip to the canine of the maxilla was always around 1-2mm. As a result, it was hypothesised that this association may be utilised to predict anterior tooth location in edentulous individuals.

## 5. CONCLUSIONS

There can only be a few inferences based on the data available at this time:

1. The degree of exposure of the maxillary central incisor with the lip in repose varies far more than the maxillary canine in all age groups.
2. During the ages of 30 to 59, the canine tip rests closer to the upper lip than the central incisal margin of the maxilla during chewing.

The exposure range of the maxillary central incisor was bigger than the exposure range of the maxillary canine, indicating that the average canine exposure dimension may be used clinically to establish the central Incisal edge placement when restoring edentulous patients.

## DISCLAIMER

The products used for this research are commonly and predominantly use products in our area of research and country. There is absolutely no conflict of interest between the authors and producers of the products because we do not intend to use these products as an avenue for any litigation but for the advancement of knowledge. Also, the research was not funded by the producing company rather it was funded by personal efforts of the authors.

## CONSENT

As per international standard or university standard, respondents' written consent has been collected and preserved by the author(s).

## ETHICAL APPROVAL

As per international standard or university standard written ethical approval has been collected and preserved by the author(s).

## COMPETING INTERESTS

Authors have declared that no competing interests exist.

## REFERENCES

1. Oscar E. Beder: Esthetics – an enigma. J Prosthet Dent 1971; 25:6:588-91.
2. Pieter Vander geld, Paul Oosterveld, Anne Mare Kuijpers: Age related changes of the dental aesthetic zone at rest and during spontaneous smiling and speech. European Journal of Orthodontics 2008;30:366-73.
3. A.G.L.Payne: Factors influencing the position of artificial upper anterior teeth. J Prosthet dent 1971;26 (1):26-32
4. Boucher CO: Arrangement of teeth. Swenson's complete dentures (ed 10). St.Louis.MO.Mosby. 1995:231-60.
5. Pound E: Esthetic dentures & their phonetic value. J Prosthet Dent 1951;1:98-111
7. Zarb GA, Bolender: Boucher's prosthodontics treatment for edentulous patients.(ed 12).St.Louis.MO.Mosby. 2004:268-320.
8. Vig RG, Brundo GC: The kinetics of anterior tooth display, J Prosthet Dent 1965;67:441-49.
9. Carl E.Misch: Guidelines for Maxillary Incisal edge position- A pilot study: The key is the canine. Journal of Prosthodontics 2008;17:130-34.
10. Barry Hirsh, Bernard Levin, Norman Tiber: Effects of patient involvement & esthetic preference on denture acceptance.J Prosthet Dent 1972;127-32.
11. T.G.Matthews: The anatomy of smile. J Prosthet Dent 1978;30:2.
12. Felix A.frech: The selection & arrangement of the anterior teeth in prosthetic dentures. J Prosthet Dent. 1951:587-93
13. Lawrence A.weinberg: Tooth position in relation to the denture base foundation. J Prosthet Dent 1958: May:398-405.
14. Dayton Dunbar Krajicek: Natural appearance for the individual denture patient. J Prosthet Dent 1960:March-April: 205-214
15. Lucian G.Coble: A complete denture technique for selecting and setting up

- teeth. J Prosthet Dent 1960: May- June:455-58.
16. William S.Jameson:Dynesthetic and Dentogenic concept revisited. J EsthetRestor Dent. 2002;14:139-41.

---

© 2021 Piplani et al.; This is an Open Access article distributed under the terms of the Creative Commons Attribution License (<http://creativecommons.org/licenses/by/4.0>), which permits unrestricted use, distribution, and reproduction in any medium, provided the original work is properly cited.

*Peer-review history:*  
*The peer review history for this paper can be accessed here:*  
<https://www.sdiarticle5.com/review-history/78330>