

Journal of Advanced Pharmacy Research



Section D: Clinical Pharmacy & Pharmacology

Lactoferrin Ameliorates Azithromycin-induced Cardiac Injury: Insight into Oxidative Stress/TLR4 /NF- κ B Pathway

Manar G. Helal¹, Mohamed Shawky², Shady Elhusseiny³, Ahmed G. Abd Elhameed^{1,4*}

¹Department of Pharmacology and Toxicology, Faculty of Pharmacy, Mansoura University, Egypt. ²Department of Biochemistry, Faculty of Pharmacy, Horus University, Egypt. ³Department of Cardiovascular Medicine, Faculty of Medicine, Mansoura University, Egypt. ⁴Department of Pharmacology, Faculty of Pharmacy, Horus University, Egypt.

*Corresponding author: Ahmed G. Abd Elhameed., Department of Pharmacology and Toxicology, Faculty of Pharmacy, Mansoura University, 35516, Mansoura, Egypt. Tel. (+2)01004715654
Email address: Ahmed_gamal_helall@mans.edu.eg

Submitted on: 11-02-2021; Revised on: 05-03-2021; Accepted on: 08-03-2021

To cite this article: Helal, M. G.; Shawky, M.; Elhusseiny, S.; Abd Elhameed, A. G. Lactoferrin Ameliorates Azithromycin-induced Cardiac Injury: Insight into Oxidative Stress/TLR4 /NF- κ B Pathway. *J. Adv. Pharm. Res.* **2021**, 5 (2), 285-296. DOI: [10.21608/aprh.2021.62735.1122](https://doi.org/10.21608/aprh.2021.62735.1122)

ABSTRACT

Introduction: Azithromycin, a widely used antibacterial agent, is also considered the cornerstone of the management protocols for COVID-19 infection, particularly in Egypt, due to its antiviral impact and preventive effects against secondary bacterial infections. However, even at pharmacological doses, azithromycin develops rapid cardiac toxicity. **Objectives:** Our study here aims at investigating the cardioprotective potentials of lactoferrin, a natural compound used primarily for boosting intestinal iron absorption, to counteract azithromycin-induced cardiac toxicity in experimental rats when administered concurrently. **Methods:** Male Sprague Dawley rats received either lactoferrin (200 mg/kg/day, orally) or saline for 10 days. Induction of cardiac toxicity was initiated on the 6th day *via* oral administration of azithromycin (20mg/kg/day, orally) for 5 successive days, concurrently with either lactoferrin or vehicle. Cardiac injuries were confirmed *via* Electrocardiogram (ECG) recording, assessment of cardiac function biomarkers, assessment of cardiac expression of nuclear factor erythroid 2-related factor 2 (Nrf2), interleukin-1 β (IL-1 β) and IL-10, measurement of cardiac oxidant/antioxidant balance, immunohistochemical staining against toll-like receptor-4 (TLR4), and nuclear factor- κ B (NF- κ B), and histopathological examination of HE-stained cardiac specimens. **Results:** Administration of azithromycin denoted a significant cardiac tissue injury as demonstrated by upregulated serum levels of cardiac biomarkers, namely total creatine Kinase (CK), Creatine kinase-MB (CK-MB), lactate dehydrogenase (LDH), and Alkaline phosphatase (ALP). Furthermore, it upregulated cardiac content of malondialdehyde (MDA) and nitric oxide (NO) and cardiac inflammatory markers, such as TLR4, NF- κ B, and IL-1 β . Similarly, azithromycin-downregulated reduced glutathione (GSH) cardiac content and the anti-inflammatory protective indicators, IL-10 and Nrf2. Additionally, azithromycin-induced cardiotoxicity was evinced by ECG pattern and histopathologic deterioration. Oral Lactoferrin showed cardioprotective potentials and counteracted the azithromycin-induced cardiac toxicity, downregulating cardiac biomarkers. Moreover, it restored cardiac oxidant/antioxidant balance, decreased cardiac TLR4, NF- κ B, and IL-1 β expression, and increased IL-10 and Nrf2 expression. Lactoferrin Cardioprotective potentials were also evinced by enhanced ECG pattern and histopathological examination. **Conclusion:** Finally, we support the use of lactoferrin with azithromycin intake that induced cardiac toxicity.

Keywords: Azithromycin; Lactoferrin; NF- κ B; TLR4; IL-10

INTRODUCTION

Macrolides, in particular erythromycin, clarithromycin, azithromycin, and telithromycin, are among the most commonly used antibacterial agents for the treatment of gram-positive bacterial infections such as *Staphylococcus aureus*, *Streptococcus pneumoniae*, and *Streptococcus pyogenes*^{1,2}. Azithromycin, a 2nd - generation macrolide with limited adverse drug reactions (ADRs), is widely used for the treatment of bacterial infections³. Azithromycin exhibited significant *in-vitro* and *in-vivo* antiviral properties against a wide variety of viruses: Ebola, Zika, respiratory syncytial virus, H1N1 influenza, enterovirus, and rhinovirus⁴⁻¹². Recently, azithromycin has been reported to exhibit antiviral effects against SARS-CoV-2 in both *in-vitro*¹³ and clinical settings¹⁴.

Notably, the recent increasing importance of azithromycin has gained attention to the associating ADRs. Several case reports have reported the azithromycin-induced cardiovascular ADRs, where it can cause cardiotoxic impacts, such as torsade de pointes, QT interval prolongation, and ventricular arrhythmias, causing unexpected sudden deaths^{15, 16, 17}. Animal models of azithromycin-associated cardiac injury revealed that azithromycin administration induces oxidative damage, inflammatory mediators upregulation, myocardial tissue injury, and, ultimately, apoptosis. These devastating impacts of azithromycin are evident by ECG changes, myocardial infarction, and death^{18, 19}. Moreover, azithromycin and other antibiotics disrupt the intestinal microbiota and may develop intestinal dysbiosis in elderly patients with gut microbiota changes, making them susceptible to heart failure. Therefore, probiotics, particularly lactoferrin, could be recommended for administration to counteract these changes¹⁵.

Lactoferrin, a naturally occurring non-toxic glycoprotein, is commercially available as an oral nutritional supplement²⁰. Lactoferrin is pivotal in both natural and acquired immunities. Several studies have reported that lactoferrin can exhibit antiviral, antimicrobial, anti-inflammatory, antioxidant, renoprotective, and hepatoprotective therapeutic potentials^{20, 21, 22, 23, 24}. These studies suggest that lactoferrin may impart cardioprotective potentials against cardiotoxins. Indeed, a recent study has reported that Lactoferrin counteracts nicotine-induced cardiac damage in a rat model²⁰.

Consequently, the current experimental work aimed to evaluate the possible cardioprotective potentials of lactoferrin against azithromycin-induced cardiotoxicity in rats. Azithromycin-induced cardiac toxicity was confirmed through ECG recording, assessing serum levels of cardiac function biomarkers, namely LDH, CK-MB, total CK, and ALP,

histopathological examination of cardiac tissues, and determination of cardiac oxidant/antioxidant balance. Besides, azithromycin-induced inflammatory conditions were monitored *via* immunohistochemical detection of TLR4, NF- κ B, IL-1 β , IL-10, and Nrf2 in cardiac tissues.

MATERIALS AND METHODS

Drugs and Chemicals

Azithromycin was obtained as *Zithromax*® 250 mg capsules, *Pfizer*® Pharmaceutical Company Inc. (Egypt). Lactoferrin was obtained as *Pravotin*® 100 mg sachets, *Hygint* Pharmaceuticals Ltd., (Egypt). Azithromycin was suspended in fresh carboxymethylcellulose (CMC) 0.5 % W/V solution, while lactoferrin was dissolved in 0.9% saline solution. All used chemicals were of analytical grades.

Animals

As part of the current investigation, eighteen male SD albino rats, each weighing 180 \pm 40 g, were used, as given by the Egyptian Organization for Biologicals and Antibodies (Cairo, Egypt). Rats have been housed in well-ventilated plastic cages under stable, standardized conditions with a 12 h light/dark period. Rats have been granted free access to standard feeding chow (El-Nasr Pharmaceuticals and Chemicals, Egypt) and water, *ad libitum*, and a one-week acclimatization period prior to initiating the experimental design. All animal experiments in the current study were conducted according to the guidelines approved by Research Ethics Committee of Mansoura university (No. 5335), which, in turn, tracked the National Institutes of Health (NIH) guidance for the care and use of laboratory animals (NIH Publications No. 8023, revised in 1978).

Experimental design

Following acclimatization, rats were indiscriminately divided into 3 groups: control, azithromycin, and lactoferrin\azithromycin groups, each of 6 rats. Rats in control, azithromycin, and lactoferrin\azithromycin groups received either saline (1 ml/kg/day, orally), saline (1 ml/kg/day, orally), or lactoferrin (200 mg/kg/day, orally)²⁵, respectively, for 10 successive days. On day 6, rats in azithromycin and lactoferrin\azithromycin groups were subjected to induction of cardiotoxicity through oral administration of azithromycin (20 mg/kg/day)^{18, 19}, while rats in the control group received CMC solution (1 ml/Kg/day, orally) for 5 successive days. At the end of the experiment, rats were fasted for 12 h and anesthetized with urethane (1.5 g/kg, intraperitoneal)²⁶.

ECG recording

A single-channel 501-B III ECG (Fukuda ME Kogyo Co. Ltd., Tokyo, Japan) was used for ECG

Table 1. Effect of lactoferrin on the azithromycin-induced elevation of cardiac function biomarkers: Total Ck, CK-MB, LDH, and ALP

	Control	Azithromycin	Lactoferrin\azithromycin
Total CK (U/L)	681.20 ± 59.78	1313.00 ± 50.99 [§]	818.20 ± 49.70 [#]
CK-MB (U/L)	305.30 ± 31.50	693.00 ± 49.76 [§]	365.40 ± 28.33 [#]
LDH (U/L)	1384.00 ± 83.25	4979.00 ± 534.70 [§]	2115.00 ± 161.80 [#]
ALP (U/L)	401.20 ± 13.08	770.20 ± 46.84 [§]	402.80 ± 25.71 [#]

Lactoferrin\azithromycin group received lactoferrin (200 mg/kg/day, orally) starting from day 1 till day 10. Cardiotoxicity was induced in azithromycin and lactoferrin\azithromycin groups through oral administration of azithromycin (20 mg/kg/day) for 5 successive days, starting from day 6 till day 10. Data are presented as mean ± SEM, n=6. Statistical analysis was done using (ANOVA) followed by Tukey-Kramer test
^{§, #} p<0.05, Significantly different Vs. either control or azithromycin groups, respectively.

Table 2. Effect of lactoferrin on azithromycin-induced alteration in cardiac oxidative stress and antioxidant levels

	Control group	Azithromycin group	Lactoferrin\azithromycin group
MDA (nmol/g tissue)	3.99 ± 0.39	8.20 ± 0.26 [§]	5.04 ± 0.42 [#]
NO (nmol/g tissue)	9.70 ± 1.05	35.51 ± 3.32 [§]	14.91 ± 0.92 [#]
GSH (µmol/g tissue)	2.34 ± 0.10	1.22 ± 0.07 [§]	2.24 ± 0.11 [#]

Lactoferrin\azithromycin group received lactoferrin (200 mg/kg/day, orally), starting from day 1 till day 10. Cardiotoxicity was induced in azithromycin and lactoferrin\azithromycin groups through oral administration of azithromycin (20 mg/kg/day) for 5 successive days, starting from day 6 till day 10. Data are presented as mean ± SEM, n=6. Statistical analysis was done using (ANOVA) followed by Tukey-Kramer test
^{§, #} p<0.05, Significantly different Vs. either control or azithromycin groups, respectively.

recordings, using standard lead II limb leads. The electrocardiographs were standardized and utilized to determine ECG patterns and changes as previously described^{19, 27}.

Blood sampling and tissue collection

Blood samples have been directly obtained, following ECG recording, *via* retro-orbital plexus puncture and centrifuged for serum separation. Freshly prepared sera were utilized for assessment of cardiac function biomarkers, total CK, CK-MB, LDH, and ALP. Afterwards, rats were sacrificed, and hearts were excised. Hearts were flushed with traditional cold saline and dried by filter paper. The apical part was preserved for histological evaluation and immunohistochemical staining against NF-κB and TLR4. The remaining cardiac tissues were cut into several specimens, immediately frozen in liquid nitrogen (-170°C), and then frozen at -80°C to evaluate MDA, GSH, NO, IL-1β, IL-10 in addition to Nrf2.

Biochemical methods

Serum CK-MB and CK levels were assessed using commercial kits provided by Biomed (Badr City, Egypt) and ELiTech clinical systems (Egypt), respectively. Serum LDH and ALP were determined

using commercial Spinreact[®] assay kits (Girona, Spain). Cardiac MDA, GSH, and NO content have been made calorimetrically using Bio-Diagnostics Kits (Bio-diagnostics Co. Giza, Egypt). Additionally, IL-1β, IL-10, and Nrf2 were measured by ELISA kits *via* BioLegend, Inc., (San Diego, CA, USA), Invitrogen (Vienna, Austria), and abcam[®] (USA), respectively. All biochemical methods were conducted according to manufacturers' instructions.

Hematoxylin and Eosin (HE) and Immunohistochemical Staining

Apical portions of cardiac tissues have been fixed in paraffin and stained with HE to detect cardiac tissue histopathology. Furthermore, the immunodetection of TLR4 and NF-κB expression has been conducted. Briefly, slides have been incubated with the primary antibody either Anti NF-κB antibody (Cat No. YP0191), purchased from ImmunoWay Biotechnology Company (Plano, TX, USA) or anti-TLR4 antibody (Cat No. SAB35463), purchased from SAB (College Park, Maryland, USA) at 4 °C overnight. Then, slides were washed, incubated with the second HRP-polymer conjugated anti-rabbit IgG antibody (Maixin, Fujian, China), followed by the DAB kit (Maixin) reaction, and finally, counterstained with

Table 3. Effect of lactoferrin on azithromycin-induced ECG pattern changes and deteriorations

	Control group	Azithromycin group	Lactoferrin\azithromycin group
Heart Rate (BPM)	181 ± 6.8	157.5 ± 3.9 [§]	194.70 ± 7.56 [#]
PR interval (Sec.)	0.082 ± 0.002	0.193 ± 0.041 [§]	0.077 ± 0.003 [#]
RR interval (Sec.)	0.310 ± 0.005	0.38 ± 0.016 [§]	0.316 ± 0.010 [#]
QRS interval (Sec.)	0.03 ± 0.002	0.048 ± 0.006 [§]	0.031 ± 0.003 [#]
QT interval (Sec.)	0.126 ± 0.002	0.145 ± 0.005 [§]	0.118 ± 0.004 [#]
QTc interval (Sec.)	0.230 ± 0.015	0.346 ± 0.058	0.211 ± 0.007 [#]
T peak-T end interval (Sec.)	0.075 ± 0.003	0.085 ± 0.005	0.055 ± 0.003 ^{§#}
ST height (mV)	0.196 ± 0.062	0.150 ± 0.020	-0.056 ± 0.054 [§]
P (mV)	0.147 ± 0.016	0.034 ± 0.025 [§]	0.108 ± 0.009 [#]
R (mV)	0.780 ± 0.128	0.77 ± 0.094	0.428 ± 0.042 ^{§#}
S (mV)	-0.130 ± 0.030	-0.13 ± 0.025	-0.283 ± 0.060
T (mV)	0.27 ± 0.034	0.29 ± 0.024	0.226 ± 0.037

Lactoferrin\azithromycin group received lactoferrin (200 mg/kg/day, orally), starting from day 1 till day 10. Cardiotoxicity was induced in azithromycin and lactoferrin\azithromycin groups through oral administration of azithromycin (20 mg/kg/day) for 5 successive days, starting from day 6 till day 10. Data are presented as mean ± SEM, n=6. Statistical analysis was done using (ANOVA) followed by Tukey-Kramer test ^{§, #} p<0.05, Significantly different Vs. either control or azithromycin groups, respectively.

Hematoxylin. All cardiac sections were examined by LEICA® light microscope (Wetzlar, Germany) at 400x magnification, and sections were chosen to analyze the expression of these proteins. Using the Motic 6.0 image analysis method (Xiamen, China), the positive rates were analyzed semi-quantitatively.

Statistical analysis

Statistics have been carried out by GraphPad Prism 8, CA, USA. Results have been presented as mean ± SEM, and parametric differences have been rendered by One-Way variance analysis (ANOVA test) followed by Tukey-Kramer test, p < 0.05 as a confidence interval. Also, Kruskal Wallis followed by post hoc Dunn's multiple comparison tests have been used for statistical analysis of non-parametric data.

RESULTS

Effect of lactoferrin on cardiac function biomarkers

Azithromycin group showed cardiac injury that is denoted with the significant rise in total CK and ALP by 92.7 % and 92%, respectively, in addition to a significant increase in CK-MB and LDH by 2.3- and 3.6-fold, respectively, compared with control group. In contrast, lactoferrin\azithromycin group showed a significant decrease in total CK, CK-MB, LDH, and ALP by 37.7 %, 47%, 58%, and 48%, respectively, compared with azithromycin group (Table 1).

Effect of lactoferrin on cardiac oxidative stress and antioxidant levels

Azithromycin administration showed a significant upregulation of cardiac MDA and NO contents by 2- and 3.7- fold, respectively, and downregulation of cardiac GSH content by 1.9-fold compared with control group. Oral lactoferrin denoted a significant alleviation of the increased cardiac MDA and NO contents by 39% and 58%, respectively, and replenished GSH store in cardiac tissues by 1.8-fold compared with azithromycin group (Table 2).

Effect of lactoferrin on azithromycin-induced ECG pattern changes and deteriorations

Treatment of rats with azithromycin significantly decreased heart rate and P wave amplitude (mV) by 13% and 77%, respectively, and significantly increased PR interval, RR interval, QRS interval, and QT interval by 2.4-fold, 23%, 60%, and 15%, respectively, compared with control group. Also, azithromycin administration prolongs QTc interval and T-T interval and decreased ST height compared with control group, but these changes did not reach significant levels (Table 3 and Figure 1(A-C)).

Regarding lactoferrin\azithromycin group, treatment with lactoferrin reversed most of the azithromycin-induced deteriorations in ECG patterns. Lactoferrin significantly increased heart rate and P wave

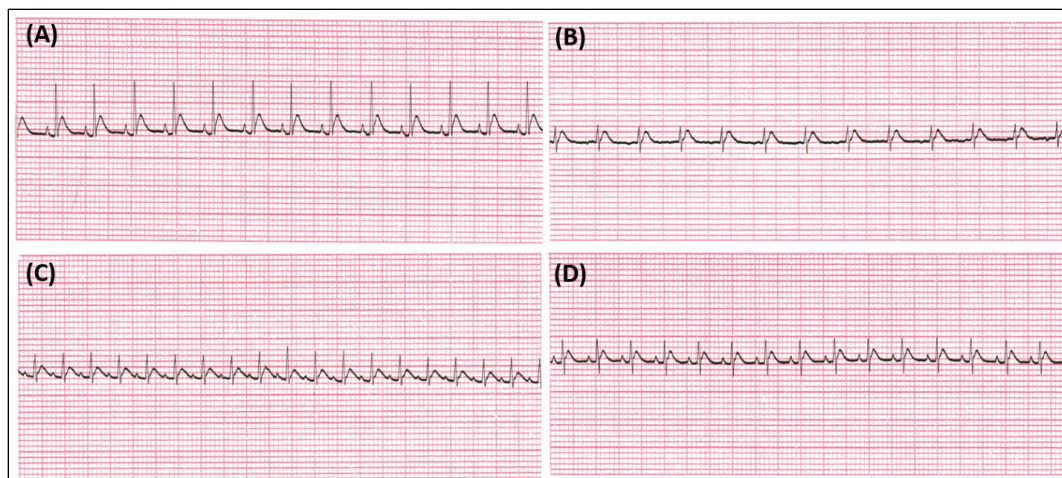


Figure 1. Effect of lactoferrin on the azithromycin-induced deterioration of ECG pattern from control rats (A), azithromycin administered rats (B&C), and rats received azithromycin and lactoferrin (D). Lactoferrin/azithromycin group received lactoferrin (200 mg/kg/day, orally), starting from day 1 till day 10. Cardiotoxicity was induced in azithromycin and lactoferrin/azithromycin groups through oral administration of azithromycin (20 mg/kg/day) for 5 successive days, starting from day 6 till day 10. Data are presented as mean \pm SEM, n=6. Statistical analysis was done using (ANOVA) followed by Tukey-Kramer test. \$, # $p < 0.05$, Significantly different Vs. either *control or azithromycin groups*, respectively.

amplitude (mV) by 24% and 3.2-fold, respectively, compared with azithromycin group. It significantly decreased PR interval, RR interval, QRS interval, QT interval, QTc interval, T-T interval, and R wave amplitude (mV) by 60%, 17%, 35%, 19%, 39%, 35%, and 44%, respectively, all in comparison with azithromycin group. In contrast, there was no significant difference between lactoferrin/azithromycin and control groups regarding most ECG parameters, except T peak-T end interval, ST height, and R wave amplitude, which significantly decreased in lactoferrin/azithromycin group compared with control group (Table 3 and Figure 1D).

Effect of lactoferrin on immunostaining against TLR4 and NF- κ B

Immunohistochemical detection of TLR4 and NF- κ B have shown a significant elevation of the positive area percentage by 4.8- and 4.9-fold, respectively, in azithromycin group compared with control group. In contrast, lactoferrin/azithromycin group showed a significant decrease in the positive area percentage by 66% and 64.8%, respectively, compared with azithromycin group (Figures 2 and 3).

Effect of lactoferrin on inflammatory and anti-inflammatory parameters

As denoted in Figure 4A, oral azithromycin showed a significantly upregulated expression of IL-1 β by 3.25-fold in the cardiac dysfunction group compared with the control. Lactoferrin administration showed significant downregulation of IL-1 β expression by 50%

in lactoferrin/azithromycin group compared with azithromycin group.

In context, in Figures 4B and 4C, denoting levels of anti-inflammatory markers IL-10 and Nrf2, azithromycin group showed a significant decrease in their levels by 63.2% and 65%, respectively, compared with control group. In contrast, the lactoferrin/azithromycin group showed a significant increase in the levels of IL-10 and Nrf2 by 75% and 2.6-fold, respectively, compared with azithromycin one.

Histopathological examination

Photomicrographs of HE-stained cardiac sections are represented in Figure 5. The HE-stained cardiac section of control group shows normal cardiomyocytes and interstitial tissue (Figure 5A). Cardiac photomicrographs from azithromycin group show congestion (red arrows), interstitial and perivascular infiltration of mononuclear cells (yellow arrows), interstitial (black asterisks) and perivascular edema (red asterisks), and necrotic cardiomyocytes (black arrows) (Figure 5(B-G)). Cardiac sections from lactoferrin/azithromycin group show mild congestion (red arrows) and interstitial edema (black asterisks) (Figure 5(H and I)).

DISCUSSION

Azithromycin is typically used to treat bacterial infections and is considered a cornerstone medication in Egyptian protocols for the management of COVID-19. Azithromycin has been demonstrated to be effective

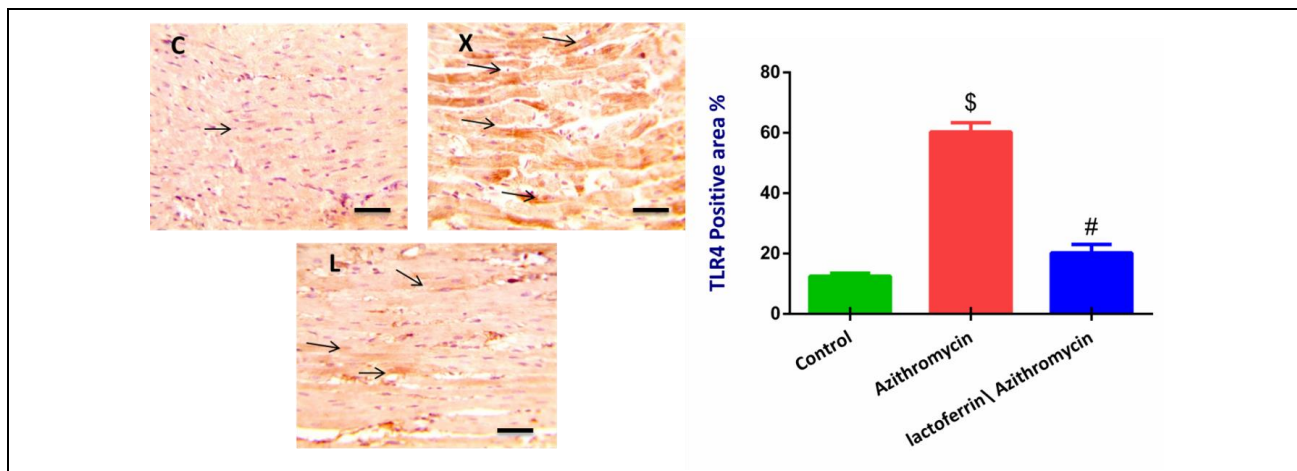


Figure 2. Effect of lactoferrin on the azithromycin-induced changes in TLR4 immunohistochemical-detection: photomicrographs show TLR4 expression in control group (C), azithromycin group (X), and lactoferrin\azithromycin group (L), magnification X= 400, bar=50. The Bar-chart represents the percentage of TLR4 expression positive area. Lactoferrin\azithromycin group received lactoferrin (200 mg/kg/day, orally), starting from day 1 till day 10. Cardiotoxicity was induced in azithromycin and lactoferrin\azithromycin groups through oral administration of azithromycin (20 mg/kg/day) for 5 successive days, starting from day 6 till day 10. Results are presented as mean \pm SEM, n=6. Statistical analysis was done using Kruskal Wallis followed by post *hoc* Dunn's test. \$, # $p < 0.05$, Significantly different Vs. either *control or azithromycin groups*, respectively.

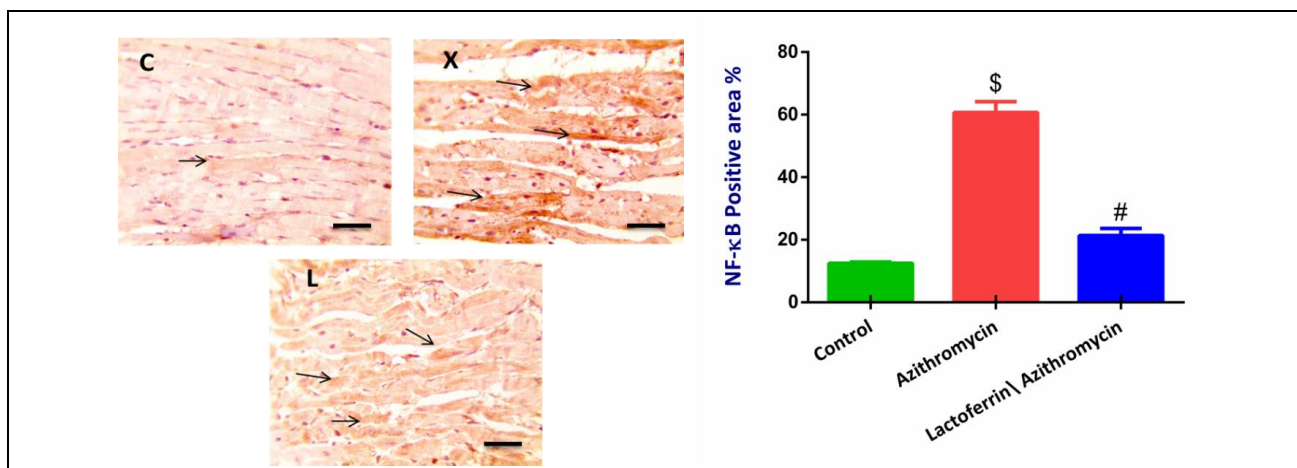


Figure 3. Effect of lactoferrin on the azithromycin-induced changes in NF-κB immunohistochemical-detection: photomicrographs show the NF-κB expression in control group (C), azithromycin group (X), and lactoferrin\azithromycin group (L), magnification X= 400, bar=50. The Bar-chart represents the percentage of NF-κB expression positive area. Lactoferrin\azithromycin group received lactoferrin (200 mg/kg/day, orally), starting from day 1 till day 10. Cardiotoxicity was induced in azithromycin and lactoferrin\azithromycin groups through oral administration of azithromycin (20 mg/kg/day) for 5 successive days, starting from day 6 till day 10. Results are presented as mean \pm SEM, n=6. Statistical analysis was done using Kruskal Wallis followed by post *hoc* Dunn's test. \$, # $p < 0.05$, Significantly different Vs. either *control or azithromycin groups*, respectively.

in-vitro against the Zika and Ebola viruses^{5, 14, 28, 29} and prevent severe viral respiratory tract infections^{14, 30}. However, the azithromycin-induced ADRs represent a serious milestone against the safe use of azithromycin. These ADRs have been studied on a pharmacological dose in our study. Pathological cardiac alterations were

especially desirable in our 20 mg/kg azithromycin-administered sample.

Many natural compounds have been reported to possess anti-inflammatory impacts and can directly protect against inflammatory tissue damage³¹. Lactoferrin, a multifunctional natural protein found in

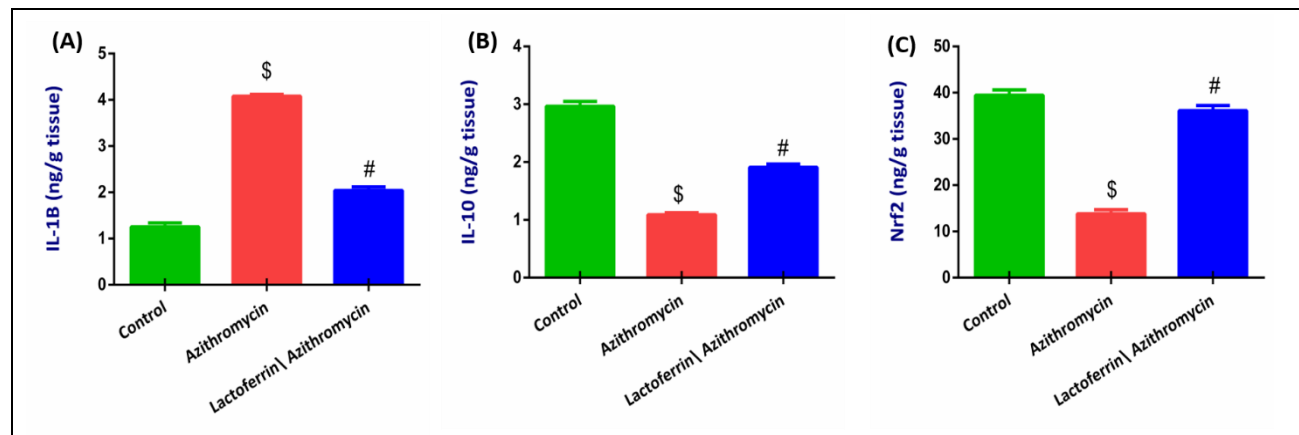


Figure 4. Effect of lactoferrin on the azithromycin-induced alteration of Cardiac IL-1 β levels(A), Cardiac IL-10 levels (B), and Cardiac Nrf2 levels(C). Lactoferrin\azithromycin group received lactoferrin (200 mg/kg/day, orally), starting from day 1 till day 10. Cardiotoxicity was induced in azithromycin and lactoferrin\azithromycin groups through oral administration of azithromycin (20 mg/kg/day) for 5 successive days, starting from day 6 till day 10. Results are presented as mean \pm SEM, n=6. Statistical analysis was done using (ANOVA) followed by Tukey-Kramer test. \$, # $p < 0.05$, Significantly different Vs. either *control or azithromycin groups*, respectively.

milk, tears, saliva, pancreatic juice, and gall, exhibited anti-inflammatory, immunomodulatory, antioxidant³², renoprotective, and hepatoprotective therapeutic activities^{24, 33, 34}, suggesting cardioprotective potentials against cardiac toxins, and particularly azithromycin. The current research aimed at the investigation of the hypothesized cardioprotective potential of lactoferrin against azithromycin-associated cardiovascular ADRs.

In the current study, the serum levels of cardiac function biomarkers, namely total CK, CK-MB, LDH, and ALP, were assessed. Higher serum levels of these cardiac biomarkers give evidence for their release into the circulation from the damaged myocardium and, consequently, myocardial injury^{35, 36}. Our results have demonstrated that oral administration of azithromycin showed a significant rise in total CK and CK-MB levels and a considerable increase in LDH and ALP levels in our azithromycin group. These results may be considered proof of the azithromycin-induced acute myocardial damage. Oral administration of lactoferrin with azithromycin protected rats, in lactoferrin\azithromycin group, against azithromycin-induced myocardial injury. The lactoferrin cardioprotective effect is evinced by alleviating serum levels of total CK, CK-MB, LDH, and ALP in the lactoferrin\azithromycin group. In agreement with our results, previous studies have reported cardioprotective effects of lactoferrin against either nicotine-induced cardiotoxicity or myocardial ischemia/reperfusion injury in rat models through normalization of elevated serum levels of CK, CK-MB, ALP, and LDH^{20, 37}.

Similarly, the azithromycin-induced cardiac injury was evidenced *via* ECG recording. In our study,

the orally administered azithromycin can be regarded as a consequence of arrhythmogenic effects due to the widely-known cardiac tissue distribution of azithromycin³⁸. ECG in azithromycin-treated rats revealed decreased heart rate and P wave amplitude, significantly increased PR interval, RR interval, QRS interval, and QT interval relative to the control group. Our research results have shown the development of bradycardia in rats treated with azithromycin, and these results were supported by the previous case reports^{39, 40}.

The PR, QRS, and QT periods were determined to be prolonged in azithromycin-administered rats compared to control rats. The ECG PR interval can essentially be extended because the atrionic node is delayed, and the atrium, bundle, branches, and Purkinje fibers are delayed to conduct the ARI⁴¹. The duration of the QT interval in the ECG is considered an important predictor of cardiotoxic impacts of medications⁴². This extend also entails the possibility of polymorphic ventricular tachycardia or Torsades de pointes^{43, 44}. The QT interval prolongation can be explained by the azithromycin-induced inhibition of the cardiac potassium channels and bradycardic disorder found in azithromycin-administered rats^{15, 45, 46}. In context, QRS complex anomaly is a crucial predictor for intranodal conduction anomalies, myocardial ischemia, and myocardial infarction⁴⁷.

On the contrary, concurrent administration of lactoferrin with azithromycin has reversed most of the azithromycin-induced deteriorations in ECG patterns. Lactoferrin intake significantly increased heart rate and P wave amplitude and significantly decreased PR interval, RR interval, QRS interval, QT interval, QTc

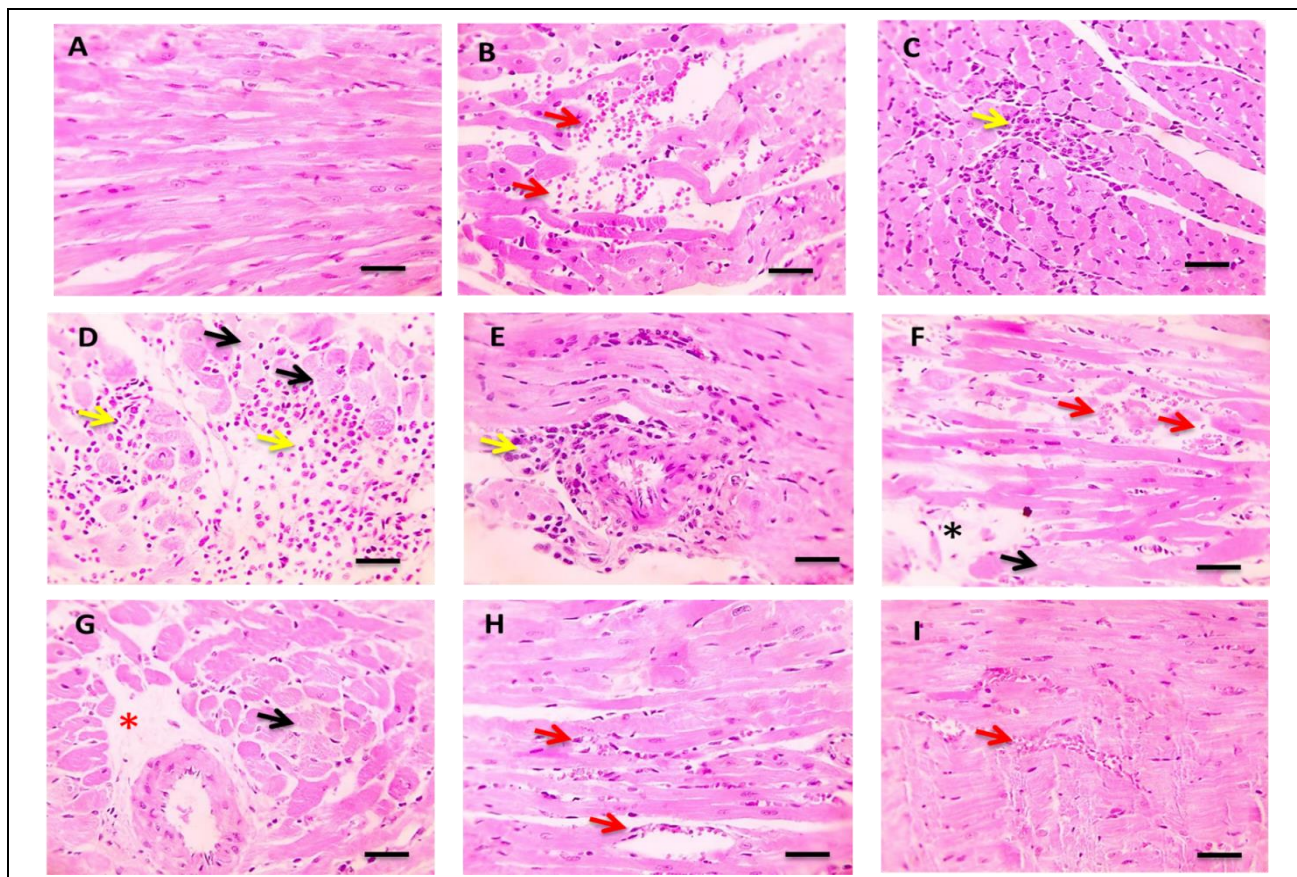


Figure 5. Effect of lactoferrin on the azithromycin-induced alterations in HE-stained cardiac sections: Microscopic photomicrograph shows normal cardiomyocytes and interstitial tissue in control group (A). Cardiac sections from azithromycin group showing congestion (red arrows), interstitial and perivascular infiltration of mononuclear cells (yellow arrows), interstitial (black asterisks), and perivascular edema (red asterisks), necrotic cardiomyocytes (black arrows)(B-G). Cardiac sections from lactoferrin\azithromycin group showing mild congestion (red arrows) and interstitial edema (black asterisks)(H-I), magnification X= 400, bar=50. Lactoferrin\azithromycin group received lactoferrin (200 mg/kg/day, orally), starting from day 1 till day 10. Cardiotoxicity was induced in azithromycin and lactoferrin\azithromycin groups through oral administration of azithromycin (20 mg/kg/day) for 5 successive days, starting from day 6 till day 10.

interval, T-T interval, and R wave amplitude compared with azithromycin group. In contrast, there was no significant difference between lactoferrin\azithromycin group and the control one regarding most ECG parameters, except for T peak- T end interval, ST height, and R wave amplitude, which are significantly decreased in lactoferrin\azithromycin group, implying its potential cardioprotective impacts.

Azithromycin-induced oxidative stress, alongside the attenuated antioxidant defenses, could result in oxidative damage to cellular lipids, proteins, and DNA^{27, 48}. Our findings showed that azithromycin-induced cardiac complications are accompanied by induction of oxidative stress in the cardiac tissue as revealed by upregulated cardiac contents of MDA and NO as well as downregulated cardiac GSH content.

On the other hand, oral administration of lactoferrin exhibited a potential to counter verse azithromycin-associated oxidative burst, as denoted by downregulation of the oxidative stress status, decreased cardiac MDA and NO contents, and upregulation of cardiac content of GSH, upon concurrent oral administration with azithromycin in lactoferrin\azithromycin group rats. Similarly, Gulmez *et al.* and Kruzel *et al.* have reported that lactoferrin could control the oxidative burst and has a protective effect against NO in a rat model of endotoxemia^{49, 50}, giving credence to our results. Moreover, our findings support the previous reports of Cohen *et al.* and Hsu *et al.*, who have reported that the antioxidant potential of lactoferrin is a pivotal physiological function of such glycoprotein^{51, 52}.

In the same context, azithromycin-induced oxidative stress has been reported to induce a detected upregulated expression of TLR4. Activation of TLR4 upregulates cardiac expression of NF- κ B, a nuclear factor implicated in inflammatory process activation and attenuation of anti-inflammatory defenses^{48, 53}. NF- κ B pathways have been reported to be engaged in the progression of pathological cardiac conditions, such as hypertension, heart failure, and myocardial hypertrophy⁵⁴. In our study, azithromycin administration to rats activated the pro-inflammatory and inflammatory responses as a consequence of upregulated expression of TLR4 and NF- κ B in cardiac tissues. Azithromycin-induced inflammatory responses are evident *via* upregulated cardiac IL-1 β expression. Moreover, azithromycin suppressed the anti-inflammatory defense within cardiac tissues, as revealed by downregulated cardiac expression of IL-10 and Nrf2. Collectively, these results denoted that azithromycin-associated cardiac injuries might be sequelae of the disturbance in oxidative/antioxidant status, upregulated expression of TLR4 and NF- κ B, and subsequent immunomodulation of pro-inflammatory responses and anti-inflammatory defenses within cardiac tissues.

Interestingly, the concomitant administration of lactoferrin with azithromycin protected rats, in lactoferrin\azithromycin group, against azithromycin-induced inflammatory responses, as revealed by the significant decrease in cardiac expression of pro-inflammatory and inflammatory biomarkers, namely TLR4, NF- κ B, and IL-1 β . Moreover, lactoferrin-induced anti-inflammatory defenses through the upregulated cardiac expression of protective IL-10 and Nrf2. Previous studies have reported immunomodulatory and anti-inflammatory potentials of lactoferrin, giving credence to our results⁵⁵. Lactoferrin has been reported to ameliorate thioacetamide-induced liver injury and chromium-Induced renal injury in rats by suppressing NF- κ B and other inflammatory cytokines expression^{24, 56}. Recently, Nemati *et al.* has reported that lactoferrin exhibited anti-inflammatory effects in RAW264.7 cell culture *via* suppression of TLR4 and NF- κ B expression⁵⁷. Collectively, our findings, alongside these previous reports, suggest an anti-inflammatory, cardioprotective mechanism of lactoferrin against azithromycin-induced cardiotoxicity *via* modulation of oxidative stress/TLR4/NF- κ B pathway.

CONCLUSION

Nowadays, azithromycin is used as an antimicrobial agent against bacterial infection, and in Egyptian management protocols for COVID-19, yet azithromycin-induced cardiac toxicity might develop very rapidly. Our study concludes that the concomitant administration of lactoferrin with azithromycin protects

against the rapid development of azithromycin-associated cardiac injury. The lactoferrin cardioprotective potentials could be mediated *via* the downregulation of oxidative stress and modulation of the TLR4/NF- κ B pathways. Future research studies should be conducted to clarify the exact molecular mechanisms involved in the cardioprotective potentials of lactoferrin.

Our study findings recommend combining lactoferrin, an immune-boosting probiotic, with azithromycin to manage severe infections, particularly COVID-19 infection.

Acknowledgment

The authors acknowledged Assistant Professor Walaa F. Awdin, Department of Pathology, Faculty of Veterinary Medicine, Mansoura University, Egypt, for the conduction of histopathological and immunohistochemical estimation.

Conflict of interest

The authors declare that they don't have any conflict of interest.

REFERENCES

1. Gaynor, M.; Mankin, A. S., Macrolide antibiotics: binding site, mechanism of action, resistance. *Curr. Top. Med. Chem.* **2003**, *3* (9), 949-960.
2. Grandy, J. K., Clinical update: Macrolides and cardiovascular death. *J. Pharm. Pharm. Sci.* **2013**, *16*, 551-63.
3. Parnham, M. J.; Haber, V. E.; Giamarellos-Bourboulis, E. J.; Perletti, G.; Verleden, G. M.; Vos, R., Azithromycin: mechanisms of action and their relevance for clinical applications. *Pharmacol. Ther.* **2014**, *143* (2), 225-245.
4. Du, X.; Zuo, X.; Meng, F.; Wu, F.; Zhao, X.; Li, C.; Cheng, G.; Qin, F. X.-F., Combinatorial screening of a panel of FDA-approved drugs identifies several candidates with anti-Ebola activities. *Biochem. Biophys. Res. Commun.* **2020**, *522* (4), 862-868.
5. Retallack, H.; Di Lullo, E.; Arias, C.; Knopp, K. A.; Laurie, M. T.; Sandoval-Espinosa, C.; Leon, W. R. M.; Krencik, R.; Ullian, E. M.; Spatazza, J., Zika virus cell tropism in the developing human brain and inhibition by azithromycin. *Proc. Natl. Acad. Sci.* **2016**, *113* (50), 14408-14413.
6. Wu, Y.-H.; Tseng, C.-K.; Lin, C.-K.; Wei, C.-K.; Lee, J.-C.; Young, K.-C., ICR suckling mouse model of Zika virus infection for disease modeling and drug validation. *PLoS Negl. Trop. Dis.* **2018**, *12* (10), e0006848.
7. Li, C.; Zu, S.; Deng, Y.-Q.; Li, D.; Parvatiyar, K.; Quanquin, N.; Shang, J.; Sun, N.; Su, J.; Liu, Z., Azithromycin protects against Zika virus infection by upregulating virus-induced type I and III

- interferon responses. *Antimicrob. Agents Chemother.* **2019**, 63 (12).
8. Tran, D. H.; Sugamata, R.; Hirose, T.; Suzuki, S.; Noguchi, Y.; Sugawara, A.; Ito, F.; Yamamoto, T.; Kawachi, S.; Akagawa, K. S., Azithromycin, a 15-membered macrolide antibiotic, inhibits influenza A (H1N1) pdm09 virus infection by interfering with virus internalization process. *J. antibiot.* **2019**, 72 (10), 759-768.
 9. Mosquera, R. A.; De Jesus-Rojas, W.; Stark, J. M.; Yadav, A.; Jon, C. K.; Atkins, C. L.; Samuels, C. L.; Gonzales, T. R.; McBeth, K. E.; Hashmi, S. S., Role of prophylactic azithromycin to reduce airway inflammation and mortality in a RSV mouse infection model. *Pediatr. Pulmonol.* **2018**, 53 (5), 567-574.
 10. Beigelman, A.; Isaacson-Schmid, M.; Sajol, G.; Baty, J.; Rodriguez, O. M.; Leege, E.; Lyons, K.; Schweiger, T. L.; Zheng, J.; Schechtman, K. B., Randomized trial to evaluate azithromycin's effects on serum and upper airway IL-8 levels and recurrent wheezing in infants with respiratory syncytial virus bronchiolitis. *J. Allergy Clin. Immunol.* **2015**, 135 (5), 1171-1178. e1.
 11. Zeng, S.; Meng, X.; Huang, Q.; Lei, N.; Zeng, L.; Jiang, X.; Guo, X., Spiramycin and azithromycin, safe for administration to children, exert antiviral activity against enterovirus A71 in vitro and in vivo. *Int. J. Antimicrob. Agents* **2019**, 53 (4), 362-369.
 12. Bleyzac, N.; Goutelle, S.; Bourguignon, L.; Tod, M., Azithromycin for COVID-19: More Than Just an Antimicrobial? Springer: 2020.
 13. Andreani, J.; Le Bideau, M.; Dufлот, I.; Jardot, P.; Rolland, C.; Boxberger, M.; Wurtz, N.; Rolain, J.-M.; Colson, P.; La Scola, B., In vitro testing of combined hydroxychloroquine and azithromycin on SARS-CoV-2 shows synergistic effect. *Microb. Pathog.* **2020**, 104228.
 14. Gautret, P.; Lagier, J.-C.; Parola, P.; Meddeb, L.; Mailhe, M.; Doudier, B.; Courjon, J.; Giordanengo, V.; Vieira, V. E.; Dupont, H. T., Hydroxychloroquine and azithromycin as a treatment of COVID-19: results of an open-label non-randomized clinical trial. *Int. J. Antimicrob. Agents* **2020**, 105949.
 15. Hancox, J. C.; Hasnain, M.; Vieweg, W. V. R.; Crouse, E. L. B.; Baranchuk, A., Azithromycin, cardiovascular risks, QTc interval prolongation, torsade de pointes, and regulatory issues: a narrative review based on the study of case reports. *Ther. Adv. Infect. Dis.* **2013**, 1 (5), 155-165.
 16. Ray, W. A.; Murray, K. T.; Hall, K.; Arbogast, P. G.; Stein, C. M., Azithromycin and the risk of cardiovascular death. *N. Engl. J. Med.* **2012**, 366 (20), 1881-1890.
 17. Svanström, H.; Pasternak, B.; Hviid, A., Use of azithromycin and death from cardiovascular causes. *N. Engl. J. Med.* **2013**, 368 (18), 1704-1712.
 18. Atli, O.; Ilgin, S.; Altuntas, H.; Burukoglu, D., Evaluation of azithromycin induced cardiotoxicity in rats. *Int. J. Clin. Exp. Med.* **2015**, 8 (3), 3681.
 19. El-Shitany, N. A.; El-Desoky, K., Protective effects of carvedilol and vitamin C against azithromycin-induced cardiotoxicity in rats via decreasing ROS, IL1- β , and TNF- α production and inhibiting NF- κ B and caspase-3 expression. *Oxid. Med. Cell. Longev.* **2016**, 2016.
 20. Ayaz, N., Bovine lactoferrin ameliorates cardiac muscle damage caused by nicotine toxicity by suppressing inflammatory signaling pathway. *J. Pharmaceut. Phytopharmacol. Res.* **2017**, 7 (2), 18-24.
 21. Chang, R.; Ng, T. B.; Sun, W. Z., Lactoferrin as potential preventative and adjunct treatment for COVID-19. *Int. J. Antimicrob. Agents* **2020**, 56 (3), 106118.
 22. Puddu, P.; Valenti, P.; Gessani, S., Immunomodulatory effects of lactoferrin on antigen presenting cells. *Biochimie* **2009**, 91 (1), 11-8.
 23. Gifford, J. L.; Hunter, H. N.; Vogel, H., Lactoferrin. *Cell. Mol. Life Sci.* **2005**, 62 (22), 2588-2598.
 24. Hegazy, R.; Salama, A.; Mansour, D.; Hassan, A., Renoprotective Effect of Lactoferrin against Chromium-Induced Acute Kidney Injury in Rats: Involvement of IL-18 and IGF-1 Inhibition. *PLoS ONE* **2016**, 11 (3), e0151486.
 25. Hegazy, R. R.; Mansour, D. F.; Salama, A. A.; Abdel-Rahman, R. F.; Hassan, A. M., Regulation of PKB/Akt-pathway in the chemopreventive effect of lactoferrin against diethylnitrosamine-induced hepatocarcinogenesis in rats. *Pharmacol. Rep.* **2019**, 71 (5), 879-891.
 26. Field, K. J.; White, W. J.; Lang, C. M., Anaesthetic effects of chloral hydrate, pentobarbitone and urethane in adult male rats. *Lab. Anim.* **1993**, 27 (3), 258-69.
 27. Abu-Elsaad, N. M.; Abd Elhameed, A. G.; El-Karef, A.; Ibrahim, T. M., Yogurt containing the probacteria *Lactobacillus acidophilus* combined with natural antioxidants mitigates doxorubicin-induced cardiomyopathy in rats. *J. Med. Food* **2015**, 18 (9), 950-959.
 28. Madrid, P. B.; Panchal, R. G.; Warren, T. K.; Shurtleff, A. C.; Endsley, A. N.; Green, C. E.; Kolokoltsov, A.; Davey, R.; Manger, I. D.; Gilfillan, L., Evaluation of Ebola virus inhibitors for drug repurposing. *ACS Infect. Dis.* **2015**, 1 (7), 317-326.
 29. Bosseboeuf, E.; Aubry, M.; Nhan, T.; De Pina, J.; Rolain, J.; Raoult, D.; Musso, D., Azithromycin

- inhibits the replication of Zika virus. *J. Antivir. Antiretrovir.* **2018**, *10* (1), 6-11.
30. Bacharier, L. B.; Guilbert, T. W.; Mauger, D. T.; Boehmer, S.; Beigelman, A.; Fitzpatrick, A. M.; Jackson, D. J.; Baxi, S. N.; Benson, M.; Burnham, C.-A. D., Early administration of azithromycin and prevention of severe lower respiratory tract illnesses in preschool children with a history of such illnesses: a randomized clinical trial. *JAMA* **2015**, *314* (19), 2034-2044.
 31. Gifford, J. L.; Hunter, H. N.; Vogel, H., Lactoferrin. *Cell Mol. Life Sci.* **2005**, *62* (22), 2588.
 32. Tsubota, A.; Yoshikawa, T.; Nariai, K.; Mitsunaga, M.; Yumoto, Y.; Fukushima, K.; Hoshina, S.; Fujise, K., Bovine lactoferrin potently inhibits liver mitochondrial 8-OHdG levels and retrieves hepatic OGG1 activities in Long-Evans Cinnamon rats. *J. Hepatol.* **2008**, *48* (3), 486-493.
 33. Adlerova, L.; Bartoskova, A.; Faldyna, M., Lactoferrin: a review. *Vet. Med. (Praha)* **2008**, *53* (9), 457-468.
 34. Bartoskova, A.; Adlerova, L.; Kudlackova, H.; Leva, L.; Vitasek, R.; Faldyna, M., Lactoferrin in canine sera: a pyometra study. *Reproduct. Domest. Anim.* **2009**, *44*, 193-195.
 35. Walker, D. B., Serum chemical biomarkers of cardiac injury for nonclinical safety testing. *Toxicol. Pathol.* **2006**, *34* (1), 94-104.
 36. Coloma, P. M.; Schuemie, M. J.; Trifirò, G.; Furlong, L.; van Mulligen, E.; Bauer-Mehren, A.; Avillach, P.; Kors, J.; Sanz, F.; Mestres, J., Drug-induced acute myocardial infarction: identifying 'prime suspects' from electronic healthcare records-based surveillance system. *PLoS One* **2013**, *8* (8), e72148.
 37. Alnahdi, H. S.; Ayaz, N. O.; Mohamed, A. M.; Sharaf, I. A.; Alshehri, N. M., Modulating impacts of quercetin and/or lactoferrin on diabetic nephropathy and cardiomyopathy induced rats. *Int. J. Pharmaceut. Res. Appl. Sci.* **2017**, *6* (2).
 38. Blondeau, J. M., The evolution and role of macrolides in infectious diseases. *Expert Opin. Pharmacother.* **2002**, *3* (8), 1131-1151.
 39. Tilelli, J. A.; Smith, K. M.; Pettignano, R., Life-Threatening Bradyarrhythmia After Massive Azithromycin Overdose. *Pharmacother.: J. Hum. Pharmacol. Drug Ther.* **2006**, *26* (1), 147-150.
 40. Santos, N.; Oliveira, M.; Galrinho, A.; Oliveira, J. A.; Ferreira, L.; Ferreira, R., QT interval prolongation and extreme bradycardia after a single dose of azithromycin. *Revist. Port. Cardiol* **2010**, *29* (1), 139-142.
 41. Aro, A. L.; Anttonen, O.; Kerola, T.; Junttila, M. J.; Tikkanen, J. T.; Rissanen, H. A.; Reunanen, A.; Huikuri, H. V., Prognostic significance of prolonged PR interval in the general population. *Eur. Heart J.* **2014**, *35* (2), 123-129.
 42. Braam, S. R.; Tertoolen, L.; van de Stolpe, A.; Meyer, T.; Passier, R.; Mummery, C. L., Prediction of drug-induced cardiotoxicity using human embryonic stem cell-derived cardiomyocytes. *Stem cell Res.* **2010**, *4* (2), 107-116.
 43. Yap, Y. G.; Camm, A. J., Drug induced QT prolongation and torsades de pointes. *Heart* **2003**, *89* (11), 1363-1372.
 44. Namboodiri, N., Bradycardia-induced Torsade de Pointes—An arrhythmia Less Understood. *Indian Pacing Electrophysiol. J.* **2010**, *10* (10), 435.
 45. Giudicessi, J. R.; Ackerman, M. J., Azithromycin and risk of sudden cardiac death: guilty as charged or falsely accused? *Cleve. Clin. J. Med.* **2013**, *80* (9), 539-544.
 46. Thomsen, M. B.; Beekman, J.; Attevelt, N.; Takahara, A.; Sugiyama, A.; Chiba, K.; Vos, M., No proarrhythmic properties of the antibiotics Moxifloxacin or Azithromycin in anaesthetized dogs with chronic-AV block. *Br. J. Pharmacol.* **2006**, *149* (8), 1039-1048.
 47. MK., H., Introduction to Electrocardiography: The Genesis and Conduction of Cardiac Rhythm. *Tufts-New England Medical Center* **2008**.
 48. Pacher, P.; Schulz, R.; Liaudet, L.; Szabó, C., Nitrosative stress and pharmacological modulation of heart failure. *Trends Pharmacol. Sci.* **2005**, *26* (6), 302-310.
 49. Gulmez, C.; Dalginli, K. Y.; Atakisi, E.; Atakisi, O., The Protective Effect of Lactoferrin on Adenosine Deaminase, Nitric Oxide and Liver Enzymes in Lipopolysaccharide-Induced Experimental Endotoxemia Model in Rats. *KAFKAS ÜNİV. VET. FAKÜLTESİ DERGİSİ* **2020**, *26* (6).
 50. Kruzel, M. L.; Zimecki, M.; Actor, J. K., Lactoferrin in a context of inflammation-induced pathology. *Front. Immunol.* **2017**, *8*, 1438.
 51. Hsu, Y.-H.; Chiu, I.-J.; Lin, Y.-F.; Chen, Y.-J.; Lee, Y.-H.; Chiu, H.-W., Lactoferrin Contributes a Renoprotective Effect in Acute Kidney Injury and Early Renal Fibrosis. *Pharmaceutics* **2020**, *12* (5), 434.
 52. Cohen, M. S.; Mao, J.; Rasmussen, G. T.; Serody, J. S.; Britigan, B. E., Interaction of Lactoferrin and Lipopolysaccharide (LPS): Effects on the Antioxidant Property of Lactoferrin and the Ability of LPS to Prime Human Neutrophils for Enhanced Superoxide Formation. *J. Infect. Dis.* **1992**, *166* (6), 1375-1375.
 53. Lan, W.; Petznick, A.; Heryati, S.; Rifada, M.; Tong, L., Nuclear Factor-κB: Central Regulator in Ocular Surface Inflammation and Diseases. *The Ocular Surface* **2012**, *10* (3), 137-148.

54. Liu, K.; Wang, F.; Wang, S.; Li, W.-N.; Ye, Q., Mangiferin Attenuates Myocardial Ischemia-Reperfusion Injury via MAPK/Nrf-2/HO-1/NF- κ B In Vitro and In Vivo. *Oxid. Med. Cell. Longev.* **2019**, 2019, 7285434. Legrand D.; Ellass E.; Carpentier M.; J., M., Lactoferrin: a modulator of immune and inflammatory responses. *Cell. Mol. Life Sci.* **2005**, 62, 2549-2559.
55. Hessin, A.; Hegazy, R.; Hassan, A.; Yassin, N.; Kenawy, S., Lactoferrin enhanced apoptosis and protected against thioacetamide-induced liver fibrosis in rats. *Maced. J. Med. Sci.* **2015**, 3 (2), 195-201.
56. Nemati, M.; Akseh, S.; Amiri, M.; Reza Nejabati, H.; Jodati, A.; Fathi Maroufi, N.; Faridvand, Y.; Nouri, M., Lactoferrin suppresses LPS-induced expression of HMGB1, microRNA 155, 146, and TLR4/MyD88/NF- κ B pathway in RAW264. 7 cells. *Immunopharmacol. Immunotoxicol.* **2021**, 1-11