



Carving the Niche for Implant Placement in Narrow Alveolar Ridges: A Case Report

**Shruti Sai^{a*#}, Mahesh Ghadage^{a≡}, Sumit Bedia^{a⊖}, Mridula Joshi^{a†},
Hrishikesh Mahapatra^{a#} and Aarti Bedia^{b‡}**

^a Department of Prosthodontics, Bharati Vidyapeeth (Deemed to be University), Dental College and Hospital, Navi Mumbai, India.

^b Department of Oral Medicine and Radiology, Bharati Vidyapeeth (Deemed to be University), Dental College and Hospital, Navi Mumbai, India.

Authors' contributions

This work was carried out in collaboration among all authors. All authors read and approved the final manuscript.

Article Information

DOI: 10.9734/JPRI/2021/v33i63A35236

Open Peer Review History:

This journal follows the Advanced Open Peer Review policy. Identity of the Reviewers, Editor(s) and additional Reviewers, peer review comments, different versions of the manuscript, comments of the editors, etc are available here: <https://www.sdiarticle5.com/review-history/78872>

Case Report

Received 20 October 2021
Accepted 27 December 2021
Published 29 December 2021

ABSTRACT

Insufficient width of the alveolar ridge often prevents ideal implant placement. Guided bone regeneration, bone grafting, alveolar ridge splitting and combinations of these techniques are used for the lateral augmentation of the alveolar ridge. Ridge splitting is a minimally invasive technique indicated for alveolar ridges with adequate height, which enables immediate implant placement and eliminates morbidity and overall treatment time. The classical approach of the technique involves splitting the alveolar ridge into two parts with use of ostetomes and chisels. Modifications of this technique include the use of rotating instrument, screw spreaders, horizontal spreaders and ultrasonic device. The purpose of this article is to thoroughly describe all the different approaches in ridge splitting technique. Procedures in Dental implantology have witnessed significant advancement in the recent times. A plethora of options have opened these days owing to improved surgical techniques and wider criteria for patient selection. Ridge-expansion technique has gained immense popularity in patients with limited crestal bone width yielding improved outcomes. The

PG Student;

≡ Assistant Professor;

⊖ Professor;

† Professor & HOD;

‡ Associate Professor;

*Corresponding author: E-mail: shrutishabu@gmail.com;

procedure entails implant placement in narrow alveolar ridges following splitting and expanding the existing bone. This article illustrates this approach with a fascinating clinical case of insufficient mandibular alveolar ridge.

Keywords: Osteotomy; ridge expansion; ridge splitting; alveolar ridge augmentation.

1. INTRODUCTION

One of the major challenges for successfully placing an implant is insufficient width of the alveolar ridge. An adequate volume and quality of hard and soft tissues is a requirement to fulfill the ideal goals of implant dentistry [1]. Optimum amount of bone in terms of both horizontal and vertical dimension, must be available which is fundamental for implant therapy to be successful, however it is often difficult to place the implant when adequate amount of bone is not available. Augmentation of inadequate alveolar ridges still remains a significant aspect in dental implant therapy, to achieve optimum amount of bone. The aim is to provide functional restoration in harmonious relationship with the remaining natural dentition.

Sibert designated ridge deficiencies as class A, B and C i.e., horizontal, vertical or a combination of both, respectively. Insufficient alveolar ridge areas can be improved by guided bone regeneration (GBR), block grafts, etc [2]. With expectable outcome in maxilla than in mandible. Ridge expansion techniques are advantageous for dealing with narrow edentulous ridge for implant placement [3]. This technique, takes benefit of the osteoconductive and osteogenic dynamics of the native bone. With the application of devices such as thin diamond disks or piezoelectric cutting devices, surgical time has reduced regardless of bone quality. This has reduced the overall treatment time and boosted the success rates of 'Alveolar Split Ridge Technique.' This technique cannot be used for vertical deficiencies; it can however be used for horizontal ridge inconsistencies. Thus, it can be used in the augmentation of alveolar ridges with appropriate height [4]. A bucco-lingual width of at-least 3mm is a pre-requisite for this technique with a minimum of 1 mm of cancellous bone sandwiched within 2 plates of cortical bone, that would confirm the placement of instruments and adequate blood supply to the parts [5,6]. This case report describes a method of successfully expanding the bone at the region of implant placement with respect to mandibular left 1st and 2nd molar.

2. CASE REPORT

A 27-year-old female patient reported to the Department of Prosthodontics, with a complaint of missing mandibular left 1st and 2nd molars since six months. No relevant systemic history was revealed by the patient (Fig. 1). The Cone Beam Computed Tomography scan data (Fig. 2) revealed an alveolar ridge width of 4 mm which was found to be scarce for implant placement. However, an acceptable alveolar ridge height was seen that of 11.0mm. Values in the normal reference range were observed in routine blood investigation. Implant placement on the same day preceded by a ridge split procedure for ridge augmentation in the same visit was planned in the left mandibular 1st and 2nd molar region [7].

A mucoperiosteal flap of full thickness was elevated after crestal and intra-crevicular incisions and the bone ridge was exposed (Fig. 3). The cortical bone was curetted with a back action chisel to remove all residual connective tissue and periosteum. A simple corticotomy at the crestal aspect of the buccal cortical plate was performed. A horizontal corticotomy using a microsaw was performed (Fig. 4), located slightly lingually with respect to the centre of the edentulous ridge along the entire area which was to be expanded. The cut was maintained parallel to the outer contour of the buccal plate to give it a uniform thickness (Fig. 5). Chisels of increasing dimensions up to a width of 2.5mm were used to displace the buccal plate, producing a greenstick fracture (Fig. 6). The chisel was gently tapped on with a hammer to create a cut (Fig. 7). To spread apart the cortical plates, the same chisel was used as a lever. The fracture was extended to a depth of about 7mm for initial expansion which was subsequently increased till the implant length. Intact bone was left apical to this site to provide primary stabilization of the placed implants. Subsequently, the implant site was prepared (Fig. 8) using increasing sizes of the implant kit drills. Tapered spiral implants were positioned (3.75 * 10 mm) each with respect to teeth no's 36, 37 (Fig. 9). Acting as bone expander screws, the conical shape of the implants contributed to the completion of the

ridge expansion. The flaps were approximated and interrupted sutures (4-0 absorbable) were placed (Fig. 10). Routine postoperative instructions were given. Patient was recalled after 1 week for suture removal.

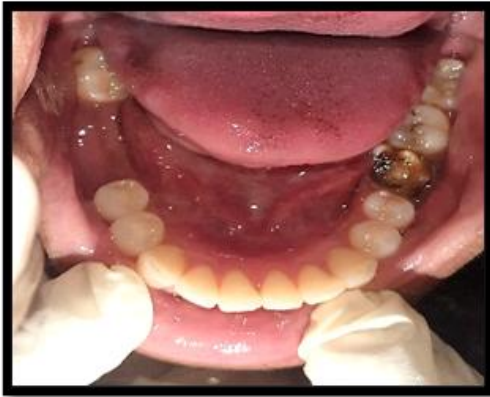

Fig. 1. Pre-operative situation

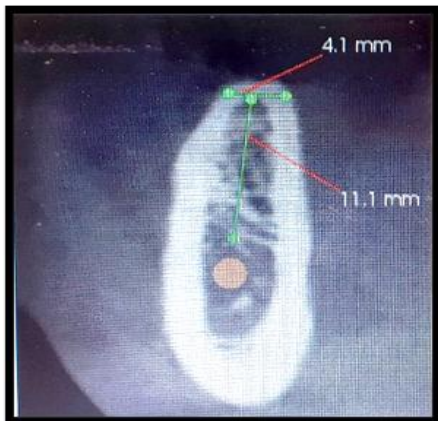

Fig. 2. CBCT section showing the available bone height and width

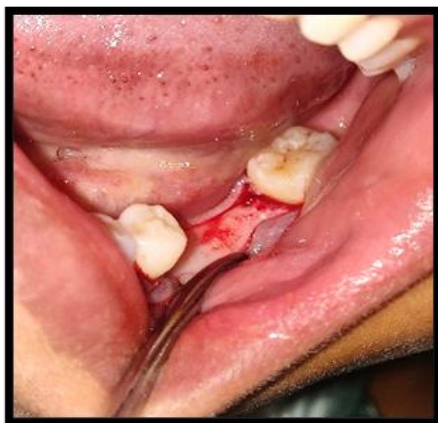

Fig. 3. Full thickness mucoperiosteal flap elevated to expose the underlying bone

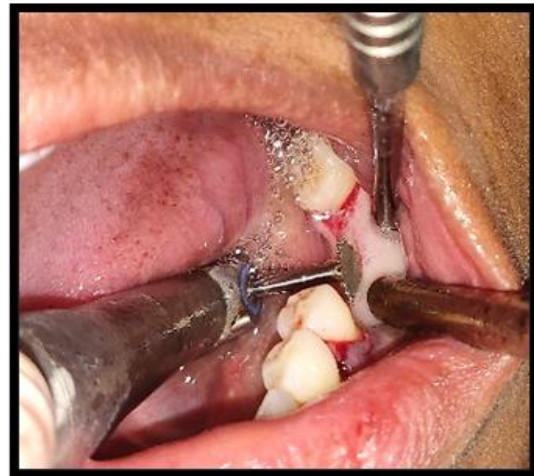

Fig. 4. Horizontal corticotomy done using microsaw

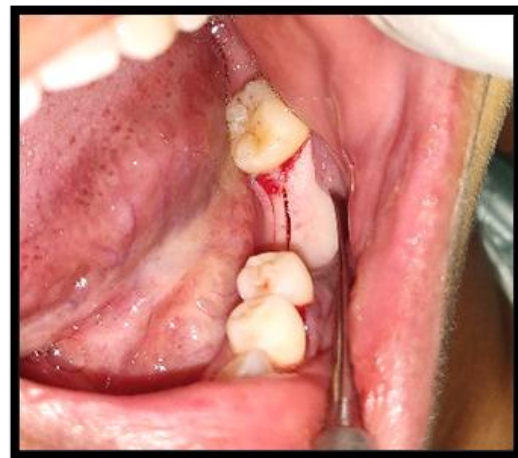

Fig. 5. Horizontal corticotomy done

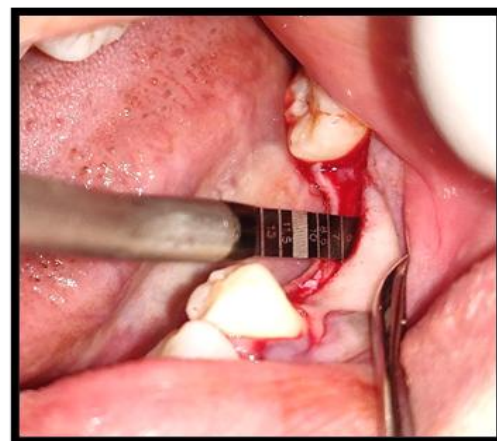


Fig. 6. Use of chisel for ridge splitting done using chisel

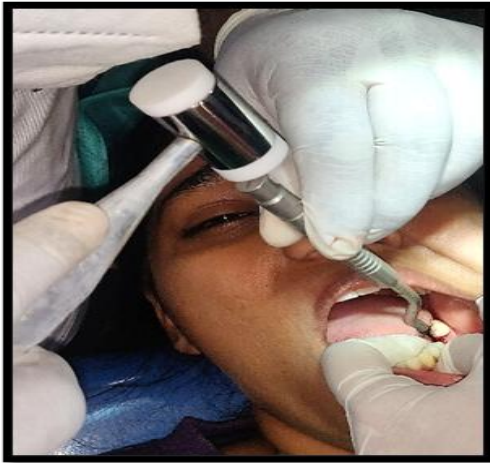

Fig. 7. Gentle tapping of the hammer over the chisel for ridge splitting

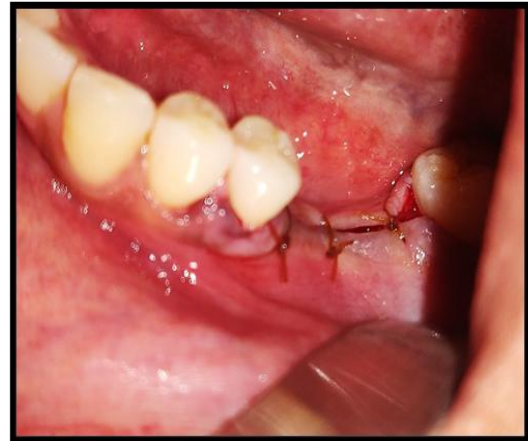

Fig. 10. Interrupted absorbable sutures placed to achieve primary closure of the operative

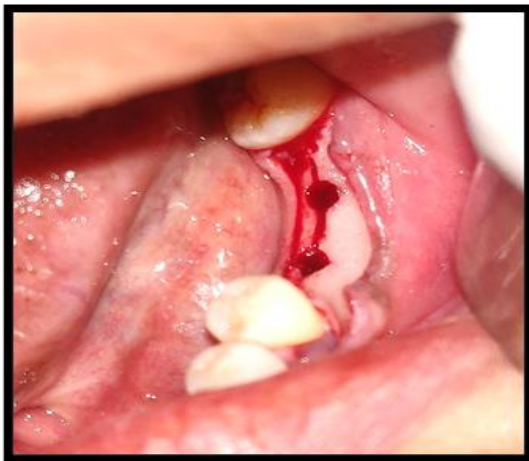


Fig. 8. Final osteotomy site

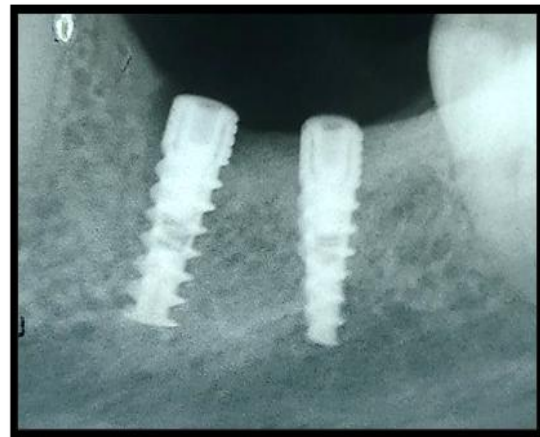


Fig. 11. Intra-Oral Peri Apical Radiograph at six months follow up

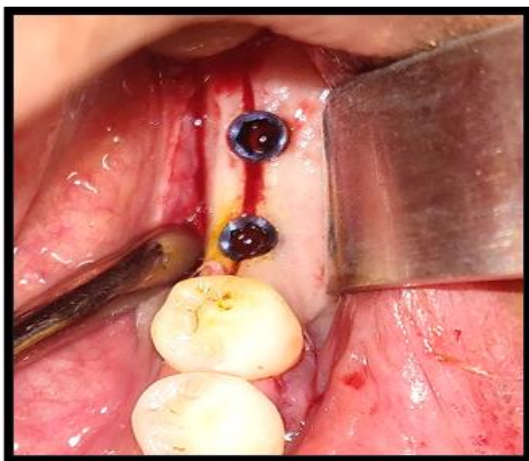

Fig. 9. Two implants (3.5 x 10 mm) each placed in the prepared osteotomy site

3. DISCUSSION

Nentwig, in 1986 advocated a technique of bone crest division that concomitantly allowed the widening of the alveolar crest and implant placement [7]. A horizontal osteotomy cut is placed dividing the crest of cortical bone, where fixture osteotomy sites are prepared for simultaneous placement. The areas that remain can be packed with autologous biological therapeutic agents such as plasma rich in growth factors, autologous grafts, etc. The predictable way in which the narrow alveolar ridge can be expanded and concurrently be simple and quick remains the main advantage of the ridge split technique. With not requiring a second surgical site, this allows use of bone grafts, in turn decreasing the possibilities of pain, nerve injury, and oedema. Alveolar ridges that are narrow

need to be augmented before implant placement in-order to attain an effective and foreseeable treatment outcome [8].

In the maxilla, the outcomes reported have been significant; however, in the mandible due to the thick cortical plates the chances of the osteotomised segment increases. In this case, initially only a horizontal cut was made followed by ridge expansion through a series of chisels. The buccal and the lingual periosteum were conserved to warrant enough blood supply to the bone.

Enislidis et al in 2006 reported on the ridge splitting technique where in Stage 2 the implants were placed [9]. However, in this case the implants were placed on the same day as that of the ridge split procedure. One-stage surgery was possible, since primary stability was attained mainly from the apical bone division. Added advantages of concurrent implant placement include a decrease in time amidst the first surgery and prosthetic rehabilitation. Moreover, immediate implant placement involves less amounts of biomaterials, reduces the cost, and the breakdown of the expanded cortical walls is also averted. It also results in reduced agony for the patient since only one surgery will be performed.

Hand instruments such as a hammer and chisel were used along with a microsaw for splitting the ridge. They were pushed against the bone with specific and mild blows.

The conventional techniques, however time consuming are better in contrast to the rotary instruments as they are less likely to damage the tissues such as the cheeks, tongue and lips. In addition, the management of rotary instruments are hard when teeth adjacent to it are present, due to the essential angulation [10,11].

4. CONCLUSION

The ridge splitting technique seems to be a procedure that is commonly used for narrow alveolar ridge expansion horizontally. The results accomplished from various studies can be predictable if correct assessment is done before procedure and a thorough surgical protocol is followed meticulously.

DISCLAIMER

The products used for this research are commonly and predominantly use products in our

area of research and country. There is absolutely no conflict of interest between the authors and producers of the products because we do not intend to use these products as an avenue for any litigation but for the advancement of knowledge. Also, the research was not funded by the producing company rather it was funded by personal efforts of the authors.

CONSENT

We have added the Consent Disclaimer in the revised paper. The revised paper is attached here with this mail for your kind perusal. Kindly check the revised paper.

ETHICAL APPROVAL

As per international standard or university standard written ethical approval has been collected and preserved by the author(s).

COMPETING INTERESTS

Authors have declared that no competing interests exist.

REFERENCES

1. Sethi A, Kaus T. Maxillary ridge expansion with simultaneous implant placement: 5-year results of an ongoing clinical study. *Int J Oral Maxillofac Implants.* 2000;15:491-9.
2. Lieberman JR, Friedlander GE. 1st ed. Totowa NJ. Humana Press, Bone Regeneration and Repair, 2005;195- 6.
3. Summers RB. The osteotome technique: Part 4 – Future site development. *Compend Contin Educ Dent.* 1995;16: 1090-1092.
4. Demarosi F, Leghissa GC, Sardella A, Lodi G, Carrassi A. Localised maxillary ridge expansion with simultaneous implant placement: a case series. *Br J Oral Maxillofac Surg.* 2009; 47:535-540.
5. Dene L, Condos S. Ridge expansion and immediate implant placement in the esthetic zone. *N Y State Dent J.* 2010;76:28-31.
6. Chan HL, Fu JH, Koticha T, Benavides E, Wang HL. Ridge width gain with screw spreaders: a cadaver study. *Implant Dent.* 2013;22:552-558.
7. Nentwig GH. *Technic of bone splitting for alveolar recession in anterior maxillary region.* Quintessenz. 1986;37.

8. Anitua E, Begona L, Orive G. Two-stage split-crest technique with ultrasonic bone surgery for controlled ridge expansion: a novel modified technique. *Oral Surg Oral Med Oral Pathol Oral Radiol Endod.* 2011; 112:708–10.
9. Enislidis G, Wittwer G, Ewers R. Preliminary report on a staged ridge splitting technique for implant placement in the mandible: a technical note. *Int J Oral Maxillofac Implants.* 2006;21:445–449.
10. Anitua E, Begona L, Orive G. Clinical evaluation of split-crest technique with ultrasonic bone surgery for narrow ridge expansion: status of soft and hard tissues and implant success. *Clin Implant Dent Relat Res.* 2013;15:176–87.
11. Blus C, Szmukler-Moncler S, Voza I, Rispoli L, Polastri C. Split-crest and immediate implant placement with ultrasonic bone surgery (Piezosurgery): 3-year follow-up of 180 treated implant sites. *Quintessence Int.* 2010;41:463–9.

© 2021 Sai et al.; This is an Open Access article distributed under the terms of the Creative Commons Attribution License (<http://creativecommons.org/licenses/by/4.0>), which permits unrestricted use, distribution, and reproduction in any medium, provided the original work is properly cited.

Peer-review history:

The peer review history for this paper can be accessed here:
<https://www.sdiarticle5.com/review-history/78872>