



# Uterine Rupture Associated with Placenta Accreta in a Communicating Pseudo-unicornus: A Case Report and Review of the Literature

Niang Ndama <sup>a,b,c\*</sup>, Diop Khary <sup>b</sup>, Diop Alioune <sup>b</sup>,  
Ndiaye Awa <sup>b</sup>, Badji Amadou <sup>b</sup>, Sene Mamadou <sup>b</sup>,  
Diouf Abdoul Aziz <sup>a,c</sup> and Diouf Alassane <sup>a,c</sup>

<sup>a</sup> Gynecological and Obstetrical Clinic, Aristide Le Dantec Hospital, Dakar, Senegal.

<sup>b</sup> Public Health Establishment level 1, Touba Ndamatou, Diourbel, Senegal.

<sup>c</sup> Cheikh Anta Diop University, Dakar, Senegal.

## Authors' contributions

This work was carried out in collaboration among all authors. All authors read and approved the final manuscript.

## Article Information

### Open Peer Review History:

This journal follows the Advanced Open Peer Review policy. Identity of the Reviewers, Editor(s) and additional Reviewers, peer review comments, different versions of the manuscript, comments of the editors, etc are available here: <https://www.sdiarticle5.com/review-history/96463>

Case Study

Received: 21/10/2022

Accepted: 30/12/2022

Published: 31/12/2022

## ABSTRACT

**Introduction:** Uterine malformations are abnormalities of the development of the Müllerian ducts and represent 1 to 4% in terms of prevalence in the population. Pregnancy constitutes a circumstance of discovery of this congenital anomaly with an increased risk of obstetrical complications, the most dreaded of which are ectopic pregnancy and uterine rupture.

**Case Presentation:** We report in our observation a case of uterine malformation associated with pregnancy. This was a 20 years old female patient with a 34 SA pregnancy who presented with abdomino-pelvic pain. On clinical examination a threat of preterm delivery was suspected. Obstetrical ultrasound revealed a prævia mass suggesting adnexal torsion or a prævia myoma. A

\*Corresponding author: E-mail: ndamaniang@hotmail.com;

laparotomy was carried out, which revealed a communicating pseudo-unicornuate uterus (AFS class II type 3) with the pregnancy located in the communicating part. A subserous uterine rupture associated with a placenta accreta was noted at this level. Fetal extraction was performed followed by a hemostasis hysterectomy. The postoperative course was unremarkable with a healthy live infant.

**Conclusion:** These rare cases require a good prenatal follow-up with early ultrasound. This is often difficult in rural areas where the low socio-economic level favors a delay in diagnosis and management and the mode of discovery remains during an obstetrical complication.

**Keywords:** Uterine malformations; pseudo unicornuate uterus; uterine rupture; rudimentary horn.

## 1. INTRODUCTION

Uterine malformations are abnormalities of the development of the Müllerian ducts and represent 1 to 4% in terms of prevalence in the population. Pregnancy constitutes a circumstance of discovery of this congenital anomaly with an increased risk of obstetrical complications, the most dreaded of which are ectopic pregnancy and uterine rupture [1-5].

We report in our observation a case of uterine malformation associated with pregnancy.

## 2. CASE PRESENTATION

A 20 years old girl came on her own for abdomino-pelvic pain associated with a pregnancy of 33 SA. In her obstetrical history, she is a second gesture second pare all delivered by vaginal route without notion of complications.

She had three prenatal consultations without any particularities, with a prenatal check-up done without any particularities. She benefited from an obstetrical ultrasound performed late in the pregnancy at 19 weeks of age without any other anomaly being detected.

On admission, the general examination was normal. Obstetrically, the diagnosis of a moderate threat of labor according to the Baumgarten score was retained and the patient was hospitalized. Tocolysis with salbutamol and pulmonary maturation were initiated.

Ultrasound performed in the department revealed a heterogeneous praevia mass measuring 96 mm in long axis, as well as a total overlying placenta previa (Figs. 1 and 2). The hypothesis of adnexal torsion or necrobiosed myoma previa was put forward.

A remission of the symptomatology was observed during her hospitalization but 5 days later the abdominal pain resumed, which led to

the indication of an emergency exploratory laparotomy.

At the exploration we noted the existence of a communicating pseudo unicornuate uterus (Figs. 3(A-B) and 4(A-B)); with the pregnancy localized at the level of the communicating part (Fig. 4B), with a beginning of uterine rupture under serosa associated with a placenta praevia accreta.

A caesarean section followed by a hemi-hysterectomy was performed which allowed the extraction of a live female infant weighing 1700 g.

The postoperative course was simple and the hospital stay was 5 days.

The malformative workup done at a distance came back normal.

## 3. DISCUSSION

The discovery of a uterine malformation during pregnancy is rare [2].

Indeed, in the literature, the prevalence of these cases is estimated at 1/100000 or even 1/140000 [2].

The positive diagnosis of a pregnancy on a rudimentary horn of a pseudo-unicornuate uterus suffers from a delay in our context related to several factors: the diagnostic delay due to diagnostic wandering, the poor technical platform especially in rural areas and the presence of ultrasound equipment of low quality.

Furthermore, even with the availability of a good quality ultrasound machine, there remains a difficulty in ultrasound diagnosis. Tsafir et al proposed criteria for early ultrasound diagnosis of pregnancies on a rudimentary horn of a pseudo unicornuate uterus, namely: a pseudo picture of an asymmetric bicornuate uterus, absence of visual continuity between the cervix and the lumen of the horn containing the

pregnancy; presence of myometrial tissue around the gestational sac and more or less the presence of hypervascularization typical of a placenta accreta [6].

The differential diagnosis during exploratory laparotomy for uterine rupture between pseudo unicornuate uterus with rudimentary horn (type IIa or IIb of the AFS classification) and bicornuate uterus (IVb and especially IVa of the AFS classification) remains difficult as shown by our observation. This difficulty is reinforced by the fact that in some cases reported in the literature, there are approximations that do not allow precise differentiation of the two malformations [7,8,5]. Their distinction is all the more difficult as the rudimentary uterine horn is gravid and therefore of at least the same size as the main uterine horn.

Pregnancy in a rudimentary horn is associated with an increased risk of delayed uterine rupture in 50 to 80% of cases [3]. This fragility is explained by the distension of the horn, which leads to its rupture when the stretch following gestation becomes too great.

This fragility may be accentuated by pathological placental implantation (placenta accreta and percreta), leading to erosion of the horn [4]. These placentation anomalies are favored by a poor quality endometrium and a thin myometrial thickness. Uterine rupture occurs mainly in the second trimester in 60 to 90% of cases [1]. In case of discovery of a pregnancy on a rudimentary horn, the continuation of the pregnancy or the achievement of a medical termination of pregnancy can be debated. Indeed, it is frequent and there is currently no way to prevent this complication.

Most of the cases described concern monofetal pregnancies. A case of twin pregnancy in a pseudo unicornuate uterus evolving in each of the horns was described by Ejnes et al, with a preventive extraction of the two fetuses at 22 weeks of amenorrhea [9]. Three other cases have been described in 1945 [9,10]. Taheri et al. described a case of twin pregnancy in a pseudo unicornuate uterus, where in each hemimatrix there was an 8SA embryo; an early hemihysterectomy at 8SA was performed to avoid complications and keep the pregnancy evolving in the main horn [11].

The surgical management of this malformation during pregnancy is based on excision of the

rudimentary horn associated with ipsilateral salpingectomy. This procedure can be performed by laparotomy or laparoscopy [12,13].

Neoadjuvant medical treatment with methotrexate has also been described but the benefit of this treatment remains to be evaluated [14].

It seems necessary to refer these patients to a multidisciplinary prenatal diagnosis center (CPDPN) [2]; this is difficult in sub-Saharan Africa where such multidisciplinary centers are not yet in place.

#### 4. CONCLUSION

These rare cases require good prenatal follow-up with early ultrasound. This is often difficult in rural areas where the socio-economic level favors a delay in diagnosis and management and the mode of discovery remains during an obstetric complication. Hence the interest of a rapid establishment of a multidisciplinary center for prenatal diagnosis.

#### CONSENT

As per international standard or university standard, patient(s) written consent has been collected and preserved by the author(s).

#### ETHICAL APPROVAL

As per international standard or university standard written ethical approval has been collected and preserved by the author(s).

#### COMPETING INTERESTS

Authors have declared that no competing interests exist.

#### REFERENCES

1. Fuchs F, Guillot E, Cordier A-G, et al. Rupture of a rudimentary non-communicating gravid uterine horn in a pseudunicorn uterus at 23 weeks of amenorrhea: A case report. *Obstetrics Gynecology & Fertility*. Elsevier. 2008;36: 400-2.
2. Le Mitouard M, Huissoud C, Fichez A, et al. Uterine rupture clogged by the omentum on pregnancy developed at the expense of a rudimentary uterine horn:

- About a rare case. *Journal of Obstetrics Gynecology and Reproductive Biology*. 2016;45:521-4.
3. Nahum GG. Rudimentary uterine horn pregnancy. The 20th-century worldwide experience of 588 boxes. *The Journal of Reproductive Medicine*. 2002;47:151-63.
  4. Oral B, Güney M, Özsoy M, et al. Placenta accreta associated with a ruptured pregnant rudimentary uterine horn. *Archives of gynecology and obstetrics*. Springer. 2001;265:100-2.
  5. Poncelet C, Aissaoui F. Uterine malformations and reproduction. *Obstetrics gynecology & fertility*. Elsevier. 2007;35: 821-5.
  6. Tsafirir A, Rojansky N, Sela HY, et al. Rudimentary horn pregnancy: First-trimester prerupture sonographic diagnosis and confirmation by magnetic resonance imaging. *Journal of Ultrasound in Medicine*. Wiley Online Library. 2005;24:219-23.
  7. Benkhaira S, Fajri S, El Azery A, et al. Pregnancy carried to term in a septate uterus: About a case and review of the literature. *International Journal of Innovation and Applied Studies*. International Journal of Innovation and Applied Studies. 2021;32:421-5.
  8. Ebanga L, Dabi Y, Thomassin-Naggara I, et al. Original two-stage approach to ectopic pregnancy in a rudimentary horn: A single case report with a review of the literature. *Gynecology Obstetrics Fertility & Senology*. Elsevier; 2021.
  9. Ejnes L, Desprez B, Bongain A, et al. Twin pregnancy and unicorn uterus with rudimentary communicating horn. *Gynecology Obstetrics & Fertility*. 2003;31: 627-8.
  10. Sefrioui O, Azyez M, Babahabib A, et al. Pregnancy on rudimentary uterine horn: diagnostic difficulties and therapeutic aspects. *Gynecology Obstetrics & Fertility*. 2004;32:308-10.
  11. Taheri H, Saadi H, Benkirane S, et al. La grossesse gémellaire sur un utérus pseudo unicorne: à propos d'un cas. *Pan African Medical Journal*. 2015;22.
  12. Adolph AJ, Gilliland GB. Fertility following laparoscopic removal of rudimentary horn with an ectopic pregnancy. *Journal of Obstetrics and Gynecology Canada*. Elsevier. 2002;24:575-6.
  13. Siwatch S, Mehra R, Pandher DK, et al. Rudimentary horn pregnancy: A 10-year experience and review of literature. *Archives of gynecology and obstetrics*. Springer. 2013;287:687-95.
  14. Edelman AB, Jensen JT, Lee DM, et al. Successful medical abortion of a pregnancy within a noncommunicating rudimentary uterine horn. *American journal of obstetrics and gynecology*. Elsevier. 2003;189:886-7.

## APPENDICES

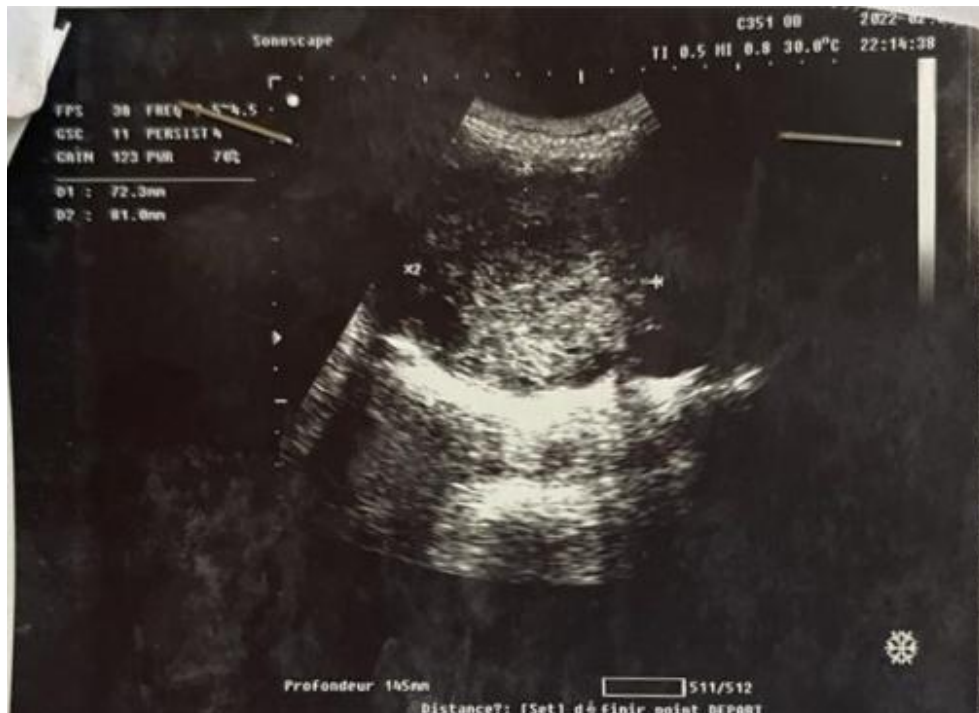

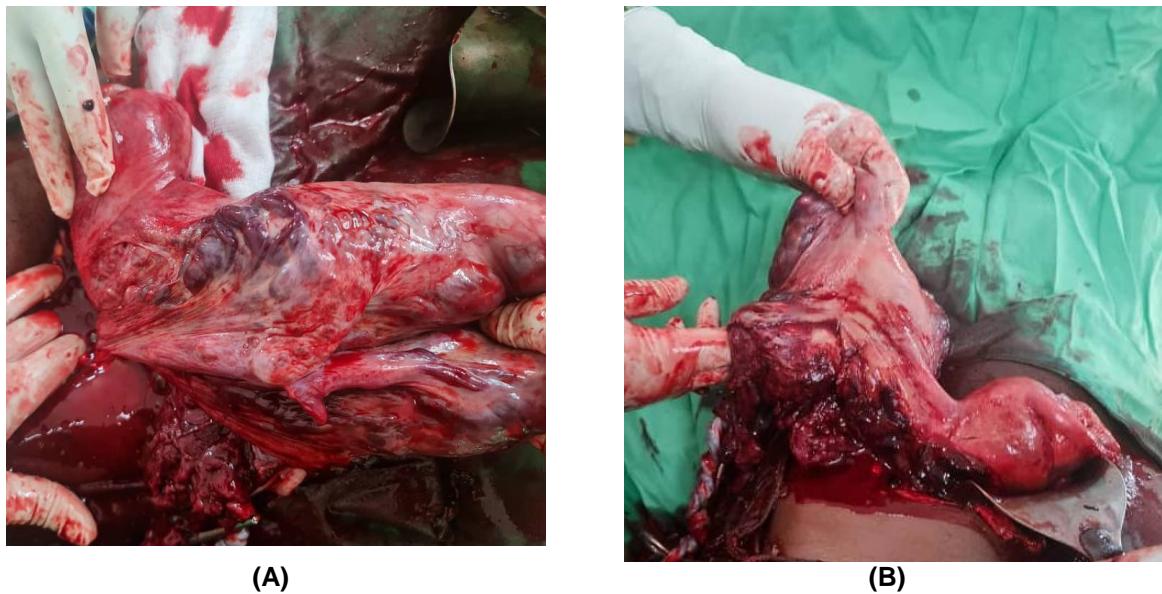
Fig. 1. Ultrasound image of the praevia mass

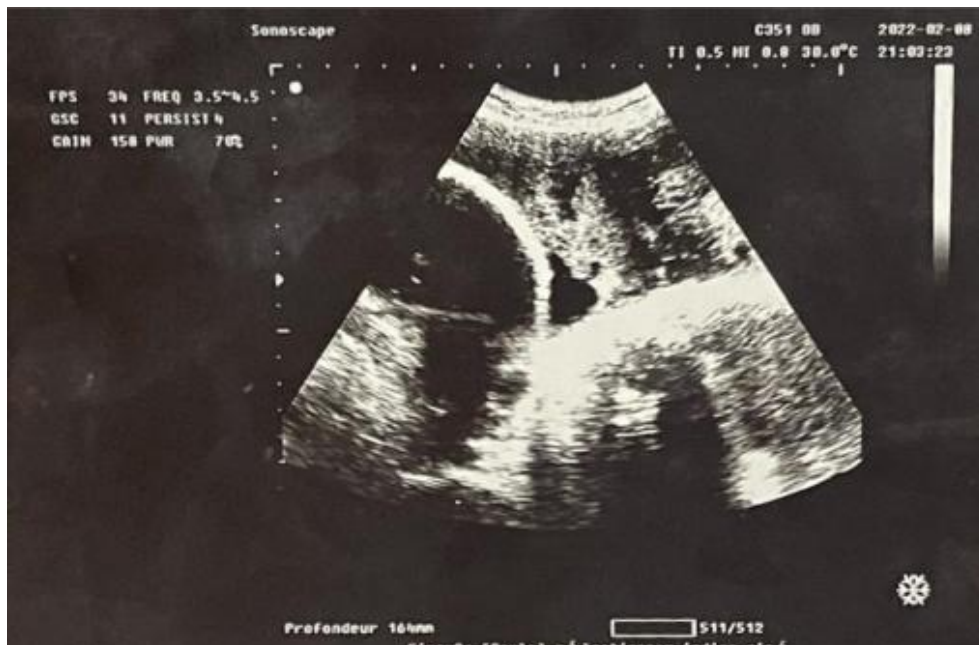
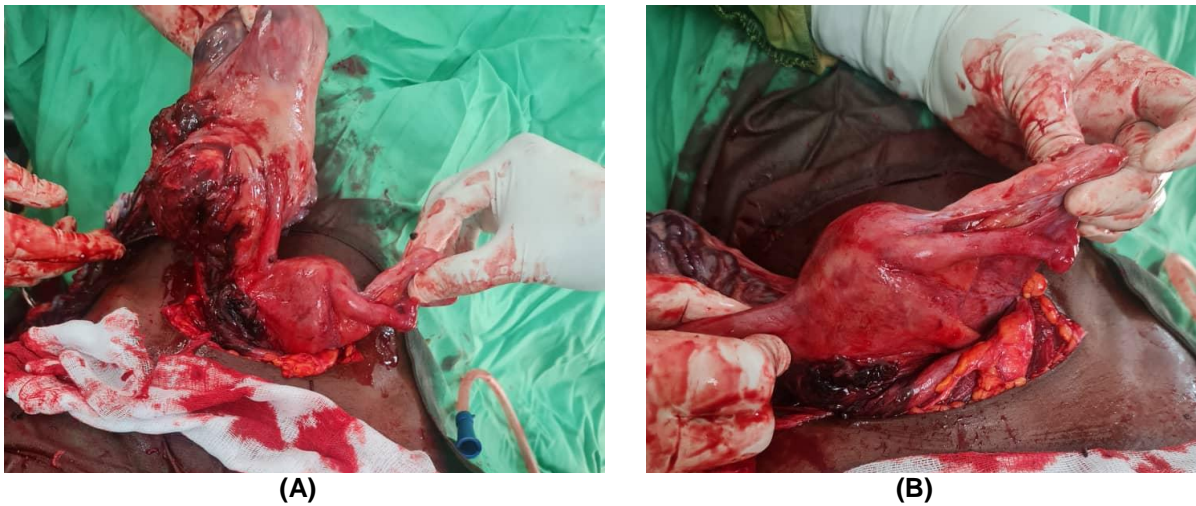
Fig. 2. Ultrasound image of the patient's low inserted anterior placenta



**Fig. 3 (A-B). Macroscopic aspect of the rudimentary horn and the normal horn after fetal extraction**



**Fig. 4(A-B). Post operative view of the malformation and demonstration of the communication of the rudimentary horn**

© 2022 Ndama et al.; This is an Open Access article distributed under the terms of the Creative Commons Attribution License (<http://creativecommons.org/licenses/by/4.0>), which permits unrestricted use, distribution, and reproduction in any medium, provided the original work is properly cited.

Peer-review history:  
The peer review history for this paper can be accessed here:  
<https://www.sdiarticle5.com/review-history/96463>