



Aspiration Cytology for Thyroid Lump in Remote Areas of Sindh

**Santosh Kumar Sidhwani^{1*}, Prem Shankar², Haresh Chand³,
Ali Mala⁴, Yameena Noman Khan⁴ and Jabbar Ahmed Qureshi¹**

¹*Department of Pathology, Ziauddin University, Karachi, Pakistan.*

²*Abbassi Shaheed Hospital, Karachi, Pakistan.*

³*Department of Pathology, Gambat Medical College, Gambat, Pakistan.*

⁴*Ziauddin University, Karachi, Pakistan.*

Authors' contributions

This work was carried out in collaboration among all authors. Authors SKS and HC designed the study, performed the statistical analysis, wrote the protocol and wrote the first draft of the manuscript.

Authors PS and JAQ managed the analyses of the study. Authors AM and YNK managed the literature searches. All authors read and approved the final manuscript.

Article Information

DOI: 10.9734/JAMMR/2020/v32i330392

Editor(s):

(1) Dr. Emmanouil (Manolis) Magiorkinis, General Hospital of Sotiria, Greece.

Reviewers:

(1) Komal Galani, India.

(2) Sandeep Kumar Agarwal, India.

(3) Arthur Chuemere, University of Port Harcourt, Nigeria.

Complete Peer review History: <http://www.sdiarticle4.com/review-history/55193>

Original Research Article

Received 21 December 2019

Accepted 29 February 2020

Published 24 March 2020

ABSTRACT

Background: Scandinavian countries were the first to use fine needle aspiration cytology (FNAC) as a diagnostic tool in the 1930. Fine needle aspiration cytology is a diagnostic approach, which helps the clinicians in diagnosis of the various lesions. Most common sites which can be targeted include breast lumps, lymph nodes, thyroid masses and other palpable swellings. The most common lesion encountered is thyroid nodule. In current cross sectional study we tried to find frequency of different thyroid lesions by fine needle aspiration cytology in different rural areas of Sindh.

Methodology and Results: 158 samples were recruited from the Vital Laboratory Larkana with different pathological midline neck (thyroid) swelling during 2014 and 2015 by non-probability consecutive sampling. 125 (79.1%) were females and 33 (20.9%) were males with a ratio of 4:1. Majority of case were of 20-39 years of age (52.5%). Most of the cases were diagnosed with

*Corresponding author: E-mail: Santosh.kumar@zu.edu.pk;

nodular goiter (88.6%) followed by colloid goiter (4.4%). In present study we failed to find any association of diagnosis with gender ($p=0.211$) and age ($p=0.553$).

Conclusion: So in this study we concluded that large number of thyroid lesions present with nodular goiter at the age of 20-39 years. The frequency is increased for these lesions due to different risk factors.

Keywords: FNAC; thyroid lesions; nodular goiter; aspiration; cytology.

1. INTRODUCTION

In the 1970's the introduction of Fine Needle Aspiration Cytology (FNAC) proved to be the key method for examining the nature and malignant potential of thyroid nodules [1]. Fine needle aspiration cytology is a minimum invasive and sensitive technique which is widely used to examine palpable lesions [2]. It primarily provides an authentic, quick and economical tissue diagnosis in most superficial palpable swellings and rarely non palpable swellings as well [3]. Most common sites which can be targeted include breast lumps, lymph nodes, thyroid masses and other palpable swellings. Fine needle aspiration is a cost effective and an accurate screening tool used in the diagnosis and workup of solitary thyroid nodules [4]. However the adequacy of FNAC depends primarily on the lesion, experience of the individual performing FNAC and expertise of the pathologist construing the aspirate [5].

Thyroid diseases are amongst the most common encountered disease in the hospitals and the prevalence of thyroid nodules depends on the population studies [6]. Studies have shown that the occurrence of thyroid nodules is directly proportional to the age, exposure to the radiation and iodine deficiency. Palpable thyroid nodules are evaluated through several other techniques but most commonly used is FNAC which also helps distinguish benign diseases from malignant diseases and therefore provide successful avoidance of surgical procedures [7].

Though palpable thyroid nodules can be evaluated through several other techniques but most commonly used is FNAC which also helps distinguish benign diseases from malignant diseases and therefore provides successful avoidance of unnecessary surgical procedures [7]. Histopathology proves a better use in diagnosing follicular thyroid lesion [8] and the prevalence of thyroid nodule occurring in a clinical patient through autopsy and ultrasound data is 50% [9]. It is found out through several studies that prevalence of clinically clearly visible

thyroid nodules is estimated with US at 20% to 76% in the general population [10].

Goiter is a common clinical presentation worldwide with a prevalence rate of 4 to 7 percent, being more common in women than in men. In the previous studies it has been analyzed that 1 out of 20 clinically identified thyroid nodules is malignant [11]. In Pakistan the most common thyroid disease encountered is multi nodular goiter (61.63%) followed by follicular adenoma (14.05%) [6]. Moreover the overall malignancy rate reported in Pakistan is (14.35%), with Papillary Carcinoma (11.17%) having higher incidence than Follicular Carcinoma (1.81%) [6]. Hence, the clinical importance of newly diagnosed thyroid nodules is mainly to get rid of the malignant thyroid lesions [10]. Thyroid cancers are more prevalent in females as compared to males and is common in the third to fifth decade of life [6]. FNAC with histological study of surgically extracted thyroid tissue combined with the morphological features of a thyroid nodule provides the most definitive analysis about the nature of the nodule [12]. It has surpassed other tests for preoperative examination of the thyroid tissue and is preferred to be adapted as a key investigation in developing countries like Pakistan [5].

2. MATERIALS AND METHODS

158 samples were included in the study with different pathological lesions of thyroid referred from various private and Government hospitals of territory received at The Vital laboratory Larkana from 2014 to 2015. FNAC was performed on all cases and slides were prepared. Non-probability consecutive sampling was used, then detailed history including different pathological variables were taken followed by physical examination. FNAC was performed on all cases and slides were prepared. Slides were evaluated by a panel of histo-pathologists and cytopathologist than results were recorded. The parameters included in the study were: sex, age, site of lesion and diagnosis. The parameters included in the study were: Sex, age, site of lesion and diagnosis. We categorized the diagnosis into the following:

Nodular goiter, colloid goiter, benign lesions, malignancy and others. Data was analyzed using IBM SPSS version 22. Quantitative data was represented as Mean, Range, Median and Standard deviation while Qualitative data was represented as frequency and percentage. To find an association between the variables Chi square test was applied and P value <0.05 was taken as significant.

3. RESULTS

We were able to perform the FNAC on 158 patients who presented with midline neck (thyroid) swelling. Out of these, 125 (79.1%) were females and 33 (20.9%) were males with a ratio of 4:1 (as shown in Fig. 1). The ages ranged from 1-75 years and were divided into three groups. In the present study, most cases were found to be present in the age group 20-39 years with a frequency of 83 (52.5%) (as shown in Fig. 3). The most common disease encountered was nodular goiter (88.6%) followed by colloid goiter (4.4%) and benign lesions had the lowest frequency (0.6%) (as shown in Fig. 2) We applied Chi square test to find an association of diagnosis with gender and age but unfortunately we were not successful, with a p value of 0.211 and 0.533 respectively (as shown in Tables 1& 2)

4. DISCUSSION

Thyroid enlargement is one of the most common disorders of the endocrine system worldwide [6]. Clinical recognition of disease of thyroid is important, because most of them can be treated medically or surgically [12]. Thyroid indisposition has been found to have an impact on 5% of the general population worldwide [13]. Recurrent findings consist of thyroid nodules which are based on palpations ranging from 3-7%. These frequently arise in elderly women exposed to iodine deficiency or radiation [10]. Enlargement of the thyroid, also termed as goiter is the most common manifestation of thyroid disease and is most often cause by iodine deficiency [12]. FNAC has played a pivotal role in approximating the risk of malignancy and has enjoyed a 95% accuracy rate of differentiating benign nodules from malignant [14,15]. Well tolerated by patients, this procedure has evaluated swellings originating from the thyroid gland, salivary gland, mammary glands and neck lymph nodes [16,17].

There is a broad research scope but our study was limited to 158 patients who presented with neck swellings out of which, 125 (79.1%) were

females and 33 (20.9%) were males with a ratio of 4:1, showing predominantly a disease of women as supported by a study conducted in the United States where 4 to 7% of the population presented with thyroid swellings and were more common in women than men [18]. Our study was in line with other studies carried out in Pakistan. In one study carried out in Karachi-Pakistan by Nazar Hussain, M. Anwar, Nadia N. and Zulfiqar Ali with a sample size of 662 out of which 570 were females and 92 were males [13]. The most common lesion encountered in this study stands with our study which is multinodular goiter, moreover the overall rate of malignancy in this study was 1.27% with papillary carcinoma being the most common than the follicular variant [13]. An Egyptian research was also found to have female to male ratio of 5.2:1 with females (83.8%) and males (16.2%) [19]. The most common disease encountered in our study was nodular goiter (88.6%) which is in line with a study carried out in Uganda by Robert Masereka, Paul K. Okeny, Jane O. Fualal and Dan Wamala in which majority of patients (88.9%) had multinodular goiter [13]. That might be encountered in resource poor settings that emphasizes on the fact that iodine deficiency still remains the top most cause of thyroid disorders on the African continent [12]. Furthermore the proportion of patients with malignancy in this study was 13.1 which contrasts with what is reported in Europe North America where the malignancy rate is 5% [20]. In another study carried out in India by Khageswar Rout, Chinmay Sunder Ray, Subrat Kumar Behra and Rudranarayan Biswal with a sample size of 76 patients, demonstrated that colloid goiter was the most common among the thyroid swellings followed by colloid goiter with cystic degeneration [17]. Moreover In the same study out of malignant cases, the most common malignancy for papillary carcinoma (71.4%) followed by follicular carcinoma (28.6%) [17].

An analysis carried out in Iran by Hassan Taghipour of Tabraiz University also managed to have highest number of multinodular goiter cases of (94.4%) followed by cases of Hashimoto thyroiditis (5.2%) [21]. The prevalence of malignancy depends on the population studied; in our study only 1.27 percent of the cases were found to be malignant however rate of malignancy was 6 percent in Canada, 9 percent in Poland and 28.4 percent in Sendai, Japan [7]. This increment of malignancy in other countries may be due to radiation treatment in their youth or familial mutation of PTC or MEN2.

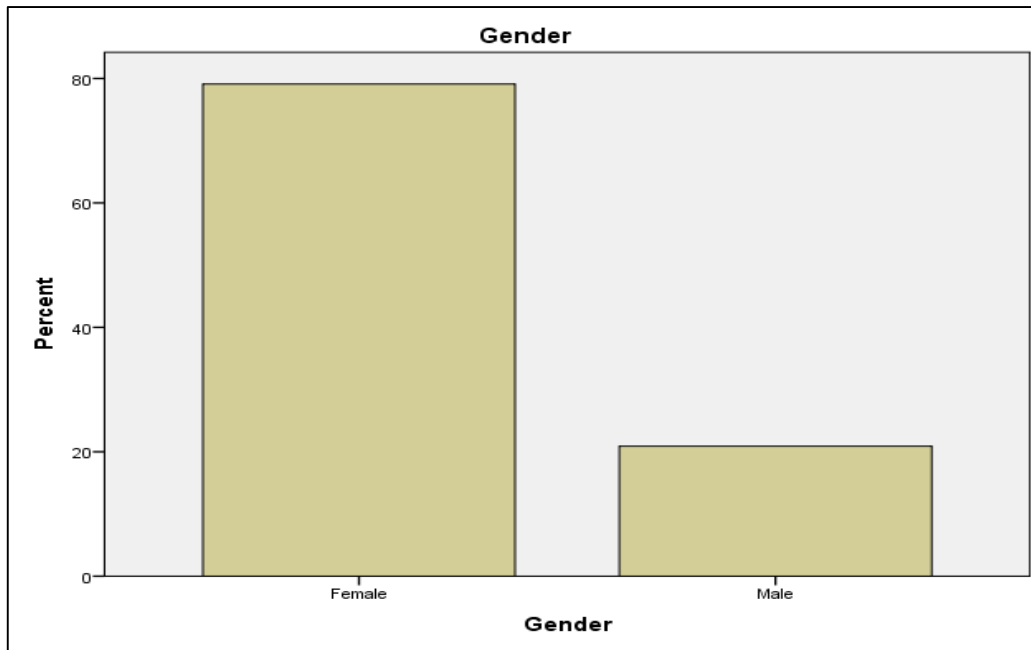


Fig. 1. Frequency of gender-associated lesions

Table 1. Association of diagnosis with gender

| Diagnosis | | Gender | | Total | P value |
|----------------|--------------------|---------|--------|---------|---------|
| | | Female | Male | | |
| Nodular Goiter | Count | 112 | 29 | 141 | |
| | % within Diagnosis | 79.40% | 20.60% | 100.00% | |
| Colloid Goiter | Count | 6 | 1 | 7 | |
| | % within Diagnosis | 85.70% | 14.30% | 100.00% | |
| Benign Lesions | Count | 1 | 0 | 1 | 0.553 |
| | % within Diagnosis | 100.00% | 0.00% | 100.00% | |
| Malignancy | Count | 2 | 0 | 2 | |
| | % within Diagnosis | 100.00% | 0.00% | 100.00% | |
| Others | Count | 4 | 3 | 7 | |
| | % within Diagnosis | 57.10% | 42.90% | 100.00% | |

*=chi square test

Table 2. Association of diagnosis with age

| Diagnosis | | Age | | | Total | P value |
|----------------|--------------------|---------|----------|---------|---------|---------|
| | | 1 to 19 | 20 to 39 | =>40 | | |
| Nodular Goiter | Count | 8 | 74 | 59 | 141 | |
| | % within Diagnosis | 5.70% | 52.50% | 41.80% | 100.00% | |
| Colloid Goiter | Count | 0 | 5 | 2 | 7 | |
| | % within Diagnosis | 0.00% | 71.40% | 28.60% | 100.00% | |
| Benign Lesions | Count | 0 | 0 | 1 | 1 | 0.211 |
| | % within Diagnosis | 0.00% | 0.00% | 100.00% | 100.00% | |
| Malignancy | Count | 1 | 0 | 1 | 2 | |
| | % within Diagnosis | 50.00% | 0.00% | 50.00% | 100.00% | |
| Others | Count | 1 | 4 | 2 | 7 | |
| | % within Diagnosis | 14.30% | 57.10% | 28.60% | 100.00% | |

*= chi square test

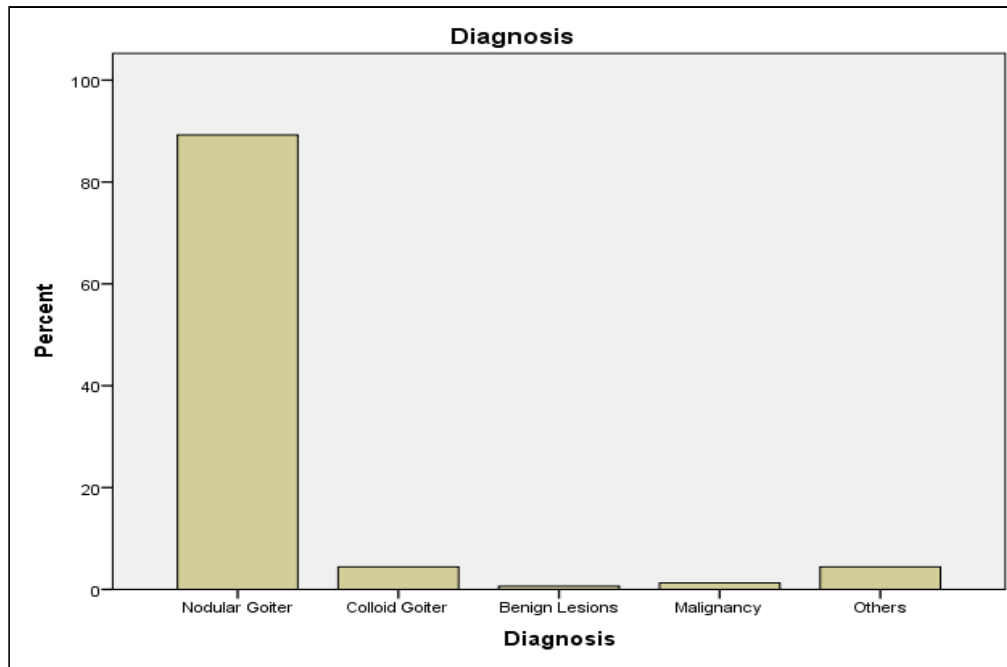


Fig. 2. Frequency of different lesions

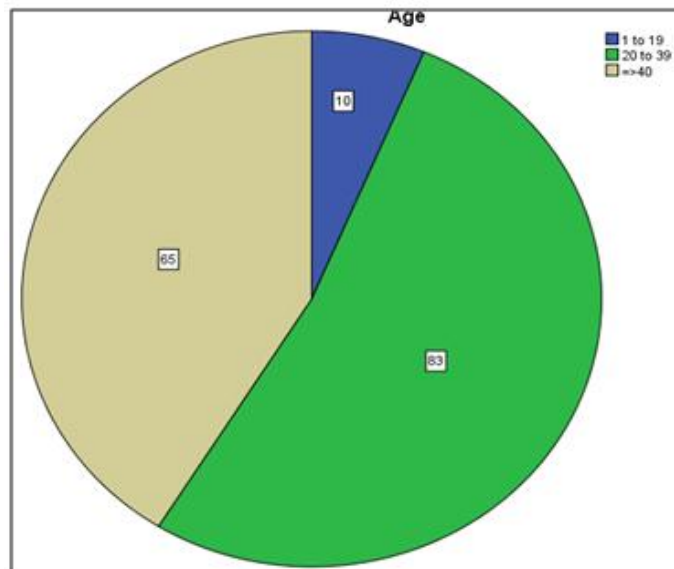


Fig. 3. Frequency of age groups

Multinodular goiters are quintessentially silent and harmless however a minority might present with thyrotoxicosis. This minority might represent the people of low socioeconomic status which do not have inadequate iodine uptake [13]. However multinodular goiters can sometimes lead to airway obstruction, dysphagia and compression of large vessels in the neck and upper thorax

(superior vena cava syndrome) [12]. The statistics of the disease not only helps us interpret the etiology behind it but gives us scope for the future plans concerning screening, management and prevention of the disease, which can be brought about on an individual level by awareness and consumption of iodine fortified food [22].

5. CONCLUSION

FNAC is a simple, safe, cost effective and highly efficient technique in the investigation of thyroid disease with high accuracy and specificity. Moreover it is extremely helpful in third World Countries like Pakistan for the diagnosis of thyroid lesions. In this study, based on the data that was collected through obtaining FNAC of thyroid patients, we concluded that thyroid lesions are more common in women with nodular goiter being the most common finding. The most important aspect of the examination is to rule out the possibility of thyroid cancer, however, the incidence of malignancy in long-standing multinodular goiters is low (<5%) but not zero and concern for malignancy arises with goiters that demonstrate sudden changes in size or associated symptoms such as hoarseness of voice.

CONSENT

As per international standard written patient consent has been collected and preserved by the author(s).

ETHICAL APPROVAL

As per international standard written ethical approval has been collected and preserved by the author(s).

ACKNOWLEDGEMENT

The authors appreciate the co-operation of patients who participated in this study, the staff for retrieving patients' data and Dr. Santosh Kumar for helping with the statistical analysis.

COMPETING INTERESTS

Authors have declared that no competing interests exist.

REFERENCES

1. Bode-Lesniewska B, Cochand-Priollet B, Straccia P, Fadda G, Bongiovanni MJC. Management of thyroid cytological material, preanalytical procedures and bio-banking. 2019;30(1):7-16.
2. Ahmad T, Naeem M, Ahmad S, Samad A, Nasir AJJAMCA. Fine Needle Aspiration Cytology (FNAC) and neck swellings in the surgical outpatient. 2008;20(3):30-2.
3. Goyal P, Sehgal S, Ghosh S, Mittal D, Kumar A, Singh SJ Pri. A cytological study of palpable superficial nodules of parasitic origin: A study of 41 cases. 2014;2014.
4. Ersöz C, Firat P, Uguz A, Kuzey GMJCCII Jot ACS. Fine-needle aspiration cytology of solitary thyroid nodules: How far can we go in rendering differential cytologic diagnoses? 2004;102(5):302-7.
5. Clary KM, Condel JL, Liu Y, Johnson DR, Grzybicki DM, Raab SSJAc. Inter observer variability in the fine needle aspiration biopsy diagnosis of follicular lesions of the thyroid gland. 2005;49(4):378-82.
6. Hussain N, Anwar M, Nadia N, Ali ZJB. Pattern of surgically treated thyroid diseases in Karachi. 2005;21(1):18-20.
7. Rojeski MT, Gharib HJNEJoM. Nodular thyroid disease: Evaluation and management. 1985;313(7):428-36.
8. Muddegowda PH, Srinivasan S, Lingegowda JB, Kurpad R, Murthy KSJJoC, JCDR DR. Spectrum of cytology of neck lesions: Comparative study from two centers. 2014;8(3):44.
9. Poller D, Stelow E, Yiangou CJC. Thyroid FNAC cytology: Can we do it better? 2008; 19(1):4-10.
10. Gharib H, Papini E, Paschke R, Duick D, Valcavi R, Hegedüs L, et al. American Association of clinical endocrinologists, associazione medici endocrinologi and European Thyroid Association medical guidelines for clinical practice for the diagnosis and management of thyroid nodules. 2010;16(Supplement 1):1-43.
11. Hegedüs LJNEJoM. The thyroid nodule. 2004;351(17):1764-71.
12. Robbins Basic Pathology used.pdf.
13. Masereka R, Okeny PK, Fualal JO, Wamala DJAhs. Diagnostic accuracy of fine needle aspiration cytology in patients undergoing thyroidectomy in Uganda: Tertiary hospital experience. 2016; 16(4):1143-50.
14. Luo J, Zhang C, Huang F, Chen J, Sun Y, Xu K, et al. Risk of malignancy in thyroid nodules: Predictive value of puncture feeling of grittiness in the process of fine-needle aspiration. 2017;7(1):13109.
15. Bagga P, Mahajan NJJoc. Fine needle aspiration cytology of thyroid swellings: How useful and accurate is it? 2010;47(4): 437.

16. Howlett D, Harper B, Quante M, Berresford A, Morley M, Grant J, et al. Diagnostic adequacy and accuracy of fine needle aspiration cytology in neck lump assessment: Results from a regional cancer network over a one year period. 2007;121(6):571-9.
17. Rout K, Ray CS, Behera SK, Biswal RJIJoO, Head, Surgery N. A comparative study of FNAC and histopathology of thyroid swellings. 2011;63(4):370-2.
18. Vander JB, Gaston EA, Dawber TRJAoim. The significance of nontoxic thyroid nodules: Final report of a 15-year study of the incidence of thyroid malignancy. 1968;69(3):537-40.
19. Sinna E, Ezzat NJJotEnci. Diagnostic accuracy of fine needle aspiration cytology in thyroid lesions. 2012;24(2):63-70.
20. Attaullah S, Haq BS, Muska M. J. Pjoms. Thyroid dysfunction in khyber pakhtunkhwa, Pakistan. 2016;32(1):111.
21. Esmaili HA, Taghipour HJIP. Fine-needle aspiration in the diagnosis of thyroid diseases: An appraisal in our institution. 2012;2012.
22. Charlton K, Skeaff Sjoicn, Care M. Iodine fortification: Why, when, what, how and who? 2011;14(6):618-24.

© 2020 Sidhwani et al.; This is an Open Access article distributed under the terms of the Creative Commons Attribution License (<http://creativecommons.org/licenses/by/4.0>), which permits unrestricted use, distribution, and reproduction in any medium, provided the original work is properly cited.

Peer-review history:

*The peer review history for this paper can be accessed here:
<http://www.sdiarticle4.com/review-history/55193>*