



Congenital Melanocytic Hairy Nevi in a Child from North-Western Nigeria

**Fatima Bello Jiya^{1*}, Maryam Amodu-Sanni¹, Nma Muhammed Jiya¹,
Dada Muhammed Aquib², Muhammed Umar³, Mohammed Hassan Abba¹
and Fa'iza Mu'azu Abubakar¹**

¹Department of Paediatrics, Usmanu Danfodiyo University Teaching Hospital, Sokoto, Nigeria.

²Department of Radiology, Usmanu Danfodiyo University Teaching Hospital, Sokoto, Nigeria.

³Department of Histopathology Usmanu Danfodiyo University Teaching Hospital, Sokoto, Nigeria.

Authors' contributions

This work was carried out in collaboration among all authors. Author FBJ designed the study, wrote the protocol and the first draft of the manuscript. Authors MAS, NMJ and MU reviewed and edited the manuscript. Authors DMA, MHA and FMA managed the literature searches. All authors read and approved the final manuscript.

Article Information

DOI: 10.9734/AJMAH/2020/v18i730221

Editor(s):

(1) Dr. Arun Singh, Rohilkhand Medical College & Hospital, India.

(2) Dr. Jaffu Othniel Chilongola, Kilimanjaro Christian Medical University College, Tumaini University, Tanzania.

Reviewers:

(1) María Teresa Cagua Sánchez, Universidad El Bosque, Colombia.

(2) Rana Rafiei, Guilan University of Medical Sciences, Iran.

(3) S. Vijay Shankar, Adichunchanagiri University, India.

Complete Peer review History: <http://www.sdiarticle4.com/review-history/58294>

Case Study

Received 20 April 2020

Accepted 27 June 2020

Published 11 July 2020

ABSTRACT

Aim: To present the first report of a large congenital melanocytic nevus with satellite nevi in an apparently healthy child from Sokoto, North-Western Nigeria.

Presentation of Case: A three year old girl was brought to the paediatric out-patient clinic of Paediatrics department of Usmanu Danfodiyo University Teaching Hospital (UDUTH) Sokoto with complaints of darkened skin colour on the left side of the face and scalp, the left arm, lower back, buttocks, and thighs, and excessive hair growth over the same side of the face since birth. There were no neurological symptoms Physical examination findings revealed a well-nourished, not ill looking child. She had a hyper pigmented patch on the left side of the face extending from the lower jaw to the scalp, measuring 21 cm in its longest length, with hypertrichosis on the same site, and two distinct, firm, painless nodular lesions on the left temporal region measuring 3 mm and

*Corresponding author: E-mail: fatimabellojiya@gmail.com;

4mm respectively. On the lower one-third of the left arm was a hairy, velvety area of hyperpigmentation measuring 2X3 cm in diameter. Other affected sites were the lower back, the gluteal region and the thighs. Her neurologic and other systemic examinations were normal. A diagnosis of large congenital facial melanocytic hairy nevus with multiple satellite nevi was made.

Discussion: Congenital melanocytic nevi are benign proliferations of melanocytic cells said to be present at birth or in the first two years of life. Large lesions are rare, they measure 20 cm or more and are said to occur more commonly on the trunk and thighs. The exact pathogenesis of congenital melanocytic nevi is yet, unknown. It is thought to occur as a result of a morphological error in the neuroectoderm during embryogenesis. Treatment of patients with large congenital melanocytic nevus may include surgical or non-surgical procedures as well as psychological interventions. Large lesions, multiple satellite lesions or paravertebral and axial locations are sometimes associated with the risk of neurological complications and malignant transformation.

Conclusion: Large congenital melanocytic nevi are uncommon skin lesions that can occur in apparently healthy children. Individualization of the patients with regards to treatment options and long term monitoring are imperative.

Keywords: Congenital; large; melanocytic nevi; child; Sokoto; Nigeria.

1. INTRODUCTION

Melanocytic nevi are benign proliferations of melanocytic cells said to be arranged in nests in the epidermis, dermis or in other tissues of the body [1,2]. When present at birth or even in the first two years of life, melanocytic nevus is said to be congenital. A lesion that is 20 cm or more is generally considered large [1-3]. Although it is rare in its occurrence with estimated incidence of 1:20,000, large lesions are sometimes associated with the risk of neurological complications and malignant transformation [4,5]. Although the risk of developing melanoma is still controversial, an estimated lifetime risk of 5-10% has been reported [6]. Its unsightly appearance is also said to be associated with psychological and social impacts on the affected individual and the family, especially when located in visible areas like the face [7]. The exact pathogenesis of congenital melanocytic nevi is yet, unknown. It is however, believed to be as a result of a morphological error that occurs in the neuroectoderm during embryogenesis, leading to unregulated growth of melanoblasts, which are the precursor cells of melanocytes [8]. The therapeutic modalities can be a source of distress to not only the patient but to the medical team involved in the management of the lesions [7]. Treatment of patients with large congenital melanocytic nevus may include surgical or non-surgical procedures, psychological interventions, with the utmost attention to changes in the color, texture or in the surface of the lesion [9,10]. This case is to the best of our knowledge, the first report of a large congenital melanocytic nevus with satellite nevi in an apparently healthy child from the study location.

2. PRESENTATION OF CASE

We report the case of H.I, a three year old girl brought to the Paediatric out-patient clinic of Usmanu Danfodiyo University Teaching Hospital (UDUTH), Sokoto in January 2020 with complaints of darkened skin colour on the left side of the face and scalp, the left arm, lower back, buttocks, and thighs, and excessive hair growth over the same side of the face since birth. No history of abnormal body movements, seizures, inability to use any body parts, irrational talk or behavior, headache, pruritus, vomiting, visual or hearing impairment. No preceding history of trauma or histories suggestive of bleeding disorders. The affected sites were noticed to be increasing in size with age but there hadn't been any change in the characteristics of the lesions over time. Scraping the hair overlying the skin at intervals had been the only intervention before presentation to the clinic. She was carried to term, antenatal period, delivery and puerperium were uneventful. There was no maternal history of exposure to radiation, febrile illness associated with rash, maternal history of ingestion of alcoholic beverages, cigarette smoking, and ingestion of un-prescribed orthodox medication or herbal medications. Her developmental milestones were normal for age. There was no known family history of similar condition. She is the only child of her parents who had been separated for 2 years on account of marital discord. Parents are not related by blood. Father is a 34 year old diploma holder working with federal road safety commission, mother is a 21 year old secondary school dropout with no other source of income. Patient had

been under the care of her paternal grandmother who had no formal education and is a petty trader.

Physical examination findings revealed a well-nourished, not ill looking child with weight, height, and occipito-frontal circumference of 13 kg, 92 cm, and 47 cm respectively. The mid upper arm circumference on the left and right were 15 cm and 14 cm respectively. She had a hyperpigmented patch on the left side of the face extending from the lower jaw to the scalp, measuring 21 cm in its longest length, with excessive, fine hair distribution on the same site, and two distinct, firm, painless nodular lesions on the left temporal region measuring 3mm and 4mm respectively. On the lower one-third of the left arm was a hairy, velvety area of hyperpigmentation measuring 2X3 cm in diameter. Other affected sites were the lower

back, the gluteal region and the thighs with small, discrete, non-hairy hyperpigmented lesions measuring 0.5-1.0 cm in diameter. There was no dysmorphic features, no significant peripheral lymphadenopathy, the neurologic and other systemic examinations were normal. A clinical diagnosis of large congenital melanocytic hairy nevus with multiple satellite nevi was made. Her results of complete blood count, Hepatitis B and C profile, retroviral screening, electrolytes, blood urea nitrogen, and blood sugar were essentially normal. Electroencephalographic findings revealed no seizure activity. Computed tomography scan of the brain showed normal findings. Histology report of the biopsied skin lesion (Fig. 4) revealed fairly discrete aggregates of small nests of pigmented polygonal melanocytes, melanophages and small naevoid cells in the dermis, consistent with melanocytic nevi.

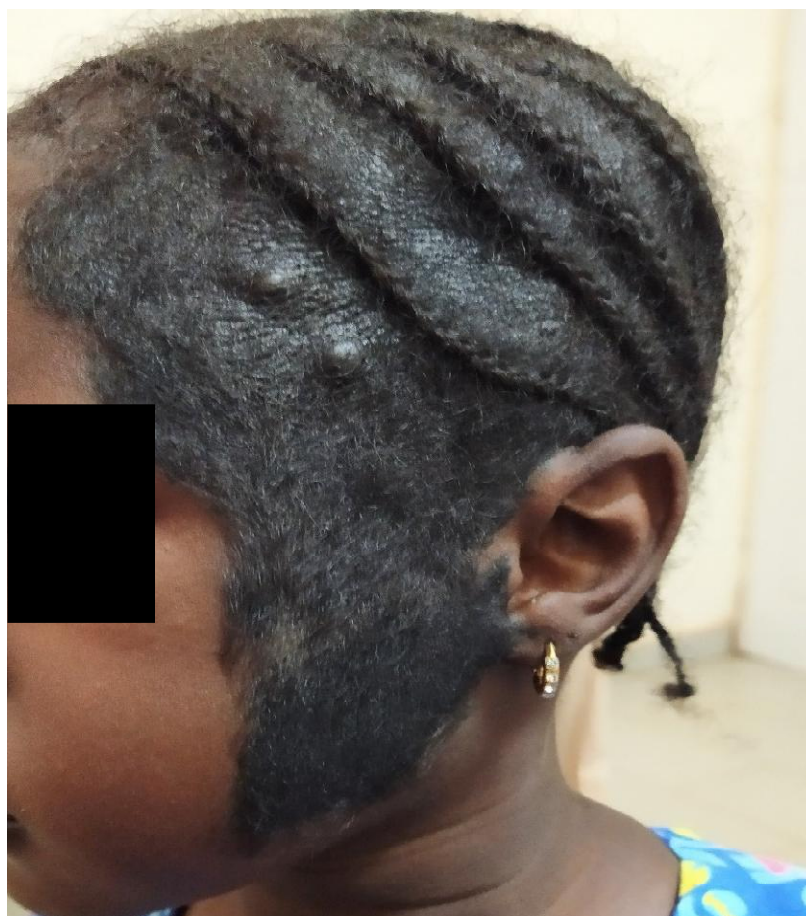

Fig. 1. Large hyperpigmented hairy nevus on the face extending to the scalp with two discrete proliferative nodules on the left temporal region

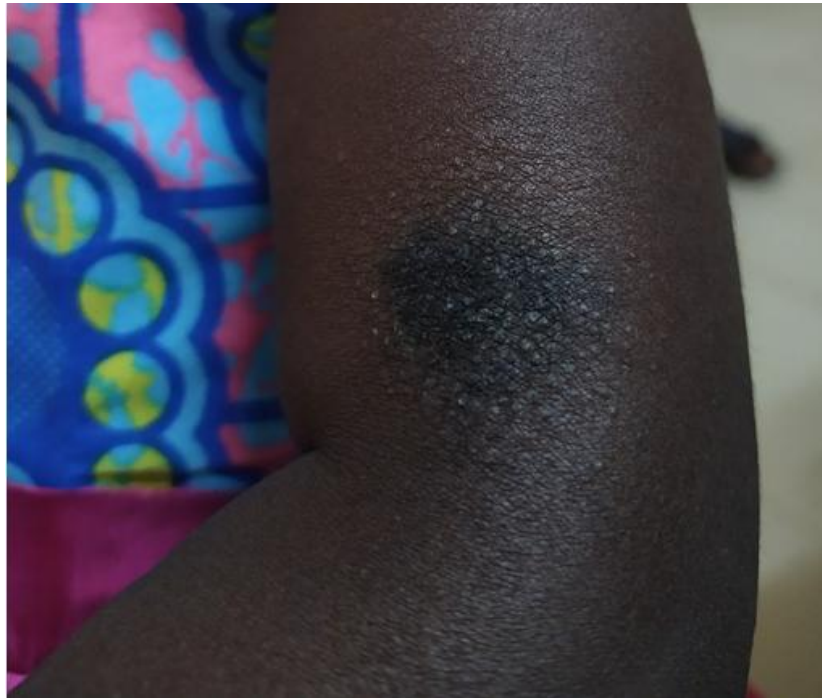

Fig. 2. Hairy nevus on the lower one-third of the left arm

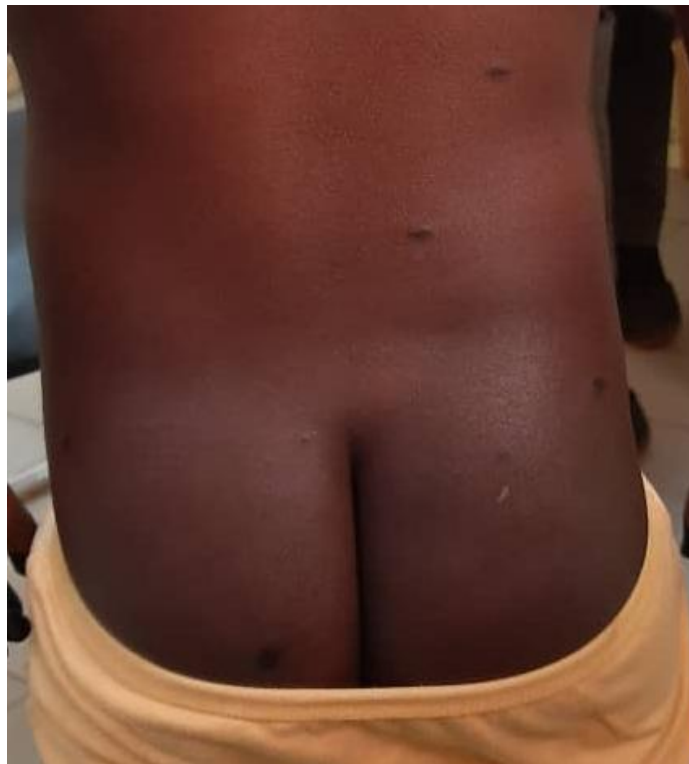

Fig. 3. Satellite non hairy nevi on the lower back and gluteal region

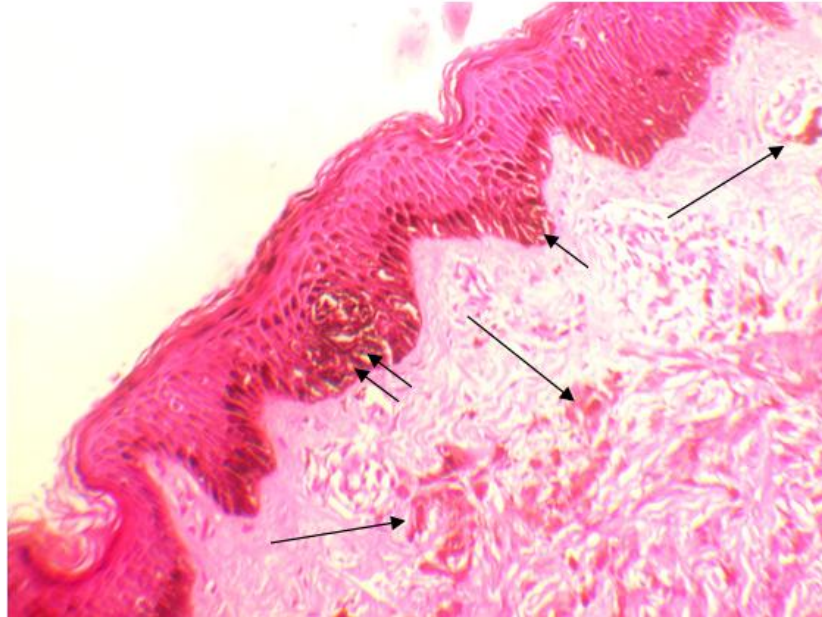


Fig. 4. Section shows fairly discrete aggregates of small nests of pigmented polygonal melanocytes, melanophage and small naevoid cells in the dermis (long arrows) with junctional activity (short arrows). H & E X 400

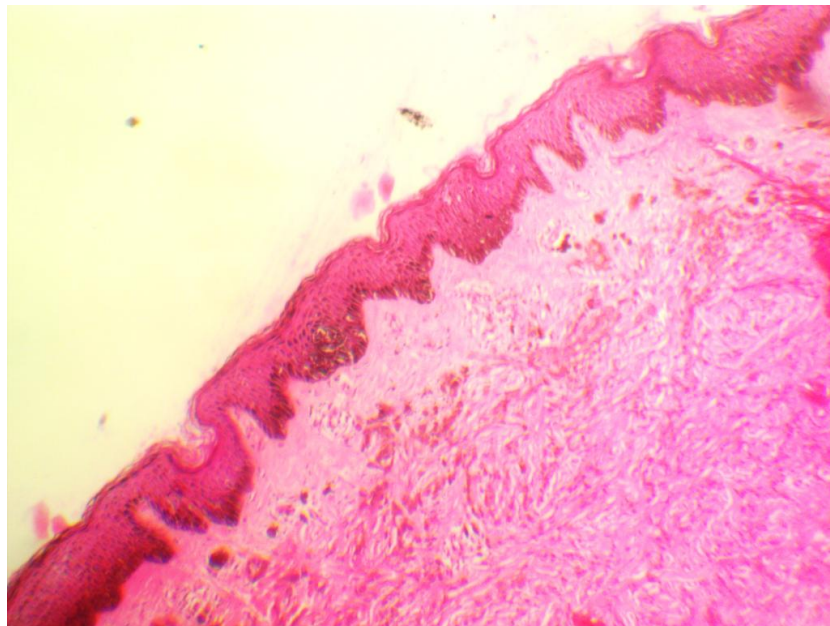


Fig. 5. Section shows fairly discrete aggregates of small nests of pigmented polygonal melanocytes, melanophage and small naevoid cells in the dermis (long arrow) with junctional activity (short arrow). H & E X 100

She is currently being managed by a multidisciplinary team of paediatrician, dermatologist, radiologist, and psychologist. The consensus agreement of the managing team was

to monitor the nevi and the growth and development of the child. This was in consideration of the age of the child, the site of the nevi being disseminated, the absence of

neurological symptoms and the psychological implication of extensive surgical removal with no certainty of preventing the development of malignancy in future. Dermabrasion, chemical peels and laser treatment were discussed as options with the caregiver who was also informed that these options were mainly for cosmetic reasons and only the superficial cells may be removed with increased risk of scarring, reappearance of the lesion and hypertrichosis. The caregiver is currently unable to afford the cost of the aforementioned options. Long term follow up of the child involving counselling sessions, periodic examination and serial photographs of the nevi has been planned and discussed with the caregiver, with the possibility of a repeat biopsy for histology and surgical treatment if the nevi should change in characteristics suspicious of a malignancy.

3. DISCUSSION

Large forms of congenital melanocytic hairy nevus are said to occur more commonly on the trunk and thighs. Our patient's lesion was predominantly on the face and scalp with small sized disseminated nevi on other parts of the body. Although the involvement of the scalp may be associated with neurological abnormalities [11], the neurological examination findings of our patient were essentially normal and she had no other associated congenital malformations. However, multiple satellite lesions and / or paravertebral or axial locations such as occurring in our patient are said to be associated with increased incidence of neoplasia often diagnosed during childhood [10,12]. The appearance of nodules in the nevus as in this case of ours who had nodules on the surface of the facial lesion is rare and usually signifies the proliferation of neuroid tissue elements which are said to be benign in nature [13]. The location of a large nevus, proliferative nodules and hypertrichosis on the face and the related risk of malignancy in our patient increases the possibility of emotional stress on the caregiver and subsequently on the patient at an age, sufficient enough for her to understand the implications of her condition.

Surgical removal of large nevi in stages may be achieved through reconstructive surgical procedures. Other treatment options are said to include procedures such as curettage, dermabrasion, laser therapy, and chemical peels which may be used for superficial skin lesions, including reducing the pigment and hair, but does

not completely remove the nevus [3,5,9,10,14]. Lifelong regular examinations of the skin and general medical examination is extremely important even in patients whose nevus has been removed completely, to facilitate the detection of any malignancy in its earliest stages [12,14]. The caregiver has been advised on regular examination of the skin of the patient at home and the patient has been planned for routine follow up visits to ensure early detection and further management of any change in characteristics of the lesions or the development of neurological symptoms.

4. CONCLUSION

Large congenital melanocytic nevi are uncommon skin lesions that can occur in apparently healthy children as in this case, which to the best of the authors' knowledge is the first documented case in the study location. The emphasis is on individualization of the patient with regards to treatment options, the need for psychological support, and the imperativeness of ensuring long term monitoring of patients for further management decisions.

CONSENT

All authors declare that written informed consent was obtained from the parent for publication of this case report and accompanying images.

ETHICAL APPROVAL

Ethical approval to conduct the study was obtained from UDUTH Health Research Ethics Committee and the study number assigned is UDUTH/HREC/2020/953.

ACKNOWLEDGEMENT

The contribution of Dr. Jamila Muhammad of the Department of Medicine, UDUTH Sokoto is highly appreciated.

COMPETING INTERESTS

Authors have declared that no competing interests exist.

REFERENCES

1. Grichnik JM, Rhodes AR, Sober AJ. Benign neoplasias and hyperplasias of melanocytes. In: Wolff K, Goldsmith LA, Katz SI, Gilchrist BA, Paller AS, Lefell DJ, editors. Fitzpatrick's Dermatology in

- General Medicine. 7th Ed. New York: McGraw-Hill. 2008;1099–1122.
2. Kincannon J, Boutzale C. The physiology of pigmented nevi. *Pediatrics*. 1999;104:1042–1045.
 3. Arneja J, Gosain A. Giant congenital melanocytic nevi. *Plast Reconstr Surg*. 2007;120:26–40.
 4. Castilla EE, da Graça Dutra M, Orioli-Parreiras IM. Epidemiology of congenital pigmented naevi: I. Incidence rates and relative frequencies. *Br. J. Dermatol*. 1981; 104:307–315.
 5. Slutsky JB, Barr JM, Femia AN, Marghoob AA. Large congenital melanocytic nevi: associated risks and management considerations. *Semin Cutan Med Surg*. 2010;29:79–84.
 6. Viana ACL, Gontijo B, Bittencourt FV. Giant Congenital melanocytic nevus. *An Bras Dermatol*. 2013;88:863-878.
 7. Koot HM, de Waard-van der Spek F, Peer CD, Mulder PG, Oranje AP. Psychosocial sequelae in 29 children with giant congenital melanocytic naevi. *Clin Exp. Dermatol*. 2000;25:589–593
 8. Saida T. Histogenesis of congenital and acquired melanocytic nevi: A unifying concept. *Am J Dermatopathol*. 2006;28: 377–379.
 9. Tromberg J, Bauer B, Benvenuto-Andrade C, Marghoob AA. Congenital melanocytic nevi needing treatment. *Dermatol Ther*. 2005;18:136–150.
 10. Marghoob AA. Congenital melanocytic nevi. Evaluation and management. *Dermatol Clin*. 2002;20:607-16.
 11. DeDavid M, Orlow SJ, Provost N, Marghoob AA, Rao BK, Wasti Q, et al. Neurocutaneous melanosis: Clinical features of large congenital melanocytic nevi in patients with manifest central nervous system melanosis. *J Am Acad Dermatol*. 1996;35:529-38.
 12. Krengel S, Hauschild A, Schäfer T. Melanoma risk in congenital melanocytic naevi: A systematic review. *Br J Dermatol*. 2006;155:1–8.
 13. From L. Congenital nevi--let's be practical. *Pediatr Dermatol*. 1992;9:345–346.
 14. Kinsler V, Bulstrode N. The role of surgery in the management of congenital melanocytic naevi in children: A perspective from Great Ormond Street Hospital. *J Plast Reconstr Aesthet Surg*. 2009;62:595–601.

© 2020 Jiya et al.; This is an Open Access article distributed under the terms of the Creative Commons Attribution License (<http://creativecommons.org/licenses/by/4.0>), which permits unrestricted use, distribution, and reproduction in any medium, provided the original work is properly cited.

Peer-review history:

The peer review history for this paper can be accessed here:
<http://www.sdiarticle4.com/review-history/58294>