



# Renal Hydatid: Rare Site of Rare Disease

**Archana N. Rijhsinghani** <sup>a#\*</sup>

<sup>a</sup> SRL Diagnostics Dr Phadke Labs, Mumbai 400028, India.

## **Author's contribution**

The author has designed the study, wrote the protocol and wrote the first draft of the manuscript. managed the analyses of the study & managed the literature searches. The author has read and approved the final manuscript.

## **Article Information**

### **Open Peer Review History:**

This journal follows the Advanced Open Peer Review policy. Identity of the Reviewers, Editor(s) and additional Reviewers, peer review comments, different versions of the manuscript, comments of the editors, etc are available here: <https://www.sdiarticle5.com/review-history/96807>

**Case Study**

**Received: 02/01/2023**  
**Accepted: 04/03/2023**  
**Published: 09/03/2023**

## **ABSTRACT**

Echinococcosis is a parasitic infection caused by the larval stage of a cestode *Echinococcus granulosus*. It manifests as hydatid cyst. Infection is transferred through the oral-fecal pathway by eggs of the parasite. Hydatid cyst can be made in liver, lung and rarely in heart, breast, thyroid, soft tissue of neck and kidney. Herein, we present a case of hydatid cyst of kidney, a rare organ to get infected by *Echinococcus granulosus*. Our patient, presented with dull vague pain & heaviness in left flank, got diagnosed with hydatid cyst of left kidney on radiology. Nephrectomy was performed, in view of non- functional nature of kidney.

**Keywords:** *Echinococcosis; hydatid cyst; parasite; kidney.*

## **1. INTRODUCTION**

“Echinococcosis or hydatid disease is a zoonotic parasitic disease caused by larval stage

of cestode *Echinococcus granulosus*. The cysts are most commonly located in liver (75%) followed by lungs (15%)” [1].

<sup>#</sup> Consultant Histopathologist;

<sup>\*</sup>Corresponding author: E-mail: [archana2188@gmail.com](mailto:archana2188@gmail.com);

“Hydatid involvement of the kidney accounts for only 2-4% of all cases of hydatid disease” [2].

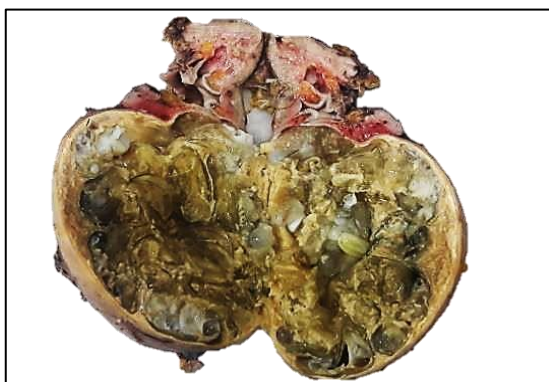
“The gold standard therapy for the disease is surgical excision of the cyst combined with antiparasitics” [3].

## 2. CASE REPORT

A 42-year-old female complained of dull vague pain and heaviness in left flank, of seven months duration. No history of fever/ loss of appetite/ loss of weight/ menstrual complaints.

Radiology studies were suggestive of Hydatid cyst of left kidney along with dilated pelvicalyceal system and non-functional left kidney. Due to non-functional nature, complete nephrectomy was performed.

We received bosselated left nephrectomy (Fig. 1) measuring 16 x 12 x 5 cms. The kidney proper measured 9 x 5 x 4 cms. Cut surface revealed a well demarcated, multicystic lesion involving lower pole of kidney measuring 13 x 12 x 5 cms containing multiple whitish to yellow smooth and gelatinous cysts that ranged from approximately 0.5 to 6.0 cm in diameter. Cysts contained translucent to yellowish fluid. There was no communication of cyst with pelvicalyceal system. No solid lesion was seen. The adjacent kidney was compressed, showing extremely dilated pelvicalyceal system, thinning of renal cortex, blurring of corticomedullary junction and differentiation. Ureteric stump measured 7.5cm in



**Fig. 1. Gross: Kidney showing multicystic lesion involving lower pole of kidney and containing multiple whitish to yellow smooth and gelatinous inner daughter cysts**

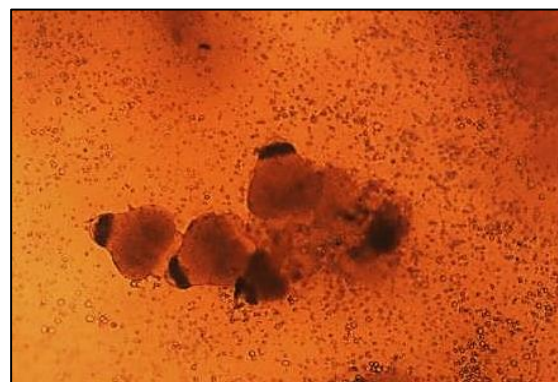
length and was slightly dilated in its upper portion. Cyst fluid cytology for immediate confirmation of diagnosis was performed, which revealed protoscolices of Echinococcus [Fig. 2].

On histology, the cysts was composed of three layers: the outermost fibrous pericyst layer (Fig. 3), the middle ectocyst (Fig. 4) layer formed by laminated, hyaline and acellular membrane and the inner endocyst (Figs. 4, 5) showing germinative layer which consists of daughter cysts and brood capsules with protoscolices. Hydatid sand (Fig. 6) comprised of degenerated protoscolices with hooklets and calcareous corpuscles. Surrounding kidney showed features of chronic pyelonephritis with atrophic tubules and markedly increased eosinophilic infiltrate (Fig. 7).

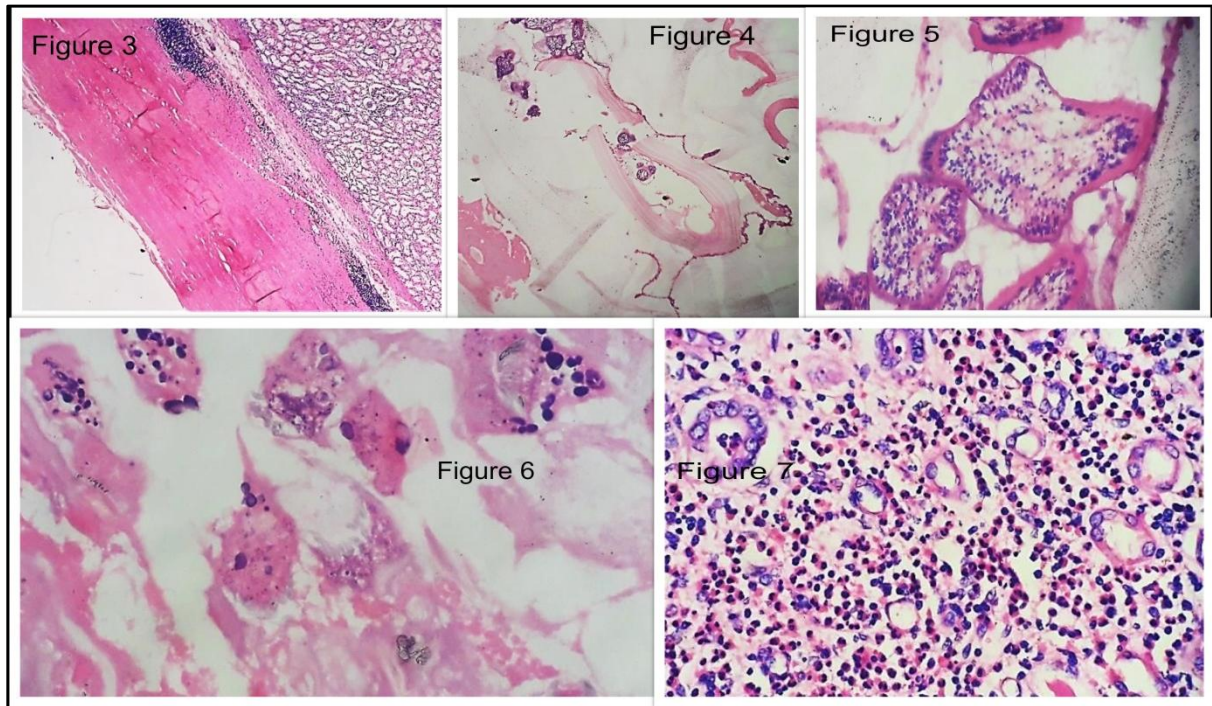
The final diagnosis on histology given was that of Hydatid cyst of kidney with hydronephrosis and chronic pyelonephritis. In the postoperative period, the patient was treated with albendazole and recovered well.

## 3. DISCUSSION

“The term "hydatid" came from the Greek word "hudatis," meaning watery vesicle. Cystic form of the Echinococcus larval stage has been well-recognized since ancient times. Rudolphi, in 1808, first used the term hydatid cyst to describe Echinococcus in humans. Hydatid disease is endemic in Mediterranean countries, the Middle East, South America, China, and India” [4].



**Fig. 2. Microscopy: Hydatid fluid cytology revealing protoscolices (Light microscopy wet preparation x400).**



**Fig. 3. Microscopy: Outermost fibrous pericyst. Fibrous layer is the tissue reaction separating renal parenchyma from ectocyst (HE x100)**

**Fig. 4. Microscopy: Middle layer of ectocyst laminated membrane and inner layer of endocyst (HE x100)**

**Fig. 5. Microscopy: Endocyst with protoscolices (HE x400)**

**Fig.6. Microscopy: Hydatid sand with degenerated protoscolices, refractile hooklets and basophilic calcareous corpuscles (HE x100)**

**Fig. 7. Microscopy: Adjacent renal parenchyma showing features of chronic pyelonephritis with dense eosinophilic infiltrate (HE x400)**

“Echinococcosis or hydatid disease is a zoonotic parasitic disease caused by larval stage of cestode *Echinococcus granulosus*. Dog is the definitive hosts while sheep is the usual intermediate host. Humans are accidental intermediate dead end hosts infected through ingestion of parasite eggs in contaminated food, water or soil, or through direct contact with animal hosts. After gaining entry in gut the parasite larva penetrates the duodenal mucosa, reaches the blood stream, and seeds the liver and lungs commonly. The cysts are most commonly located in liver (75%) followed by lungs (15%)” [1].

“Hydatid involvement of the kidney accounts for only 2-4% of all cases of hydatid disease” [2].

“It is not clear how the hydatid embryo reaches the kidney in cases of primary hydatid disease but it is postulated that it must pass through the portal system into the liver and retroperitoneal lymphatics” [5].

“Symptoms vary depending on the size, extension, and location of the cyst. Patients may be asymptomatic for long periods of time or present with lower back pain, hematuria, or an abdominal lump. Hydatiduria, a pathognomonic presentation of the disease, is observed in only 10-20% of the patients when the cyst ruptures into the collecting system. Patients with the disease are diagnosed with imaging tests, namely ultrasound, computed tomography (CT), nuclear magnetic resonance (NMR). Additional workup may include ELISA or indirect hemagglutination assays to titer for specific

antibodies, follow patients, and determine cases of recurring disease" [3].

"On imaging, a multiloculated cyst with daughter cyst(s) is diagnostic but unilocular cyst with a detached membrane is also suggestive of a hydatid cyst. In cases with noncharacteristic cystic lesion, the kidney may pose a diagnostic dilemma; double contour thick wall on ultrasonography or the presence of hydatid cyst in other organs favors the diagnosis" [4].

"The CT scan has an accuracy of 98% and sensitivity to demonstrate the daughter cysts. The CT scan usually demonstrates an expansile, hypo-attenuating tumor with a well-defined wall and daughter cysts within the parent cyst. The central cystic part of the lesion has an attenuation of 30-35 HU, in contrast to the much lower attenuation of the fluid in the surrounding cysts (5-15 HU), giving the mass a wheel-like or rosette appearance" [5].

"The hydatid cyst of the kidney is considered closed if all three layers of the cyst i.e. pericyst, ectocyst and endocyst are intact. When the cyst is no longer protected by the third layer i.e. pericyst or by the lining of collecting system it is considered to be an exposed cyst. If all the three layers of the cyst have ruptured resulting in free communication with the calyces and pelvis, it is called an open or communicating cyst" [5].

Blutke et al described in their study "hydatid sand revealing numerous free, partially evaginated protoscolexes, intact and ruptured brood capsules, calcareous corpuscles, necrotic protoscolexes, debris, and free rostellar hooklets" [6].

"The adjacent renal parenchyma often shows pressure atrophy and chronic pyelonephritic changes and an infiltrate in which eosinophils may be prominent" [7].

"The gold standard therapy for the disease is surgical excision of the cyst combined with antiparasitics" [3].

"A variety of surgical options, ranging from marsupialization and pericystectomy to nephrectomy, are advocated. Laparoscopic aspiration of the renal hydatid cyst has also been reported. Treatment with mebendazole or albendazole helps to prevent seeding" [4].

"Operation and using puncture, aspiration injection and re-aspiration (PAIR) are the most important and best treatment methods. According to the pressure on hydatid cyst, getting torn and the release of hydatid liquid containing protoscolex during the surgery are not unusual, and this issue is the most important cause of invasion in this disease, therefore applying scolicedals during the surgery is necessary" [8].

"Complete nephrectomy is reserved for destroyed nonfunctioning kidneys, opening into the draining system or other cavities and complicated by renal infection" [1].

#### 4. CONCLUSION

Hydatid cyst of kidney is a rare infection to have. The radiology and histology help in its diagnosis. The clinical manifestation being very vague, leads to late diagnosis of the disease, leading to renal damage. Hence, early diagnosis helps in functional renal preservation and thus leading to renal sparing surgeries.

#### ACKNOWLEDGEMENT

The author would like to thank SRL Diagnostics Dr. Phadke Labs.

#### COMPETING INTERESTS

Author has declared that no competing interests exist.

#### REFERENCES

1. Ramteke VV, Deshpande NS, Balwani MR, Bawankule CP. Primary renal echinococcosis. Indian J Nephrol. 2017; 27(4):316-318.
2. Turgut AT, Odev K, Kabaalioglu A, Bhatt S, Dogra VS. Multitechnique evaluation of renal hydatid disease. Am J Roentgenol. 2009;192(2):462-467.
3. Soares Ana Teresa Trindade, Couto Catarina, Cabral Maria João, Carmona Luísa, Vieira Isabel. Renal hydatid cyst: medical treatment. J. Bras. Nefrol. 2016 Mar;38(1):123-6.
4. Ray RP, Mondal PP, Mahapatra RS, Priyadarshi V, Mishra S, Bera MK. Hydatid cyst of kidney can present as simple renal cyst: A case report. Ann Trop Med Public Health. 2015;8(4):125-7.

5. Mongha R, Narayan S, Kundu AK. Primary hydatid cyst of kidney and ureter with gross hydatiduria: A case report and evaluation of radiological features. *Indian J Urol.* 2008 Jan;24(1):116–7.
6. Blutke A, Hamel D, Hüttner M, et al. Cystic echinococcosis due to echinococcus equinus in a horse from Southern Germany. *Journal of Veterinary Diagnostic Investigation.* 2010;22(3):458-462. doi:10.1177/104063871002200323
7. Joel JM, Jeyasingh SD, Chellaiah P. Primary renal hydatidosis. *Clin Cancer Investig J.* 2016;5(1):86-8.
8. Reza HAM, Rreza G, Nastaran B, Mousa M. Renal hydatid cyst; a rare infectious disease. *Oxf Med Case Reports.* 2019;4:114-116.

© 2023 Rijhsinghani; This is an Open Access article distributed under the terms of the Creative Commons Attribution License (<http://creativecommons.org/licenses/by/4.0>), which permits unrestricted use, distribution, and reproduction in any medium, provided the original work is properly cited.

*Peer-review history:*

*The peer review history for this paper can be accessed here:*  
<https://www.sdiarticle5.com/review-history/96807>