



Pleomorphic Adenoma of a Minor Salivary Gland of the Hard Palate Report of a Case

**M. Chandra Sekhar¹, D. Ayesha Thabusum^{1*}, M. Charitha¹, G. Chandrasekhar¹
and K. Sai Dharani¹**

¹*Department of Oral Medicine and Radiology, Government Dental College and Hospital, Kadapa, India.*

Authors' contributions

This work was carried out in collaboration among all authors. Authors MCS, DAT, MC, GC and KSD studied the case and evaluated. Authors MCS and DAT designed the case study and wrote the first draft of the manuscript. All authors managed the literature searches. All authors read and approved the final manuscript.

Article Information

DOI: 10.9734/JAMMR/2019/v30i530199

Editor(s):

(1) Dr. James Anthony Giglio Adjunct, Clinical Professor of Oral and Maxillofacial Surgery, School of Dentistry, Virginia Commonwealth University, Virginia, USA.

Reviewers:

- (1) Areeba Asghar, United Medical and Dental College, Pakistan.
 - (2) S. Mythili, Sri Ramachandra Institute of Higher Education and Research, India.
 - (3) K. C. Niranjan, Shri Dharmasthala Manjunatheshwara University, India.
- Complete Peer review History: <http://www.sdiarticle3.com/review-history/50710>

Case Report

Received 26 May 2019
Accepted 07 August 2019
Published 16 August 2019

ABSTRACT

The pleomorphic adenoma is the most common benign tumor of the minor salivary glands and is comprised of epithelial and mesenchymal tissues. The majority of the salivary gland tumors occur in the second decade of life with a slight predilection for females. Clinically it presents as a firm or rubbery submucosal mass without ulceration or surrounding inflammation. Diagnosis is established on the clinical examination and histopathology, supplemented with plane radiographs, computerized tomography, and magnetic resonance imaging when necessary. Here, we report a case of pleomorphic adenoma of the hard palate in a 21-year-old female patient with a painless swelling in the left palatal region of nine months duration.

Keywords: *Pleomorphic adenoma; minor salivary gland tumor; palate.*

*Corresponding author: E-mail: drayashaomr@gmail.com;

1. INTRODUCTION

Salivary gland tumors account for less than 3% of head and neck tumors [1]. Pleomorphic adenoma is the most common salivary gland tumor accounting for about 40 – 70% of all major and minor salivary gland tumors [2]. The most common site of this tumor in the oral cavity is the palate (42.63%) followed by lip (10%), buccal mucosa (5.5%), and retromolar area (0.7%) and uncommonly affecting the floor of the mouth [3]. It is also called a mixed salivary gland tumor because of its dual origin from the epithelium and myoepithelial cells [4]. A case of Pleomorphic adenoma of the minor salivary gland of the palate is discussed.

2. CASE REPORT

A 21-year-old female patient reported to the Department of Oral Medicine and Radiology with a chief-complaint of a painless swelling over the left palatal region of nine months duration. The swelling was nontender, slow-growing, initially pea-sized, and increased to its present size. It did not interfere with speech, mastication, or swallowing. There was no history of trauma or fever. Her past medical, dental, and family histories were noncontributory. On general physical examination, the patient was well-developed, well-nourished, oriented x 3, with a normal gait. Her vital signs were within normal limits. On extraoral examination, no abnormalities were detected, and no lymph node involvement was noted.

Her intraoral examination revealed a solitary, roughly oval-shaped, sessile swelling measuring approximately 2×2 cm and extending from 5-6 mm from marginal gingival of left maxillary second molar to the mid-palatal region. Fig.2. The overlying mucosa was normal in color and

ulcerated. On palpation, the swelling was firm in consistency, nontender, nonpulsatile, and appeared fixed to the underlying bone. There was no regional lymphadenopathy. Based upon the history and clinical findings a provisional diagnosis of a benign salivary gland tumor was established. A differential diagnosis included: palatal abscess, odontogenic cyst, Kaposi's sarcoma, and syphilitic gumma.

A paranasal sinus radiograph did not reveal any pathological changes in the bony structure. CT revealed lobulated soft tissue dense space-occupying lesion measures 3×2 cm noted in the regional soft palate on the left side with no calcific foci. MRI revealed a well defined oval-shaped mass measuring 2.8×2.0 cm pointed out in the region of the soft palate at the junction with hard palate, mildly to the left side extending up to midline. The lesion shows T2 and short T1 inversion recovery hyperintensities with few areas of hypo intensities in the center Figs. 3, 4a, 4b, 5a, and 5b.

An incisional biopsy was performed under local anesthesia. The histopathological picture showed a tumor mass composed of epithelial and mesenchymal components with highly cellular and scanty connective tissue stromal cells. Areas of spindle cell proliferations resembling myoepithelial cells were evident. Myxomatous and chondroid areas were also seen. Fig. 6a. The patient was treated by wide local excision, and tumor was excised. Fig. 6b. There were no complications postoperatively and the area healed well within six weeks.

Fig. 5a, 5b showing well circumscribed lesion at the junction of hard and soft palate with hyperintensities and few areas of hypointensities in the center.

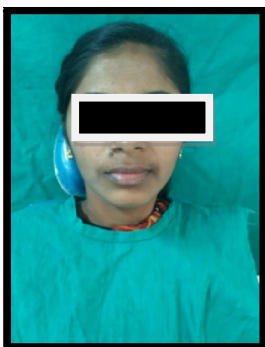

Fig. 1a. Frontal view

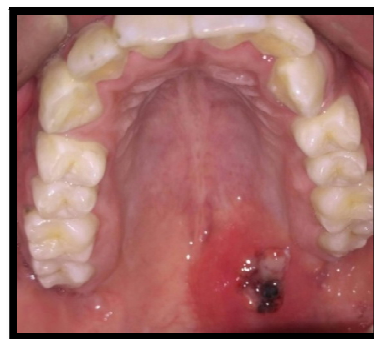

Fig. 2. Intraoral clinical picture showing swelling on the left side of the hard palate

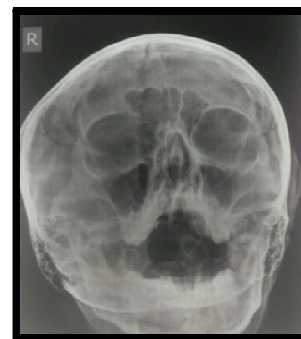

Fig. 3. Para nasal sinus view showing no perforation of maxillary sinus

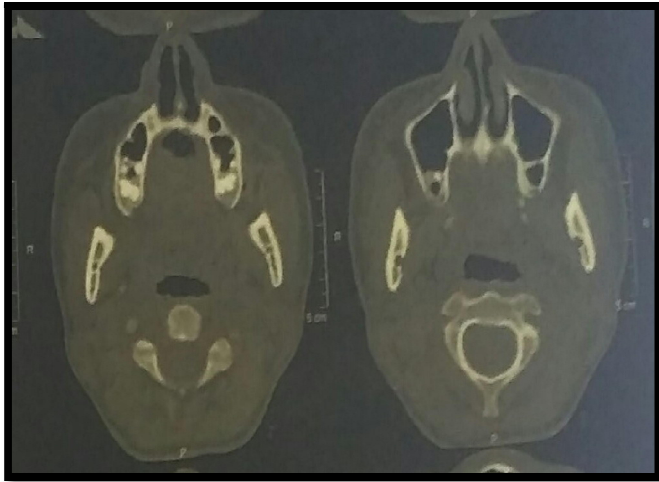


Fig. 4a. CT reporting no erosion or perforation palatal bone

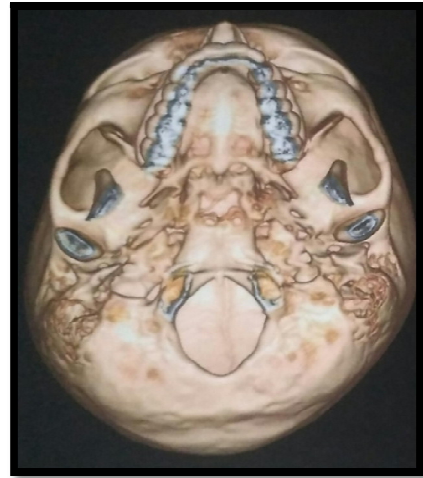


Fig. 4b. 3d CT skull showing no pathological changes of palatal bone

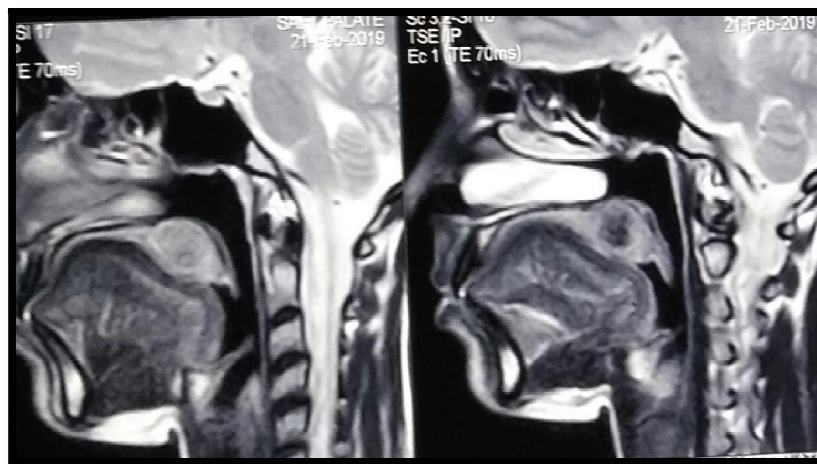


Fig. 5a. MRI sagittal view

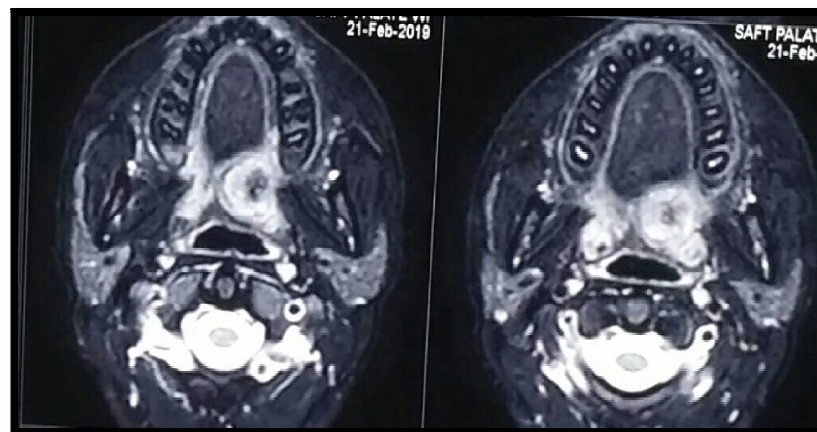


Fig. 5b. MRI axial view

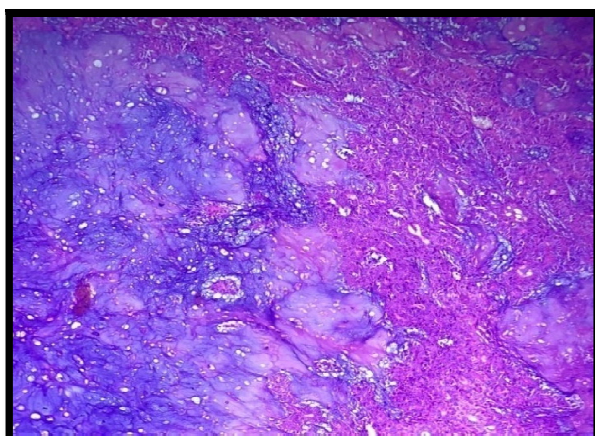


Fig. 6a. Histopathological view showing ducts and myoepithelial cells surrounded by a hyalinized eosinophilic background

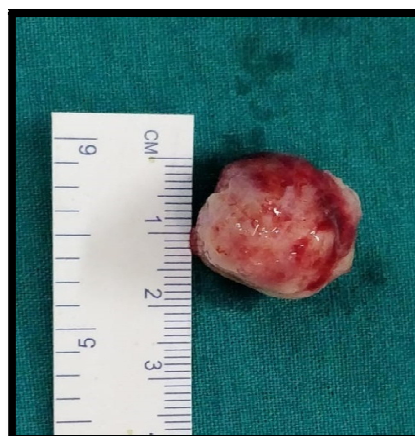

Fig. 6b. Excised specimen showing a well encapsulated mass

3. DISCUSSION

Tumors arising from the minor salivary glands are uncommon clinical entities. Among them the palate is the most commonly affected site followed by the upper lip and buccal mucosa respectively [5]. Pleomorphic adenoma is considered to be the most common benign salivary gland tumor. Our literature search indicated that eighty-four percent of pleomorphic adenomas occur in the parotid gland, eight percent in the submandibular gland, and four to six percent in the minor salivary glands. Spiro et al. conducted a study of patients with salivary gland neoplasia in which he reported that twenty to forty percent of all salivary gland tumors arise from minor salivary glands. [7], mostly seen in fourth to sixth decades of life with a slight predilection for female gender. This case report is consistent with the finding of gender. Rahnema et al. reported that etiology of pleomorphic adenomas, in 70%, result of chromosome abnormalities involving pleomorphic adenoma gene 1 (Plag 1) located on 8q12 and 12q15 [8].

Clinically it presents as a firm, painless swelling with intact overlying mucosa sometimes they have mucosal ulceration as was the case with this patient. Malignancy should be suspected in cases where ulceration of overlying mucosa is not result of trauma or biopsy [9]. Pleomorphic adenomas of palate can appear to be fixed to the bone. This is not caused by bony invasion but rather by the inelasticity of the

palatal mucosa that becomes distended by the tumor mass and may result in a cupped-out resorption of bone [10]. In other oral mucosal sites, it occurs as a freely movable, circumscribed mass [11].

Diagnosis of pleomorphic adenoma is established based on the physical examination and histopathology along with computed tomography (CT) and magnetic resonance imaging (MRI) [12]. Depending on the location and size of tumor, imaging with CT scan or MRI is helpful in setting the diagnosis and planning the treatment [13].

Differential diagnosis of pleomorphic adenoma includes odontogenic and non-odontogenic cysts, soft tissue tumors, palatal abscess, mucoepidermoid carcinoma, adenoid cystic carcinoma, and other salivary gland tumors. In addition to minor salivary gland tissue, palatal mucosa contains multiple other soft tissue types. As a result, soft tissue tumors such as neurofibroma, fibroma, lipoma, neurilemmoma as well as salivary gland tumors should also be considered in a differential diagnoses [6].

As the name suggests, mixed histology which consists of three components: an epithelial, myoepithelial elements, and a mesenchymal component arranged in varieties of cell patterns such as cord-like and duct-like along with areas of epidermoid metaplasia embedded in mucopolysaccharide stroma. Its microscopic diversity can exist in different areas of the same tumor and from one tumor to the other. The

tumor is composed of the island of stellate and spindle cells that are interspersed in myxoid background [14]. It is typically encapsulated and well circumscribed tumor, but incomplete encapsulation is more common for tumors of minor glands, especially palatal lesions.

Simple enucleation of the tumor has been reported with high recurrence. Therefore the treatment of benign minor salivary gland tumors is wide surgical excision along with the removal of periosteum and underlying bone found to be involved. Many authors had advocated wide surgical excision with curettage of the underlying bone with a surgical curette or bur to avoid recurrence [15]. Recurrence of the lesion may be due to an incomplete surgical removal such as might occur with simple enucleation leaving behind microscopic pseudopod-like extensions, capsular penetration, and tumor rupture with spillage of tumor cells [12]. Reconstruction of the palate should be considered for functional and aesthetic needs. The soft tissue defect of the palate can be left to granulate, whereas the hard tissue defect can be corrected with the help of obturator. In the present case, the patient did not require any reconstruction as the palatal mucosa regenerated without any formation of a fistula [15].

4. CONCLUSION

Pleomorphic adenomas of palate is a most common tumor of minor salivary glands. It is a challenging entity to diagnose and to treat. Proper history, patient evaluation, histopathological, and radio imaging are necessary because of its clinical diversity. Early diagnosis and wide local surgical excision result in complete removal of the pathology with no recurrence. With adequate surgical excision, the tumor usually does not recur, but most recurrences can be due to inadequate surgical technique. A long term follow up is needed because of possible recurrence even after several years of after the initial excision.

CONSENT

As per international standard or university standard, patient's consent has been collected and preserved by the authors.

ETHICAL APPROVAL

It is not applicable.

COMPETING INTERESTS

Authors have declared that no competing interests exist.

REFERENCES

1. Luna MA, Batsakis JG, El-Naggar AK. Salivary gland tumors in children. *Ann Otol Rhinol Laryngol.* 1991;100:869–871.
2. Jorge J, Pires FR, Alves FA, Perez DEC, Kowalski LP, Lopes MA. Juvenile intraoral pleomorphic adenoma: Report of five cases and review of the literature. *Int J Oral Maxillofac Surg.* 2002;31:273–275.
3. Rahnama M, Urszula Orzędą-Koszel, CzupkaŁo L, et al. Pleomorphic Adenoma of the palate: A case report and review of the literature. *Wspolczesna Onkol.* 2013;17(1):103-106.
4. Mubeen K, Vijayalakshmi KR, Patil AR, Giraddi GB, Singh C. Benign pleomorphic adenoma of the minor salivary gland of the palate. *J Dent Oral Hyg.* 2011;3:82–88.
5. Batsakis JG. Neoplasms of the minor and 'lesser' major salivary glands. In: *Tumors of the head and neck.* The Williams and Wilkins Company, Baltimore. 1981; 38–47.
6. Dhanuthai K, Sappayatosok K, Kongin K. Pleomorphic adenoma of the palate in a child: A case report. *Med Oral Patol Oral Cir Bucal.* 2009;14:E73–E75.
7. Spiro RH. Salivary neoplasms: Overview of a 35-year experience with 2,807 patients. *Head Neck Surg.* 1986;8:177-84.
8. Rahnama M, Orzędą-Koszel U, CzupkaŁo L, Lobacz M. Pleomorphic adenoma of the palate: A case report and review of the literature. *Contemp Oncol (Pozn).* 2013;17:103-106.
9. Chavan SN, Rathod JK. Lesion on palate: A diagnostic dilemma. *J Indian Acad Oral Med Radiol.* 2016;28:223-6.
10. Janardhan B. Garde, Kanchan Ralkwar, Adwait Kulkarni. Pleomorphic adenoma of the hard palate. *Journal of International Clinical Dental Research Organisation.* 2010;92- 94
11. Vellios F, Shafer WG. Tumors of minor salivary glands. *Surg Gynecol. Obstet.* 1981;108:450-456.
12. Patigaroo SA, Ashraf J, Mehfooz N, Nazir MS, Massod H. Pleomorphic adenoma of the hard palate: A experience. *J. Maxillofac. Oral Surg.* 2014;13(1):36–41.

13. Sharma Y, Maria A, Chhabria A. Pleomorphic adenoma of the palate. Natl J Maxillofac Surg. 2011;2:169-71.
14. Chau MN, Radden BG. A clinical-pathological study of 53 intraoral pleomorphic adenomas. Int J Oral Maxillofac Surg. 1989;18:158-62.
15. Swapnil Moghe, Ajay Kumar Pillai, S. Prabhu, Saksham Nahar UK. Kartika. Pleomorphic adenoma of the palate: Report of a case. Int J Sci Stud. 2014;2(1): 54-56.

© 2019 Sekhar et al.; This is an Open Access article distributed under the terms of the Creative Commons Attribution License (<http://creativecommons.org/licenses/by/4.0>), which permits unrestricted use, distribution, and reproduction in any medium, provided the original work is properly cited.

Peer-review history:
The peer review history for this paper can be accessed here:
<http://www.sdiarticle3.com/review-history/50710>